EX LIBRIS
PLUMMER

32

ROLAND HILL
PRESIDENT, 1919

CAT.

TWENTY-NINTH ANNUAL MEETING

TRANSACTIONS

OF THE

WESTERN SURGICAL ASSOCIATION

Twenty-Ninth Annual Meeting

Kansas City, Missouri, December 5 and 6, 1919

MINNEAPOLIS
PRESS OF THE JOURNAL-LANCET
1920

BOSTON MEDICAL
MAR - 5 1930
LIBRARY

CATALOGUED
MAR 5 1930
B. B.

BOSTON MEDICAL
MAR - 5 1930
LIBRARY

OFFICERS AND EXECUTIVE COMMITTEE

1920

PRESIDENT

Arthur T. Mann, M. D. - - - Minneapolis

FIRST VICE-PRESIDENT

Richard W. Corwin, M. D. - - - Pueblo

SECOND VICE-PRESIDENT

E. M. Sanders, M. D. - - - - Nashville

SECRETARY-TREASURER

Warren A. Dennis, M. D. - - - St. Paul

EXECUTIVE COUNCIL

Roland Hill, M. D. (Chairman) - - St. Louis

Joseph R. Eastman, M. D. - - Indianapolis

Charles D. Lockwood, M. D. - - Pasadena

Eric P. Swain, M. D. - - - - Bismarck

Warren A. Dennis, M. D. - - - St. Paul

EX-PRESIDENTS AND MEETING PLACES

PRESIDENT	PLACE	YEAR
S. S. Todd*	Topeka	1891
Milo B. Ward*	Kansas City	1892
Milo B. Ward*	Des Moines	1893
Lewis Schooler	Omaha	1894
John E. Summers, Jr.	Kansas City	1895
Thomas J. Beattie	Topeka	1896
Joseph Eastman*	Denver	1897
David S. Fairchild	Omaha	1898
Homer C. Crowell	Des Moines	1899
O. Beverly Campbell	Minneapolis	1900
August F. Jonas	Chicago	1901
James E. Moore*	St. Joseph	1902
Alex. Hugh Ferguson*	Denver	1903
Charles H. Mayo	Milwaukee	1904
Harvey D. Niles*	Kansas City	1905
Malcolm L. Harris	Salt Lake City	1906
Charles W. Oviatt*	St. Louis	1907
William W. Grant	Minneapolis	1908
Arthur L. Wright*	Omaha	1909
John P. Lord	Chicago	1910
Amos W. Abbott	Kansas City	1911
Lewis L. McArthur	Cincinnati	1912
Jabez N. Jackson	St. Louis	1913
Byron B. Davis	Denver	1914
Joseph Rilus Eastman	Des Moines	1915
Lawrence W. Littig*	St. Paul	1916
Leonard Freeman	Omaha	1917
James F. Percy	Chicago	1918
Roland Hill	Kansas City	1919

*Deceased.

The Western Surgical Association does not hold itself responsible for, or necessarily endorse, any of the papers printed herein.

ARTHUR T. MANN, Secretary-Treasurer.

CONTENTS

Officers and Executive Council 5
Ex-Presidents 7
Executive Session 11

PAPERS

President's Address: Medical Problems Suggested by the War. Roland Hill, M. D., C. M., St. Louis, Mo..... 23

The Distribution of Adenomyomas Containing Uterine Mucosa. Thomas S. Cullen, M. D., Baltimore, Md... 41

Treatment of Fracture of the Neck of the Femur in the Aged. Charles D. Lockwood, M. D., Pasadena, Cal... 139

Some Rarer Fractures—with Lantern Slides. Edward Evans, M. D., La Crosse, Wis..... 149

Dislocation of the Tarsal Scaphoid: Double Fracture of the Ischiatic Tuberosities. Willard D. Haines, M. D., Cincinnati, Ohio 155

Tuberculosis of the Great Trochanter of the Femur. Malvern B. Clopton, M. D., St. Louis, Mo..... 163

Tuberculosis of the Joints and Rollier's Heliotherapy. Gustav Schwyzer, M. D., F. A. C. S., Minneapolis, Minn. 169

Traumatic Osteomyelitis. Richard W. Corwin, M. D., Pueblo, Colo. 187

A New Method of Applying Plaster-of-Paris Splints. Lewis H. McKinnie, M. D., Colorado Springs, Colo... 197

Volkmann's Contracture of the Forearm, with Presentation of a Patient. Clifford U. Collins, M. D., Peoria, Ill. 205

Operative Technic in Spina Bifida. Joseph Rilus Eastman, M. D., Indianapolis, Ind..... 215

A Mixture of Ethyl Chloride, Chloroform, and Ether for General Anesthesia—An Experience in War Surgery. E. P. Quain, M. D., Bismarck, N. D..... 227

Rhinophyma. M. G. Seelig, M. D., F. A. C. S., St. Louis, Mo. 239

The Operative Treatment of Vesico-Vaginal Fistulæ. E. S. Judd, M. D., F. A. C. S., Rochester, Minn..... 251

Medical Education in Greece. Carl E. Black, A. M., M. D., F. A. C. S., Jacksonville, Ill. 273

Case-Reports of Merycism Associated with Appendicitis. Frank G. Nifong, M. D., Columbia, Mo. 283

Diaphragmatic Hernia. Theodore F. Riggs, M. D., Pierre, S. D. 291

Jaundice and Its Surgical Significance. C. H. Mayo, M. D., F. A. C. S., Rochester, Minn. 273

Gastro-Enterostomy Still the Treatment for Chronic Gastric and Duodenal Ulcer. Robert C. Coffey, M. D., Portland, Ore. 315

Intestinal Anastomosis—Newest, Quickest and Best. B. M. Ricketts, M. D., Cincinnati, O. 345

A Congenital Anomaly of the Duodenum and Its Surgical Significance. Leonard Freeman, M. D., F. A. C. S., Denver, Colo. 349

Abdominal Drainage. D. W. Basham, M. D., Wichita, Kans. 355

The Surgical Treatment of Empyema. W. W. Grant, M. D., Denver, Colo. 371

Operative Results in Two Hundred Breast Tumors. Byron B. Davis, M. D., Omaha, Neb. 389

Operation for Advanced Carcinoma of the Tongue or Floor of the Mouth. Vilroy Papin Blair, A. M., M. D., F. A. C. S., St. Louis, Mo. 405

Cancer Involving the Mouth. George Noble Kreider, A. M., M. D., F. A. C. S., Springfield, Ill. 415

Arthroplastic Operations, with Report of Cases of Arthroplasty of the Temporomaxillary Joint; Also of the Elbow Joint. A. A. Kerr, M. D., Salt Lake City, Utah 423

Intentional Removal of Skin and Other Tissues Overlying Deep-Seated Inoperable Cancer, a Necessity for Effective Treatment with *X*-Ray or Radium, with Report of Relative Absorption of Rays by Skin, Fat and Muscle as Compared with Various Thicknesses of Aluminum, by G. W. Warner, A. B., of the Ryerson Laboratory, University of Chicago. Emil G. Beck, M. D., F. A. C. S., Chicago, Ill. 433

BOSTON MEDICAL
MAR - 5 1930
LIBRARY

Executive Session

Transactions of the Twenty-ninth Annual Meeting Held in Kansas City, Missouri, December 5 and 6, 1919

December 5, 1919, First Day—Morning Session

The Association met in the ball-room of the Muelhbach Hotel, and was called to order at 9:40 A. M., by the President, Dr. Roland Hill, St. Louis, Missouri.

Dr. L. H. McKinnie, Colorado Springs, Colorado, read a paper entitled "A New Method of Applying Plaster-of-Paris Splints." The paper was discussed by Drs. Coughlin, Porter, Freeman, and, in closing, by the essayist.

Telegrams were read from Dr. A. A. Kerr, Salt Lake City, and Dr. James F. Percy, Galesburg, Illinois, regretting their inability to attend the meeting.

The courtesies and privileges of the floor were extended to visiting physicians.

Dr. Charles D. Lockwood, Pasadena, California, read a paper on "Artificial Impaction of the Femur in the Aged," which was discussed by Drs. Lord, Richardson, Nifong, and, in closing, by the essayist.

Dr. Edward Evans, La Crosse, Wisconsin, followed with a contribution on "Rare Fractures," with lantern-slides, which was discussed by Drs. Smith, Tennant, Hopkins, Magie, and, in closing, by the essayist.

Dr. Willard D. Haines, Cincinnati, Ohio, read a paper entitled "Rare Bone Injuries; Report of Two

Cases,—(a) Dislocation of the Tarsal Scaphoid; (b) Double Fracture of the Ischiatic Tuberosities." The paper was discussed by Dr. Pearce, after which the discussion was closed by the essayist.

Dr. Melvin B. Clopton, St. Louis, Missouri, read a paper entitled "Tuberculosis of The Great Trochanter."

Dr. Gustav Schwyzer, Minneapolis, Minnesota, followed with a paper entitled "Our Surgical Experience with Tuberculosis of the Joints; Rollier's Heliotherapy."

Dr. Richard W. Corwin, Pueblo, Colorado, read a paper on "Traumatic Osteomyelitis," with slides.

These three papers were discussed together by Drs. Jepson, Kreider, Beck, Mayhew, Grant, and, in closing, by Drs. Schwyzer and Corwin.

President Hill spoke of the importance of increasing the membership of the Association. The Association was organized twenty-nine years ago, with a membership of 150, since which time the number of desirable men in the Western territory has materially increased. A two-thirds vote, he said, was necessary to increase the membership. At the present time, the Association has a large waiting list.

Dr. B. B. Davis: I think our President is mistaken as to the number of members in the Association when it was organized. At first, it was 100, and then, by amendment to the constitution, it was increased to 125, and later to 150. I am thoroughly in favor of the proposal to increase the membership. I think the Association ought to be larger, and I would like to make a motion that we increase the membership from 150 to 200.

Dr. W. W. Grant: I second the motion.

Dr. Jabez N. Jackson: I move so to amend the constitution that we increase the membership to 175. The amendment was seconded.

Dr. John P. Lord: It seems to me, in view of the large waiting list, that by electing a fair number of eligible candidates, we shall nearly reach the two hundred limit.

Dr. W. W. Grant: I believe that to increase the membership to 200 is the right thing to do at this time. The judicious selection of members is always a good thing.

The amendment to increase the membership to 175 was put to a vote and declared carried.

On motion the Association adjourned until 2 P. M.

First Day—Afternoon Session

The Association reconvened at 2. P. M., and was called to order by the President.

Dr. Thomas S. Cullen, Baltimore, Maryland, read a paper (by invitation) entitled "The Distribution of Adenomyomata Containing Uterine Mucosa," which was illustrated by slides. The paper was discussed by Dr. Sherk, and, in closing, by the essayist.

Dr. Eric P. Quain, Bismarck, North Dakota, read a paper on "The Use of Ethyl-Chloride as a General Anesthetic," and the paper was discussed by Drs. Clark, Sala, Coughlin, Beck and Farr, and the discussion was closed by the essayist.

Dr. Major G. Seelig, St. Louis, Missouri, read a paper entitled "Rhinophyma," which was discussed by Dr. Beck.

Dr. Edward Starr Judd, Rochester, Minnesota, followed with a paper entitled "Results of Operation

for Vesicovaginal Fistula." The paper was discussed by Drs. Eastman, Abbott, Cullen, Quain, Schwyzer, and, in closing, by the essayist.

Dr. Clifford U. Collins, Peoria, Illinois, read a paper on "Volkmann's Contracture of the Forearm," with slides. The paper was discussed by Drs. Hertzler, Freeman, Sanders and Fairchild.

Dr. Joseph Rilus Eastman, Indianapolis, Indiana, read a paper entitled "Operative Technic in Spina Bifida," which was discussed by Dr. C. H. Mayo.

Dr. V. P. Blair, St. Louis, Missouri, read a paper on "Cancer of the Tongue," after which the Association, on motion, which was duly seconded and carried, adjourned until 7:30 P. M.

First Day—Evening Session

The Association reconvened at 8 P. M., and was called to order by the President.

Preceding the Scientific session, the annual banquet was held, after which the President, Dr. Roland Hill, delivered his address entitled "Medical Problems Suggested by the War," which was followed by an address on "Greek Medicine" (illustrated), by Dr. Carl E. Black, Jacksonville, Illinois.

Adjourned.

Saturday, December 6—Second Day—Morning Session

The Association met at 9:15 A. M., and was called to order by the President.

Dr. Frank G. Nifong, Columbia, Missouri, read a paper entitled "Merycism Associated with Appendi-

citis." The paper was discussed by Drs. Blesh, Coffey, Davis, and, in closing, by the essayist.

Dr. T. F. Riggs, Pierre, South Dakota, read a paper on "Diaphragmatic Hernia." The paper was discussed by Drs. Blesh, Richter, Jepson, Coffey, and Lockwood, and the discusion was closed by the essayist.

Dr. R. C. Coffey, Portland, Oregon, read a paper entitled "Posterior Gastro-enterostomy Still the Surgical Treatment of Gastroduodenal Ulcer; Ideal Composite Technic." The paper was discussed by Drs. Cullen, Eastman, Tennant, Davis, Haines, Schwyzer, Kreider, Bowers, and, in closing, by the essayist.

Dr. Charles H. Mayo, Rochester, Minnesota, read a paper on "Jaundice and Its Surgical Significance." The paper was discussed by Drs. Abbott, Cullen, Richter, Sala, Bowers, Davis, Basham and Coffey, and discussion closed by the essayist.

Dr. Leonard Freeman, Denver, Colorado, read a paper entitled "A Congenital Anomaly of the Duodenum and Its Surgical Significance."

Dr. D. W. Basham, Wichita, Kansas, read a paper entitled "Abdominal Drainage."

These two papers were discussed together by Drs. Collins, Shere, Coffey, Quain, Grant, Macrae, Pearce, Coughlin, Nifong, Davis, after which the discussion was closed by Dr. Freeman.

On motion the Association adjourned until 2 P. M.

Second Day—Afternoon Session

The Association reconvened at 2 P. M., and was called to order by the President.

Dr. W. W. Grant, Denver, Colorado, read a paper entitled "Surgical Treatment of Empyema." The paper was discussed by Drs. Hollowbush, Blesh, Mann, Beck, Sala, Connor, and Mayhew, and, in closing, by the essayist.

President Hill said it was necessary for the Association to decide upon the next place of meeting.

Dr. Charles D. Lockwood invited the Association to hold its next meeting in Los Angeles, California.

An invitation was also received to hold the next meeting in St. Louis, Missouri.

On a test vote Los Angeles received 26 votes, and St. Louis 18. Los Angeles, therefore, was declared to be the next place of meeting.

As to the time of meeting: Dr. W. W. Grant moved that it be left to the Executive Council after a conference with the California members.

Seconded and carried.

Secretary Mann presented the report of the Executive Council as follows:

REPORT OF THE EXECUTIVE COUNCIL

There were present at the meetings of the Executive Council Drs. Roland Hill, Howard Hill, A. W. Abbott, E. S. Judd, Edward Evans, Leonard Freeman, J. R. Eastman, and A. T. Mann.

The following men are recommended for election to membership:

Dr. Fred W. Bailey, St. Louis, Mo.
Dr. Wm. E. Leighton, St. Louis, Mo.
Dr. James T. Case, Battle Creek, Mich.
Dr. Wm. Senger, Pueblo, Colo.

Dr. A. C. Strachauer, Minneapolis, Minn.
Dr. Robt. Earl, St. Paul, Minn.
Dr. Archibald L. McDonald, Duluth, Minn.
Dr. Wm. A. Coventry, Duluth, Minn.
Dr. Chas. S. Venable, San Antonio, Texas.
Dr. Arthur W. Ide, Brainerd, Minn.
Dr. Elmer D. Twyman, Independence, Mo.
Dr. Frank R. Teachenor, Kansas City, Mo.
Dr. Melvin S. Henderson, Rochester, Minn.
Dr. Fosdick Samuel Jones, Denver, Colo.

FOR HONORARY MEMBERS

Dr. Clarence M. Nicholson, St. Louis, Mo.

Dr. Paul Sorkness, Fargo, N. D.

FOR THE ELECTIVE MEMBERS OF THE EXECUTIVE COUNCIL

Dr. Charles D. Lockwood, Pasadena.

Dr. E. P. Quain, Bismarck.

The following are recommended as officers for the coming year:

President, Dr. Arthur T. Mann, Minneapolis.

First Vice-President, Dr. Richard W. Corwin, Pueblo.

Second Vice-President, Dr. E. M. Sanders, Nashville.

Secretary-Treasurer, Dr. Warren A. Dennis, St. Paul.

The Treasurer's report was approved and is as follows:

TREASURER'S REPORT

Balance on hand Dec. 21, 1918	$ 716.10
Fees and dues	1,755.00
Extra tickets to the banquet	70.00
	$2,541.10
Paid for reporting Chicago meeting	110.40
Paid for printing	153.19
Paid for printing and mailing 1918 Vols. of Transactions	979.87
Honorarium to Secretary	100.00
Paid for emblems	29.16
Paid for Kansas City banquet	495.00
Petty cash paid	16.00
	$1,883.62
	$2,541.10
	1,883.62
Balance on hand December 6, 1919	$ 657.48

It is recommended that the annual dues for the coming year be $12.00.

As the place of meeting for next year, Los Angeles, California, is recommended, with Dr. Charles D. Lockwood as Chairman of the Committee on Arrangements, and the dates, December 3 and 4, 1920.

ARTHUR T. MANN, M. D.,
Secretary.

The President: What disposition do you wish to make of the report of the Executive Council?

Dr. W. W. Grant: I move it be adopted as presented.

Seconded and carried.

Secretary Mann called attention to the deaths during the year of Ex-Presidents, James E. Moore and L. W. Littig.

Dr. Harry P. Ritchie, St. Paul, Minnesota, presented the following obituary report with reference to the late Dr. James E. Moore:

Dr. James E. Moore died at his home in Minneapolis in November, 1918. He was long an active member of the Western Surgical Association. At the time of his death he was Professor and Chief of the Department of Surgery of the University of Minnesota Medical School.

It is given to but few men to depart this life and record a career of more interest, of more influence, of more lasting benefit. Not only in his profession did he exercise the greatest weight in its many problems, but with widest vision, the fullest optimism, and the keenest decision did he deal with many questions, social, civic, and national. Were I to point out the chief strength of his character, I would use broadly the word *patriotism*. He was imbued with this sentiment with all the power of his body and mind. He was for his country, he was for his home, he was for his city, he was for his school, he was for his students, he was for his patients, he was for the best, upright, moral and efficient practice of medicine and surgery, and, best of all, he was for his friends.

His boys, as he was fond of designating his associates while in more personal touch, saw that the real foundation of his character was a gentle, kind, and ever-winning disposition, which held all those in contact with him to the highest ideals and stirred within them a feeling of love and consideration.

He was aggressive in his ambition; he was original in his ideas; he was forceful in his actions,—a positive character supported by a profound moral sense, clear judgment and an honesty of purpose which commanded the respect and esteem and honor of all.

Guided by such principles could it be otherwise than that he should attain the eminent position that he held among us, that he should leave such wonderful records in the literary archives of this Association and an indelible imprint upon our memory?

Dr. Clifford U. Collins, Peoria, Illinois, presented the following memorial of Dr. L. W. Littig, Davenport, Iowa:

When one of our members lays his instruments down for the last time, and exchanges his operating gown for the shroud, and passes on to "that bourne from which no traveler returns," it is fitting that we should pay some tribute to the excellent characteristics of the life he has lived among us, and the example he has set for us.

I knew Dr. Littig for a good many years, and knew nothing to his discredit. Among my first impressions of him was his indomitable courage. He had suffered from a general infection that had stiffened his joints and had incapacitated him for his surgical work. He was attending surgical meetings and was carrying a rubber ball and a small contrivance with springs, in his hands, and was constantly exercising his hands and fingers on these contrivances in an endeavor to limber up the joints, so that he might get back to his beloved work.

His courage was manifested in another way. He saw and pointed out, before the College of Surgeons had taken up the work of standardizing hospitals, some of the things that were wrong with our hospitals. He had the courage to lift an insistent voice urging their correction, although he knew as well as anyone that it would cause him trouble in the hospitals of his home city.

He read a paper before the staff of the St. Francis Hospital in Peoria, upon my invitation, about a year before he died, and in a conversation at that time he gave evidence that he well knew the usual fate of the reformer, of the man who tries to pry humanity out of the rut of complacent satisfaction with unsatisfactory conditions.

Dr. Littig was an honest, progressive surgeon, and what better tribute can I pay to his memory? He detested fraud, show, and pretence in any form, and was always frankly outspoken against it. While he was living, his life shed a constant influence for better surgery and higher ideals. The Western Surgical Association appreciated his value as a member and as a surgeon, and honored him and itself by making him its President, in 1916.

One of the beauties of a good life is that its influence does not end with death. The Western Surgical Association

will be better for years to come for having had Dr. L. W. Littig as one of its members and consellors.

Dr. E. M. Sala: I move that these reports be adopted as presented, printed in the Transactions, and a copy of them be sent to the families of the deceased.

Seconded and carried.

Dr. Emil G. Beck, Chicago, Illinois, read a paper entitled "What Shall be Done for Recurrent Deep-Seated Carcinoma?" The paper was discussed by Drs. Skinner, Lord, and, in closing, by the author of the paper.

Dr. E. M. Sanders: I feel that before we adjourn we should take some cognizance of the hearty welcome that the Kansas City members have extended to us. We have been beautifully, heartily, and cordially received; and I want to make a motion that we express our thanks to the members of the local committee of arrangements by a rising vote for their hospitality and uniform courtesy throughout this meeting.

Seconded and carried.

Dr. B. B. Davis, Omaha, Nebraska, read a paper entitled "Breast Tumors, Benign and Malignant." The paper was discussed by Drs. Hill, Cullen, Plummer, Haines, and, in closing, by the essayist.

President Hill: I have a very pleasant duty to perform, namely, to introduce to you the new President.

I will ask Dr. Howard Hill and Dr. William T. Coughlin to escort Dr. Mann to the platform.

Dr. Hill, in introducing his successor, said:

It is with a great deal of pleasure coupled with no little regret, that I am introducing to you your new President, Dr. Arthur T. Mann, of Minneapolis. It gives me great pleasure to introduce him because he is so worthy of the Presidency of this Association. He has earned the position

time and again more than any other man in the Association. At the same time, I am introducing him with a great deal of regret because you have lost a most efficient Secretary. Anyone who acted as President when Dr. Mann was Secretary had a very easy job indeed. It has certainly been a great pleasure to me to have occupied this position with him as Secretary, and this pleasure I feel is now enhanced by turning the position over to our friend, Dr. Mann. (Applause.)

Dr. Mann, in accepting the Presidency, said:

I feel very much gratified—in fact, I feel greatly honored to be elected President of this Association, which is one of the most active and promising surgical associations we have.

I know you do not want a speech. I will say this, however, that at our meeting in Kansas City, in 1906, I was elected Secretary, and personally it seems very fitting that it should be in Kansas City that this honor should come to me of being your next President.

Again, I wish to thank you for the distinguished honor you have conferred upon me. (Applause.)

Dr. George N. Kreider, Springfield, Illinois, read a paper entitled "Cancer of the Mouth," which was discussed by Drs. Bowers, Lord, Jepson, and Lockwood, after which the discussion was closed by the essayist.

In bringing the meeting to a close, President Mann said: "This closes one of our most successful meetings, if not the best meeting we have ever had. We have had the largest attendance here of any place we have been.

"I feel that our new Secretary is a man whose services will prove unusually efficient. He is a strong man, and I am sure will like the work."

As there was no further business to come before the meeting, on motion, which was duly seconded and carried, the Association adjourned *sine die*.

Arthur T. Mann, M. D.,
Secretary-Treasurer.

President's Address

MEDICAL PROBLEMS SUGGESTED BY THE WAR

ROLAND HILL, M.D., C.M.

ST. LOUIS, MISSOURI

No one could be elected president of the Western Surgical Association without having the most sincere appreciation of the very high honor conferred on him. I assure you it is one that I value most highly, and at the same time I feel that it carries with it responsibility of a marked degree.

In seeking for a theme to discuss at this meeting it has seemed to me more timely to consider some of the medical problems suggested as a result of the recent international upheaval than to present a strictly scientific subject.

The world's greatest war, now so happily terminated, shook to its foundations the whole fabric of our modern civilization and threw an almost overwhelming strain on all branches of our national industry. The spur of self-preservation applied to the industries of the country in the prosecution of the conflict, has resulted in many new and valuable discoveries applicable to times of peace. The statement that "necessity is the mother of invention" was never more strikingly illustrated than is shown by a study of the footsteps of this great country when once determined on war.

Almost unprepared at first, practically ignored by Germany and regarded by the Allied powers as a

source of industrial more than military strength, America became ever an increasing factor until the battles of Chateau-Thierry, Belleau Wood and the Argonne Forest proved determining factors in causing the Central Powers to sue for peace. Behind this great military effort were coördinated the great industries of the country. All our mechanical forces and the arts, sciences, and professions came to the support of the nation in this period of anxiety and danger.

No profession responded more nobly than did the profession of medicine. The internist, the research man, the surgeon, in fact, representatives of every department of the profession, were equally ready in response to the nation's call. Approximately 50,000 civilian doctors joined the colors and 70,000 more expressed their willingness and obligated themselves to do so by applying for membership in the Volunteer Medical Service Corps. We were particularly gratified with the record made by the medical profession of the city of St. Louis. Approximately 600 entered active service, and of the remainder, about 1,300, the Volunteer Medical Service Corps, of which I was chairman, succeeded in getting pledges from all but eighteen. We doubt if this record has been equaled by that of any other city in the country.

The Western Surgical Association alone had a representation in active service of more than one-third of its membership, and it is doubtful if there was a single one of the remainder not engaged to a greater or less extent in activities pertaining to the war.

This great national upheaval was not without far-reaching effects on the medical profession. The value of medical and surgical services was never more fully recognized than it was by the commanders of the armies in the field. We were enabled to learn many things about the protection of large bodies of

men that we did not know before. We also learned a great deal about the treatment of wounds that will be far-reaching in its effects, especially among the members of our profession who handle traumatic surgery. The war, however, created an opportunity for "irregular" practitioners, osteopaths, chiropractors, and Christian scientists, who may be termed the Bolsheviki of medicine, to seek recognition, and in some of the states they succeeded in securing legislative support that would have been impossible under normal conditions.

In the state of California we notice that even osteopaths were admitted as internes in the state hospitals. Later on they were made members of the medical examining boards of Texas, California, and Washington. The fact that the attainment of medical education has been made so difficult led to a scarcity of medical men on the advent of the war that gave to these irregulars the chance they have long been striving to secure to establish themselves firmly throughout the country.

Today a man who would enter medicine must spend several of the best years of his life and many thousands of dollars to perfect himself for the duties of the regular profession. This, with the war, has tended to cause many men to seek the easier path of entering one of the irregular branches. It has ever been easier to plant a noxious weed than to get rid of it and, if there ever was a time when we needed surgical organization with a view of protecting the people of the country and the surgeons of the country from the noxious influence of the irregulars, that time is the present. We have such an organization in the American College of Surgeons. It is time that each one of us should realize that in the support of this organization we have a force with which some of our ideals may be accomplished. The aims of the college

appeal to all of us. It seeks to uplift the surgeon and put him on a plane where he will be universally recognized and respected by every one. The college has made excellent progress in the work of hospital standardization, but it will fall far short of what it should accomplish unless it gets legislative recognition in each one of the states. The American National Examining Board is seeking to secure such recognition for itself, and there seems no reason why the American College of Surgeons should not do likewise.

At the present time I can see no reason why the American College of Surgeons should not seek such a plane that its degree would be recognized by the legislature of every state, and the holder thereof be permitted to practice surgery without any of the obstacles that are now met in going from one state to another. What we want in this country is a national surgical degree like that of the Royal College of Surgeons of England, respected and recognized as a national token of efficiency in every state in the Union. Personally, I should like to see the American College of Surgeons have two degrees: a membership for the younger men and those of moderate proficiency, and a fellowship degree for the men who have shown unusual attainments. Furthermore, I should like to see it more than a national degree, a degree available to any man presenting the proper qualifications, no matter whether he came from Europe, South America, or Australia. The more universally it is recognized the greater will be the credit to American surgery.

In thus endorsing the American College of Surgeons I am doing so because the College represents surgical organization of a high degree. I realize full well that so far it has been a disappointment to many of its members. There are those who regard it as

more of a liability than an asset. It represents, however, organization; and there is not a surgeon in the country who does not realize that the strength of organization is needed, particularly at the present time. If the College is not working to best advantage then its methods should be changed, for this organization is large enough and strong enough to attain great good. When effective effort is made to secure legislative support throughout the Union then the laity will soon recognize the difference between the physician and the surgeon. The college will in this way become a necessity for all young men who are looking forward to surgical achievements. Then it will be a definite asset to every one of its members.

The importance of hospitals and hospital organization has been emphasized by the recent work of the American College of Surgeons in conjunction with the American Medical Association and other bodies. Many phases of this question were ably presented by the presidential address of our late lamented Fellow, Lawrence W. Littig, of Davenport, Iowa. I believe that in the general run of hospitals sufficient time and care are not devoted to instruction of internes and others engaged in caring for the patients. To my mind, every institution devoted to the care of the sick should be a center of greater or less degree for the education of those who are devoting their lives to this work. Members of all departments of service should be instructed in detail as to the latest and best methods of doing the work assigned to them. The house surgeon should have clinical instruction from his chief and not be left to learn simply as he can by his own observation, as is the rule in most hospitals not devoted to the instruction of the student. By devoting a little time to the internes their interest will be increased and the surgeon will be more than repaid for his time by their added efficiency and devotion.

When the bright light of military necessity was brought to bear in the search for soldiers in our strenuous preparation for war, the one vital factor that stood out in bold relief was the large number of men disqualified for military service because of physical defects. It is doubtful if many people in the country, even the medical men, realize what a large percentage of the male population of the country had physical defects of such a character as to render them unfit for military service.

It is probable that no other defect stood out more prominently than that of hernia. The number of cases of hernia and varicocele was almost incredible. These men were not considered able to render their country their best physical efforts until these defects were remedied. The majority of them, undoubtedly, would have gone through life suffering from their disability if it had not been found and remedied by the Government in its efforts to draw on the man power of the nation. The percentage of our people afflicted with hernia, considering an average of 1 to 15, would show that approximately 7,000,000 of our population are afflicted in this way. The impairment in some cases may be slight, but, unquestionably, a very large number suffer from more or less impairment of their physical power. Where such a large percentage of the population is afflicted, undoubtedly there will be some lessening of the productive power of the country.

Adenoids and tonsils and defective teeth are other lesions that may be classified with hernia as causing directly or indirectly a loss of physical power. Under these conditions, would it not be better to have careful medical inspection of all children in very early life, and all physical defects card-indexed? In this way the general public would be gradually educated to the point of seeking relief for these curable defects. At the present time in certain communities we have

medical boards associated with the public schools. These boards are composed of a number of doctors and nurses who search carefully for all defects that impair the children, both mentally and physically, and put such children in the very best environment for having these defects remedied. In highly organized communities very effective work has been accomplished. In other communities the work has not been so effective, and in still other communities, embracing probably by far the larger percentage of the young of our population, this work is not carried on in anything but a perfunctory manner or not at all. To my mind this is a matter of national importance.

I think the health of the young of the country is one of the most important of our national assets. I believe that this work should be uniform throughout the country, and the only way to make it uniform and make it effective is to have it under Government control. In Washington we have bureaus that have to do with quarantine and marine hospital service. The public-health service is largely a quarantine service. To my mind this is a service that should be enormously enlarged and extended until it is responsible for the welfare of every community in the country. If this is not feasible, then we should have a national department of health headed by some medical man of high standing who should be a member of the highest of our national councils.

The curable defects, like hernia, tonsils, and adenoids, should be remedied in early life. It may be a debatable question whether or not children suffering from these defects should be cured by men under the supervision of the Government, but it is not a debatable question that these defects should be remedied by some one. Every child that is handicapped by one of the curable surgical lesions should have that handi-

cap removed before entering on the productive period of life, so that, when assuming the active burdens of manhood, its usefulness may not be impaired by any condition that could possibly be remedied.

It is probable that no other problem associated with the physical health of the men was of more importance than that of venereal diseases. The war did one great national service when it showed to us this problem in its true light. The influence of this class of diseases alone on the nation's manhood cannot be accurately estimated. A study of the army statistics, however, brings before us the fact that we have too long ignored this peril and condoned its ravages. From April, 1917, to September, 1918, the loss to the army from venereal diseases alone represented 2,295,000 days of service. This occurred in young men living under strictly military discipline and subject to military inspection. If this loss of time and labor in this body of men was so great where they had every care that enlightened prophylaxis and treatment could give, it is almost inconceivable what the ravages would be in a like body of men not subject to military discipline where their inclinations and desires acknowledged no restraint. As a matter of fact, it was found that only one-sixth of the venereal diseases in the army originated while the men were in military service, and five-sixths were found to be in men already infected when they entered the army. The loss of time caused by these diseases while under army observation would be but a small percentage of the loss caused by them in their remote and indirect effects. As medical men we know that the elusive gonococcus comes to light months after the patient considers himself cured. The ravages wrought by these uncured cases form one of the greatest tragedies of our civilization. The individual afflicted with an acute case realizes his condition and, as a rule, will

try to avoid conveying the disease to others. In the subacute stage the vast majority think that the infective element is gone and the danger of communication past. These men are the great carriers of this affliction. To them we look for the gonococcal invasion of the wife and oftentimes infection of the eyes of their children. It is estimated that one-half the blindness in the world is directly traceable to this cause. Sterility in the male is another one of its very frequent sequelæ. The organism lying latent in the cervix for months, may invade the tubes and render the women chronic invalids only to be relieved by surgery. The desires and joys of motherhood are usually denied women whose tubes harbor the gonococcus. If pregnancy does take place the ovum may be held in the diseased tube and the woman's life seriously impaired by extra-uterine pregnancy. Even more to be dreaded than the lesions caused by invasion of the gonococcus is syphilis with its insidious and far-reaching results. In this disease all symptoms and manifestations may disappear for years and then suddenly manifest themselves in the individual or in his offspring. We have all seen cases of permanent blindness and locomotor ataxia years after the disease was supposed to have been cured. How many cases of cerebral hemorrhage in men below fifty years of age belong to remote consequences of this infection? The effects on the individuals themselves, while of vital importance, really fade into insignificance when contrasted with the ill effects wrought on the wives and children of those afflicted.

The elimination of the venereal diseases is one of the greatest of our national problems. The tendency to ignore them has disappeared. The greatest of our scientific men backed by the influence of the Government are now trying to find some way of overcoming the effects of these diseases.

That these diseases can be reduced to a minimum I believe to be a matter of certainty. The results obtained in the service of the American army in Porto Rico and the work of the British army in Port Said all go to prove that their elimination is but a matter of education and efficient control.

There are a few well-known factors of the venereal diseases that I would like to enumerate: 1. These diseases are rampant in every walk of life. 2. They are the only diseases of importance that have not been placed under legal control. A child may have measles, whooping cough, diphtheria or scarlet fever, and every effort is made to safeguard the community from contamination with these infections. The house is placarded, the other children are kept from school, and every effort is made to trace the source of the infection. The case is regarded as a menace to the community and the medical guardian of the community, the health officer, becomes directly responsible to the community for its proper control. How different is the condition where an individual contracts gonorrhea or syphilis! There is no valid law forcing the physician to report the infection in the vast majority of communities. If the man is intelligent he may seek the advice of a competent physician, follow it carefully, take the treatment instituted until he is well, and not jeopardize the community. On the other hand, in the vast majority of cases the woman from whom he contracts the infection does not seek medical advice and continues to spread the infection right and left among her admirers. Where the victims belong to the ignorant classes little, if any, effort is made by either party to be cured properly or to seek to protect the community by self-restraint.

The problem of handling the question of venereal diseases is one of the most vital we have to solve and one of the most difficult. The greatest factors towards

this end are education and legalized control. The first and most important step I believe to be one of education. No important question vitally affecting the people is less understood than that pertaining to the venereal diseases. If their causes and results could be thoroughly impressed on the masses of people in every walk of life a great deal would be accomplished. As a matter of fact, although education in these matters has been tabooed, we as surgeons see what great good has resulted from the limited knowledge that has already been disseminated. Twenty-five years ago pus tubes were being constantly encountered in all stations of life. They were found among highly intelligent women almost as frequently as among the ignorant classes. Today this is all changed. Venereal pelvic infections in educated women are much more rare than they were two decades ago. No one realizes this fact more fully than men who are doing pelvic surgery. While there has been such a marked decrease of these conditions among the educated, still we find that in the ignorant classes the same unfortunate state persists as in the past. Proof of this can be found in the gynecological service of any large charity hospital. Legalized control is absolutely necessary. A standard form of laws has been approved by the social hygiene board at Washington. These laws, however, will need to be considered very carefully before being adopted. They are made so drastic that individuals guilty of illicit intercourse are subject to very severe punishment in prison. It is very doubtful if some of these provisions will not have a directly contrary effect to what is desired. The means of tracing violations of the moral law are found largely in the resulting venereal infections. If the man who contracts gonorrhea or syphilis knows that he has a prison offense staring him in the face if he goes to a doctor he is liable to keep the matter secret and thus lead to spreading of the infection. To my

mind we should have drastic laws, but more of the drastic element should be in causing these cases to be reported so that they can be watched and cured, and the infected individuals eliminated as carriers. The health officer should have the same power over them as he has over any other infectious disease. Every effort should be made to find the carriers; and those infected should be kept under observation until they are found free from the power of infecting others.

I am not one of those who believe that laws will ever adequately control the sexual impulse. I do believe, however, that the sexual diseases under legalized control can be reduced to a minimum and the country freed from the horrible conditions that prevail at the present time.

While the questions of disability due to venereal diseases and that due to remedial defects were forced into prominence by the urgent need of the nation for men for the army, another problem of vital importance was brought to the front in the course of the routine and searching examinations that were made. The problem I speak of is the one dealing with defects that are incurable. This is a great and far-reaching question that expands and becomes more difficult the more one ponders over it. One of our statesmen has said that the manhood of the nation is the nation's greatest asset. This may be accepted as a truism. Every normal child born in the country is a national asset, while every incurably defective child is a probable national liability. The causes of permanent incurable defects in human beings are many. Some cannot be traced and seem to be purely accidental. Others, however, and probably a large percentage of them, are strictly of congenital origin and can be traced back to strictly preventable causes. Approximately one-half of the defects were of congenital origin.

The war will not have been fought in vain if it leads to a recognition and correction of the evil influences that have afflicted humanity at large. The benefits wrought by stimulation of our commercial industries are colossal indeed, but cannot be compared with the results likely to be achieved by a closer analysis and study of the individual elements of our population. Never before have we had presented to us so clearly the large percentage of defectives existing among us. It has never before been so forcibly impressed on us how large a percentage of these defectives are curable, and, I am sure, but few of us realize the number of these defectives who cannot be cured. The class of defectives that cannot be remedied present one of the most interesting problems in our national life. It leads us to a consideration of the duties of the generations of the present to those of the future. In other words, it brings us fairly and squarely to the eugenic question. While the venereal question is the paramount one of the present, unquestionably the eugenic question is the most vital one of the immediate future. While we cannot cure the large percentage of congenital weaklings that we have among us, we should be able to devise means to secure from future generations a comparative immunity from them. This is a duty we owe to posterity.

It is a well-recognized fact that a farmer or horticulturist to succeed must pay every attention to the condition of his soil, the quality of the seed he plants, the character of the stock that he breeds. The horticulturist must select his plants most carefully to see that they are made free from noxious influences if his orchard is to be made a success. The question may be asked in dealing with human beings, "Am I my brother's keeper?" This question may be answered in the negative as regards the ordinary acts of the individual. The minute, however, a man so acts as to

impose an increased burden on society at large, such act should be amenable to society's laws. The influence of heredity is being recognized by the law makers of many of our states. It seems to be dawning on the people of this country that it is necessary to control births among certain classes of society if we are to eliminate defectives in the present and future generations. Laws seeking to control undesirable marriages are now found on the statute books of fifteen states. Many of these laws are loosely drawn and easy of evasion. In some states, however, notably Michigan and Wisconsin, they have been made sufficiently stringent to help overcome some of the evils we seek to eliminate.

The law of Michigan may be taken as a model of the marriage laws that now exist. It says that no insane person, no idiot, or no person who has been afflicted with syphilis or gonorrhea and has not been cured shall be capable of contracting marriage. Any person who has been afflicted with syphilis or gonorrhea and has not been cured who shall marry, shall be deemed guilty of a felony and be punished by a fine not less than $500 or more than $1,000, or by imprisonment in the discretion of the court. And it provides that in all prosecutions under the act a husband shall be examined as a witness against his wife, and a wife shall be examined as a witness against her husband, whether such husband or wife consents or not; and provided, further, that in all cases arising under this act any physician who has attended or prescribed for any husband or wife for either of the diseases above mentioned, shall be compelled to testify to any fact found by him from such attendance. It will readily be seen that from the drastic character of this law, the legislators of our country are beginning to realize the great importance of the venereal disease and also of the eugenic factor in marriage.

The importance to future generations of preventing transmission of insanity or other grave conditions is just beginning to be realized. The necessity of cutting off certain congenital strains is seen by a study of the census of 1910, which shows that 841,244 patients in the United States were inmates of institutions for antisocial and unfortunate classes of the country. The number of those in these institutions is constantly shifting as the inmates and patients are only under custodial care for a few years. From this it may be seen that of the total number of persons living a much larger percentage has been legally committed to the state's custody than the census shows. Besides the persons who have been thus committed, there are many others of equally unfortunate hereditary qualities who have never been committed to such institutions. Many of these are taken care of by private means. From these classes come the progeny that means such a strain on future generations. To eliminate them it is necessary to cut off the inheritant strains that produce them.

While the enforcement of the marriage laws tends to prevent the union of such types we question if this is enough and fully believe in the endeavors that are made to eliminate these defectives by more radical means. To my mind this is a question of great importance and one of the most delicate we can be called on to decide.

It is not generally realized that sterilization laws have been passed by the legislatures of twenty-two states. In a few states the courts have declared them unconstitutional. In some, like Washington, the primary aim has been punitive, but in others, like California, the eugenic features have been predominant. In California the law is largely confined to the insane and feeble-minded, and more than 1,000 operations have been performed in that state. We know abso-

lutely that from these strains come the children that fill our poor-houses, our asylums, our jails, our homes for feeble-minded, and our murderers' cells; and there is no question that society would be relieved of a very great and definite burden if certain of these well-defined classes were denied the power of procreation.

Personally, I am coming to believe that the sterilization of the hopelessly insane and the feeble-minded should be done. Perhaps further study will show that the process could be justly extended to include other classes with advantage. The importance of the subject is so great that it should be under national control. The method of sterilization should be most carefully studied. To my mind the use of the Röntgen ray for this purpose deserves very careful consideration. It is known that this will definitely cause temporary sterility in a human being; and a further study of it undoubtedly should be made. If it were found that it could be made efficient it would make the process very much easier and rob it of many of its offensive features.

Perhaps many of the views that have been expressed in this address may be regarded by most of you as too radical. Before the war one would hardly have dared to give expression to some of the thoughts that I have submitted for your approval. The war, however, has taught us to look on facts as they are, and not as we would wish them to be.

The views expressed here are in many cases fundamental in character and I believe will stand the most careful analysis. Much of the time and energy of the medical profession has been devoted to the care of defectives. Every consideration is given to our insane and our feeble-minded and to the reconstruction of our criminal classes. Little attention has been

paid to the question of their elimination from the generations of the future. With the ever-increasing strain of our national life the burden of these classes of cacogenic individuals is bound to become greater until the subject receives the consideration it deserves.

It has been a pleasure as well as an honor to be president of the Western Surgical Association for the year. This Association stands for the best there is in American surgery and, I believe, with the increase of membership it will become a more potent force for the advancement of surgery in the future even than it has been in the past.

THE DISTRIBUTION OF ADENOMYOMAS CONTAINING UTERINE MUCOSA*

THOMAS S. CULLEN, M.D.

BALTIMORE, MARYLAND

At a meeting of the Johns Hopkins Hospital Medical Society in March, 1895, I reported my first case of adenomyoma of the uterus, and ever since then I have been on the lookout for tumors of this character. From time to time the results of my labors have been recorded either in book form or in the literature.

I have been amazed at the widespread distribution of these tumors consisting of nonstriped muscle with islands of uterine mucosa scattered throughout them. In May, 1919, I read a short paper on the subject before the Medical Society of the State of New York, at Syracuse. This fragmentary article was published[1] a few months later.

In the present paper I shall not attempt to cover the literature on the subject, but shall confine my remarks to a description of the cases and of the pathological material that I have personally observed since reporting my previous cases.

Thus far we have found uterine mucosa in ten places in the body, as indicated in Figure 1, and we shall, therefore, discuss the subject under the following heads:

1. Adenomyoma of the body of the uterus.
2. Adenomyoma of the rectovaginal septum.

---

*Presented by invitation. From the Gynecologic Department of the Johns Hopkins University Medical Department and Hospital.

---

1. Cullen, T. S.: The Distribution of Adenomyomata Containing Uterine Mucosa, Am. J. Obst., vol. lxxx, p. 130, August, 1919.

3. Adenomyoma of the uterine horn, or of the Fallopian tube.
4. Adenomyoma of the round ligament.
5. Uterine mucosa in the ovary.
6. Adenomyoma of the utero-ovarian ligament.
7. Adenomyoma of the uterosacral ligament.
8. Adenomyoma of the sigmoid flexture.
9. Adenomyoma of the rectus muscle.
10. Adenomyoma of the umbilicus.

ADENOMYOMA OF THE BODY OF THE UTERUS

These tumors may be limited to the anterior or posterior walls of the uterus, or they may form a mantle or zone just outside the uterine mucosa. When the uterus is cut open, it is noted that the anterior or posterior wall, or both, are thickened. This increase is due to a coarsely striated condition of the muscle directly beneath the uterine mucosa. Where the uterine walls are especially thick, the diffuse myomatous growth may be several centimeters in thickness. Scattered throughout the diffuse growth, one often notes small cyst-like spaces filled with chocolate-colored contents, and not infrequently with a loupe one can detect here and there uterine mucosa penetrating into the diffuse growth.

Occasionally a cyst-like space, 1 cm. or more in diameter, may be found in the thickened uterine wall. Such a space will usually be lined with a velvety membrane about 1 mm. thick, and the cavity will be filled with the characteristic chocolate-colored contents,—old menstrual blood.

The line of demarcation between the normal outer uterine muscular wall and the diffuse myomatous growth just beneath the mucosa is invariably sharply defined, but the two are, nevertheless, so closely blended that it would be absolutely impossible to sepa-

rate them. Occasionally such a uterus will contain one or more small discrete myomas.

The histologic picture in a typical case is very characteristic: The uterine mucosa is often of normal thickness and looks perfectly natural, but, as we approach the underlying diffuse myomatous tissue, the mucosa is seen to penetrate it in all directions, sometimes as an individual gland; but often large areas of mucosa are seen extending into the depth. In favorable sections, one can follow a prolongation of the mucosa half way through the uterus. Where the diffuse myomatous growth ends, the outward extension of the glands also ends.

In the course of time, portions of the diffuse adenomyoma may project into the uterine cavity and be expelled through the cervix as submucous adenomyomas. In other instances a portion of the growth is forced to the outer or peritoneal surface, forming a subperitoneal adenomyoma. Such a myoma is prone to become cystic, and the cyst cavity or cavities will be filled with chocolate-colored contents.

Symptomatology.—It is not difficult to figure out to what symptoms an adenomyoma of the uterus will usually give rise. In the first place, the mucosa lining of the uterine cavity is perfectly normal; hence, as a rule, we shall have no intermenstrual discharge. With the advent of the menstrual period, however, not only will the patient lose her normal quota of blood, but this will be greatly increased by the flow coming from the large areas of mucosa which are scattered throughout the diffuse myomatous growth.

There will be, as a rule, a great deal of pain in the uterus, due primarily to the swelling of the mucosa, which is scattered throughout the uterine walls. The small and medium-sized cystic spaces filled with chocolate-colored fluid are due to the accumulation of old

menstrual blood in areas where the continuity of the mucosa with the uterine cavity has been interrupted. Such areas also undoubtedly add to the feeling of distention and discomfort at the period.

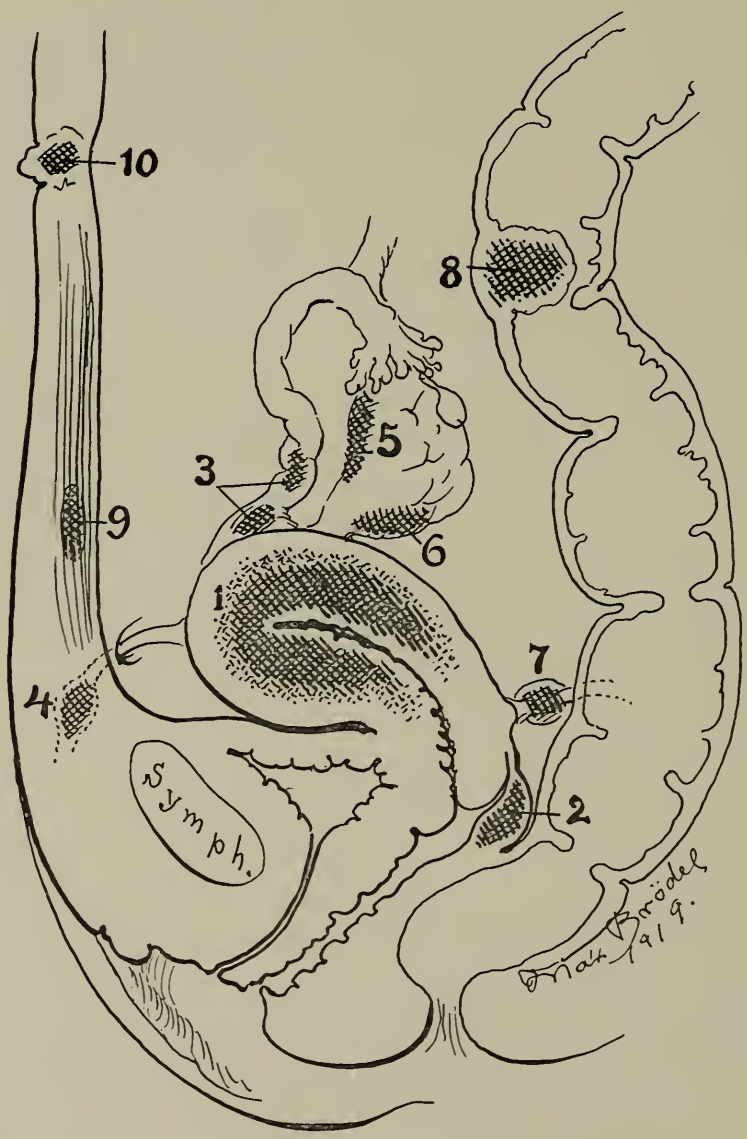

Fig. 1.—The various points at which we have found uterine mucosa: 1, in adenomyoma of the body of the uterus; 2, in adenomyoma of the rectovaginal septum; 3, in adenomyoma of the uterine horn or fallopian tube; 4, in adenomyoma of the round ligament; 5, in the hilum of the ovary usually unaccompanied by a myomatous growth; 6, in the utero-ovarian ligament; 7, in the uterosacral ligament; 8, in the sigmoid flexure; 9, in the rectus muscle; 10, in adenomyoma of the umbilicus.

On bimanual examination, we find a uterus that may be normal in size and perfectly smooth, or, on the other hand, it may be two or three times its normal size and slightly nodular. The introduction of a uterine sound usually reveals a normal cavity; and on curettage normal mucosa is invariably found. From the clinical findings one often can make a fairly accurate diagnosis of adenoma.

Generally speaking, removal of such a uterus is clearly indicated. Frequently this proves rather difficult on account of the tendency for such an organ to become densely adherent to surrounding structures.

I have discussed adenomyomas of the body of the uterus in such detail elsewhere[2] that a further consideration of the subject here would be superfluous.

Among the slides of adenomyoma of the uterus that will be thrown on the screen is one of especial interest. The right horn of a bicornate uterus is the seat of a widespread and diffuse adenomyoma; the right tube contains a pregnancy; the left tube is the seat of an adenomyoma; and the left ovary has been converted into a large retention cyst.

Case 1.—*A bicornate uterus with diffuse adenomyoma of the right horn. Pregnancy in the right fallopian tube. Adenomyoma and hydrosalpinx of the left tube. Large cyst of the left ovary.* (Figs. 2, 3, 4, 5, and 6.)

History (Church Home and Infirmary, No. 19173).—Mrs. H. T., aged 36, admitted to the Church Home and Infirmary, May 21, 1918, and referred to me by Dr. Marshall G. Smith, complained of an abdominal tumor, increasing pain in the right lower abdomen, and vaginal bleeding.

The menstrual periods as a rule had been regular, lasting two days, and she had had pain in the right lower abdomen.

2. Cullen, T. S.: Adenomyoma uteri diffusum benignum, Johns Hopkins Hospital Reports, vi, p. 133, 1896; Adenomyome des Uterus, Berlin, August Hirschwald, 1903; Adenomyoma of the Uterus, J. A. M. A., vol. 1, p. 107, January 11, 1908; Adenomyoma of the Uterus, Philadelphia: W. B. Saunders Company, 1908.

Latterly the periods had been irregular. The last normal period began probably Feb. 25, 1918. During March and April, she had had no menstrual period, but had suffered from the usual right-sided pain. She again had noted a flow on May 1, which had lasted one day. Two days had elapsed and then she had had a flow for seven days. The patient had been married twice, but had had no children and no miscarriages.

On examination under anesthesia, I made out what appeared to be a myomatous uterus, which extended well up toward the umbilicus.

Operation and Result.—Operation was performed May 28. When the abdomen was opened we found the tube on the right side, 4 cm. in diameter, and adherent in the pelvis. The uterus was bicornate, and the right side was three times the natural size. The surface of one of the nodules had a brownish appearance suggestive of an adenomyoma. On the left side was an ovarian cyst which filled the pelvis and was glued down by adhesions. We removed the structures from left to right, and then took out the appendix, which was tied down. The abdomen was closed without drainage. The patient made a good recovery and was discharged, June 18.

Examination of Specimen (Gyn. Path. No. 25515).—The specimen consists of the pelvic structures intact. (Figs. 2 and 3.) The uterus has been amputated through the cervix. This portion consists of a right and left uterine horn. The right horn is 9 cm. long and 5.5 cm. broad. This has two or three small bosses projecting from its surface, the largest being 1.5 cm. in diameter. The surface of the last and some of the others and also the adjoining peritoneum has a rusty appearance, instantly suggesting adenomyoma. On the anterior surface of the uterus are a few adhesions, on the posterior surface, many fanlike adhesions.

Intimately blended with the right enlarged uterine horn is a left uterine horn. The two horns are separated from one another by a cleft, about 1.5 cm. deep anteriorly, but very shallow posteriorly. The left horn to the point of amputation of the cervix is 7 cm. long and about 3 cm. broad.

On section, it is seen that both the right and left horns have separate cavities. These apparently unite near the external os.

The right horn, on section, presents the typical picture of adenomyoma. (Fig. 4.) The anterior wall of the right horn

reaches a thickness of more than 4.5 cm. There is no vestige of normal muscle persisting. The entire wall of the uterus, both anteriorly and posteriorly, shows the striated picture characteristic of adenomyoma; and scattered everywhere throughout both the anterior and posterior walls are chocolate-colored areas, varying from 1 mm. to 5 mm. in diameter, while small chocolate-colored cysts are also found in the myomatous nodules on the surface of the uterus.

The walls of the left uterine horn present the normal appearance.

The right tube near the uterus is about 8 mm. in diameter. As it passes outward and downward, it reaches a diameter of 4 cm. On section, it is found to be filled with what looks like organized blood. (Fig. 3.)

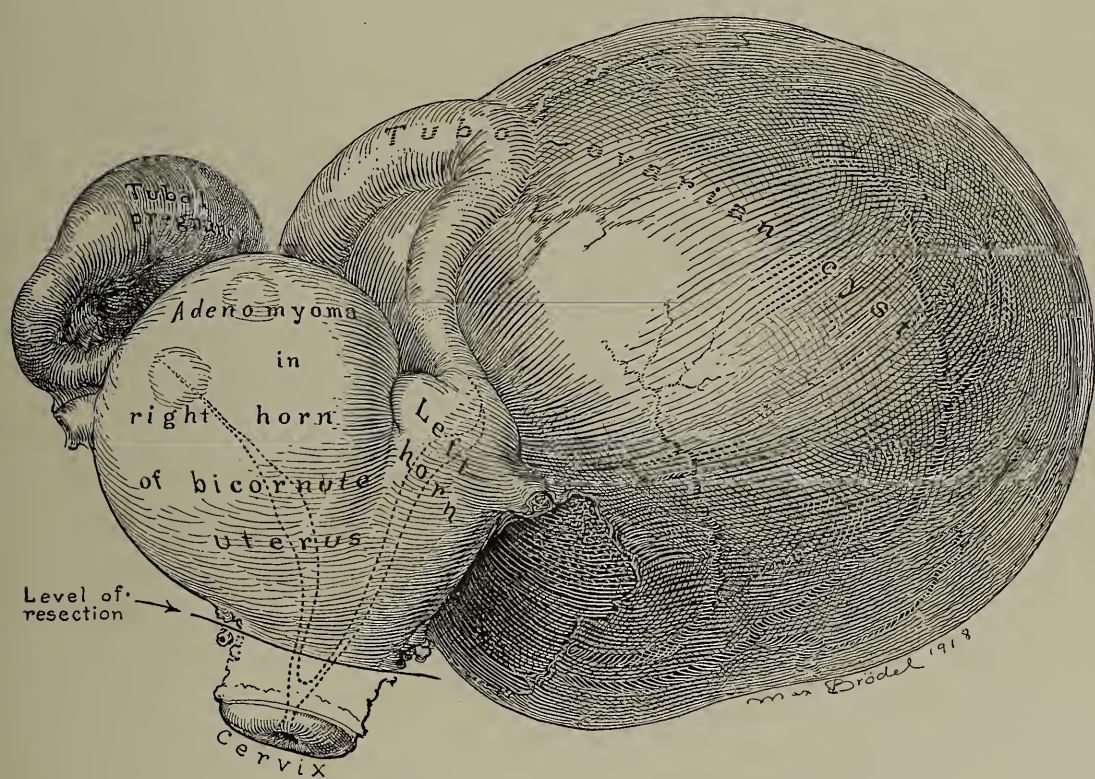

Fig. 2 (Case 1).—A bicornate uterus with adenomyoma of the right horn; right tubal pregnancy; enlarged left tube, the inner end showing adenomyoma (Fig. 6), the outer end hydrosalpinx; left ovarian cyst. For the finer details see Figure 5.

The left ovary has been transformed into a thin-walled multilocular cyst, 16 cm. in diameter. Its walls in places are as thin as parchment. The left tube at the uterine cornu

Fig. 3 (Case 1).—Bicornate uterus, right tubal pregnancy, enlarged left tube, left ovarian cyst. Viewed from the front. The uterus has been amputated through the cervix. The right cornu is much enlarged and projecting from its surface are two small fibroids. Beneath the anterior fibroid, the surface of the uterus is somewhat puckered. At this point the adenomyoma had extended to the peritoneal surface. A longi-

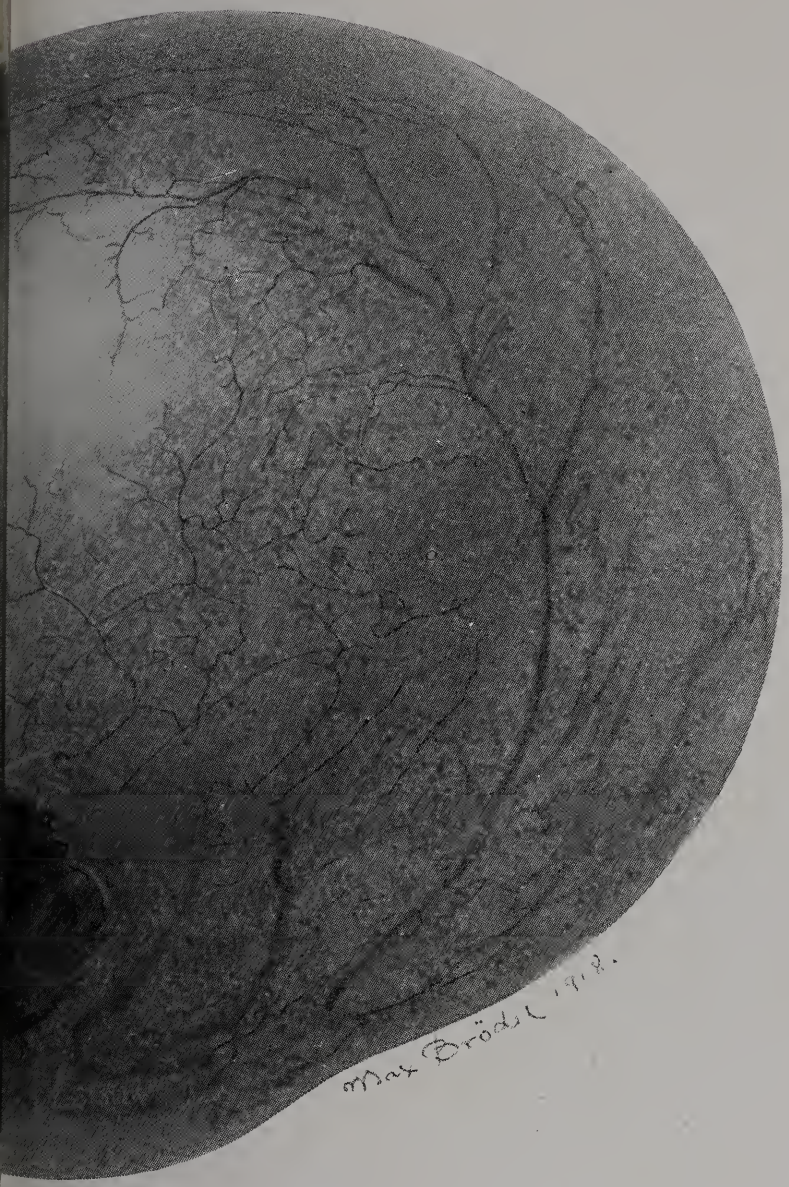

tudinal section of the right horn is shown in Figures 4 and 5. The left uterine horn is relatively small. The left tube in its inner portion is almost solid and consists of typical adenomyomatous tissue (Fig. 6). The outer end of the tube has been converted into a hydrosalpinx. The ovarian cyst seemed to be of the retention cyst variety.

Fig. 5 (Case 1).—Diffuse adenomyoma of the uterus. This is a longitudinal section through the right horn of the uterus shown in Figures 2 and 3. The longitudinal slit a noted in the lower and right portion of the picture, represents the uterine cavity. It can be traced upward and toward the left. The glands of the mucosa on the whole present the usual appearance. The anterior wall of the uterus is somewhat thickened and the posterior wall markedly so. The greater

part of the uterus presents a diffuse myomatous thickening, and where the muscle is arranged in whorls there is nearly always a gland or a colony of glands in its center. Many of the glands are dilated, forming round, oval, or irregular cyst cavities. The glands extend right up to the peritoneal surface. The picture is that of a most pronounced diffuse adenomyoma of the uterus.

BOSTON MEDICAL
MAR - 5 1930
LIBRARY

is fully 1 cm. in diameter. As it passes outward it comes to measure about 2.5 cm. in diameter, and the walls are very thin.

Histologic Examination.—Right Uterine Horn: Sections have been made embracing the entire thickness of the uterus.

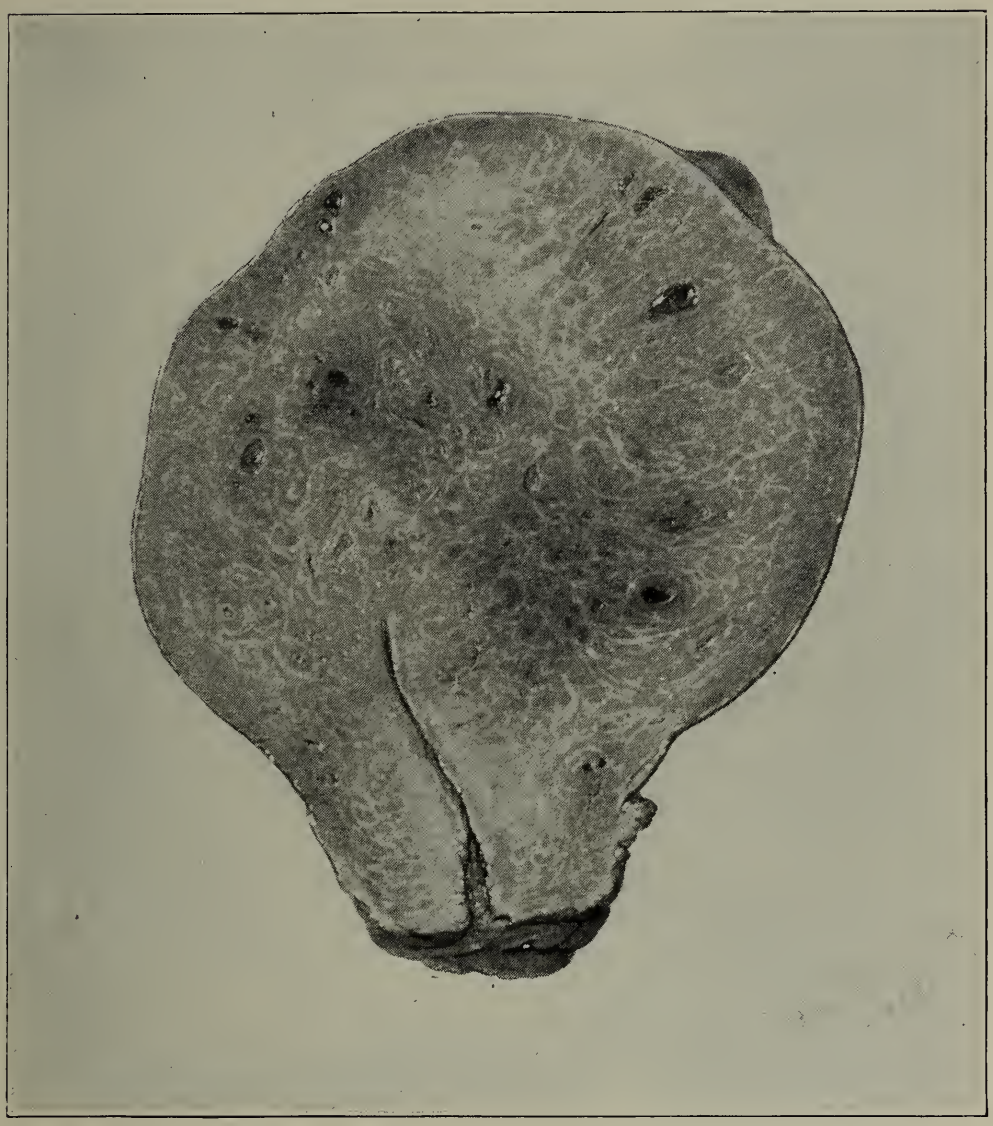

Fig. 4 (Case 1).—Adenomyoma of the right uterine horn. This is a longitudinal section through the right horn of the uterus shown in Figure 3. The entire body of the uterus shows a diffuse myomatous thickening, and scattered throughout the walls are small cyst-like spaces. These were in the main filed with chocolate-colored contents. The diffuse adenomyoma extends right up to the peritoneal surface at most points. At the fundus a discrete myomatous nodule can be seen. For the low power picture of the adenomyoma see Figure 5.

(Fig. 5.) The musculature is divided up into diffuse whorls, varying from 5 mm. to 3 cm. in diameter. Some of these are oval or circular; others are long and run parallel to the cavity of the uterus. Scattered everywhere throughout the walls of the uterus are dark areas containing minute cavities in their centers. Some of these cavities have a definite lining fully 1 mm. in thickness. In various places are oval or irregular cystlike spaces varying from 1 to 4 mm. in diameter. The majority of these are partially filled with blood. Even with the naked eye the diagnosis of diffuse adenomyoma occupying both the anterior and posterior uterine walls is perfectly evident.

With a higher power, islands of normal-appearing uterine mucosa are seen scattered everywhere throughout the diffusely thickened uterine walls, and the glands extend right up to the peritoneal surface. Even the isolated glands are accompanied by the characteristic stroma. In this case, the muscular tissue immediately around the islands of mucosa is unusually dense. Some of the blood at the menstrual period has undoubtedly escaped to the peritoneal surface, thus accounting for the rusty appearance noted on the surface of the uterus at operation.

This is the most widespread adenomyoma of the uterus that I have ever seen. The mucosa lining of the cavity of the uterus is perfectly normal. In a few places, however, it shows some tendency to extend into the underlying muscle.

Right Side: Sections from the blood clot in the right show quantities of placental villi. On some of these both Langhans' layer and syncytium are still visible, and one is also able to make out syncytial buds. At other points, the villi have lost all trace of epithelium. No cellular structure is visible in the stroma, and they are recognized as mere shadows. Their contours are still perfectly preserved. We are dealing with a right-sided tubal pregnancy, and, as we look back over the history, we find that the menstrual cycle strongly indicated extra-uterine pregnancy, but that the relatively large size of the pelvic masses completely overshadowed the enlargement of the tube.

Left Side: As was noted macroscopically, the left tube, even near the uterus, is unusually large. A section taken 2 cm. beyond the uterine horn is 1 cm. in diameter. Even with the low power it is noted that it is almost solid. (Fig. 6.) Its center is occupied by diffuse myomatous tissue, and

scattered everywhere throughout this are glands which resemble in every particular uterine glands. The majority of these lie in direct contact with the muscle, but here and there are several glands embedded in the characteristic stroma of the uterine mucosa. Some of the glands are dilated; and at one or two points we can see miniature uterine cavities. We have in this tube an adenomyoma of the uterine type, and I am totally at a loss to explain its mode of origin.

Sections from the large ovarian cyst show that the largest cavity is lined with epithelium that is almost flat. In the walls of this large cyst are a few gland-like spaces lined with cuboidal epithelium. The cyst walls are composed of laminated fibrous tissue.

In this case, we have a most unusual combination: a bicornate uterus, the right horn of which presents a most beautiful example of diffuse adenomyoma; a right tubal pregnancy; adenomyoma of the inner end of the left tube and a hydrosalpinx of its outer end; and, finally, a large multilocular cyst of the left ovary apparently of the retention cyst variety.

ADENOMYOMA OF THE RECTOVAGINAL SEPTUM

I wish to lay unusual emphasis on this group of cases. Many of you have undoubtedly seen them, but may not have recognized them. They are of unusual importance, and, if overlooked, will in time cause the patient to become a chronic invalid, and in some instances will undoubtedly lead to her death.

In 1913, Dr. D. S. D. Jessup of New York, knowing my interest in adenomyomas, sent me specimens of two tumors of this class. The mail on the following morning brought me the *Proceedings of the Royal Medical and Chirurgical Society of London,* containing Cuthbert Lockyer's splendid article on "Adeno-

3. Cullen, T. S.: Adenomyoma of the Rectovaginal Septum, Jour. A. M. A., vol. lxii, p. 835, March 14, 1914; Tr. South. Surg. & Gynec. A., vol. xxvi, p. 106, 1913; A Further Case of Adenomyoma of the Rectovaginal Septum, Surg., Gynec. & Obst., vol. xx, p. 260, March, 1915; Adenomyoma of the Rectovaginal Septum, Bull. Johns Hopkins Hosp., vol. xxviii, p. 343, November, 1917.

myoma of the Rectovaginal Septum." These two communications set me thinking, and I at once felt sure that two of my cases undoubtedly belonged in this category, although the histologic examination had given no inkling of such a condition. I had many more sections made and was finally rewarded by finding in each case the typical picture in other portions of the specimen. Since then I have been on the lookout for this condition and have had in all 19 cases.

Adenomyoma of the rectovaginal septum usually starts just behind the cervix; and, on bimanual examination, one can feel in this region a small, somewhat movable nodule scarcely more than a centimeter in diameter. The rectal mucosa at this time can be made to slide perfectly over the tumor.

As the growth increases in size, it spreads out laterally and at the same time becomes blended with the adjacent anterior rectal wall. Later it may invade the broad ligaments, encircling the ureters, or may envelop pelvic nerves. With the extension of the growth, it may push down into the posterior vaginal vault, forming definite and well-formed vaginal polypi, and, finally, it may break into the vagina.

The histological picture is typical of adenomyoma; even the vaginal polypi consist of non-striped muscle and uterine mucosa covered over by vaginal mucosa. Where the growth has definitely broken through into the vagina, we have normal-appearing uterine mucosa lining portions of the vaginal vault.

The clinical picture in adenomyoma of the rectovaginal septum is typical. In the early stages, the patient comes complaining of much pain just before and at the beginning of the period, especially at the time of defecation. On bimanual examination a small nodule is felt directly behind the cervix.

When the process is more advanced, the growth may measure 2 or 3 cm. across and may bulge slightly into the rectum, while in some cases there is already marked thickening of the anterior rectal wall for a

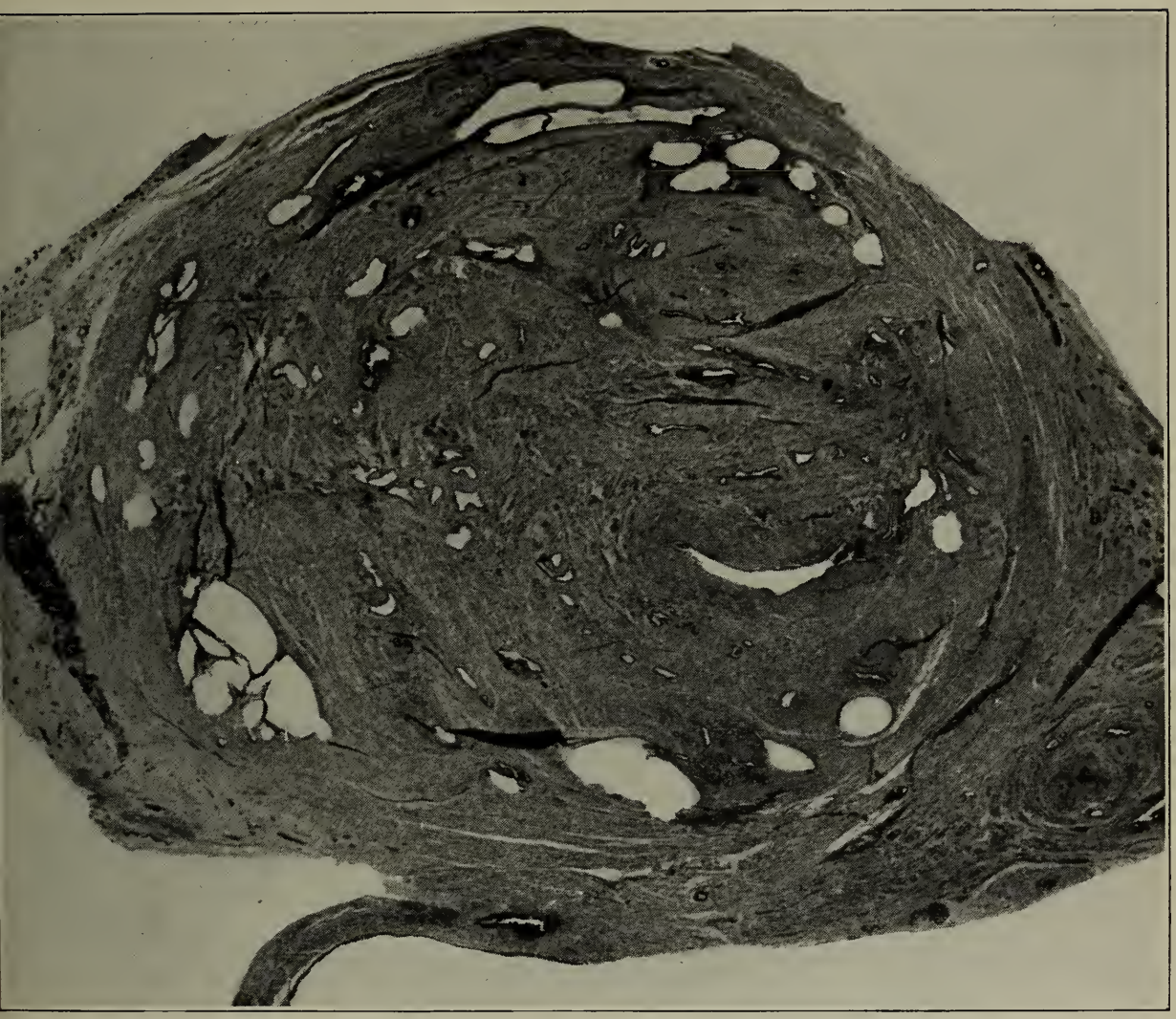

Fig. 6 (Case 1).—Adenomyoma of the left fallopian tube. This section was taken from the left tube seen in Figure 2, about 2 cm. distant from the uterine horn. Here the lumen of the tube is almost completely replaced by a diffuse myomatous growth with isolated glands or groups of glands scattered throughout it. The majority of the glands lie in direct contact with the muscle, a few are surrounded by the characteristic stroma of the uterine mucosa. Quite a number of the glands in the outlying portions have become dilated, forming small cysts. Hitherto, I have never seen the lumen of the tube occupied by an adenomyoma. The distal end of the tube formed a hydrosalpinx.

distance of several centimeters, and at the period there may be some rectal bleeding.

The growth sometimes encircles one or both ureters. At the period, the tumor tissue naturally swells up, and it may so constrict one or both ureters that there is a damming back on one or both kidneys with consequent pain in the renal region. In other cases, when the pelvic nerves are caught in the growth, excruciating pelvic pain may be experienced as soon as the tumor becomes congested at the time of menstruation.

Occasionally, as the growth progresses, the polypoid condition in the vaginal vault directly behind the cervix becomes very prominent, and in those cases in which the growth breaks through the vaginal mucosa there may be a menstrual flow from the vaginal vault even when a supravaginal hysterectomy has been performed some years before for uterine myomas. Finally, if nothing is done, the pelvis may become so choked with the growth that the patient dies from the extreme loss of blood coupled with partial intestinal obstruction.

In the early stages of the growth, this condition should be readily diagnosed. It cannot at this time be confused with any other pelvic lesion.

Treatment.—In the very early stages it may be possible to open up the vaginal vault just behind the cervix and remove the tumor. As a rule, however, it involves the posterior part of the cervix and cannot be shelled out.

When the nodule is 1 cm. or more in diameter and is still freely movable, the abdomen should be opened, the ureters isolated, and the uterus with a cuff of vaginal mucosa removed. If the vagina is cut completely across, one can then lift the uterus and vaginal cuff up and with more ease separate the adherent vaginal

cuff from the rectum. Sometimes it will be necessary to remove a wedge of the adherent anterior rectal wall with the uterus.

In cases in which the growth is widespread, a preliminary permanent colostomy is imperative. Later the pelvic structures can be removed *en bloc*. The removal of an extensive adenomyoma of the rectovaginal septum is infinitely more difficult than a hysterectomy for carcinoma of the cervix.

When a hysterectomy has been performed, and a small portion of the growth has been left on the rectum, radium seems to have held the rectal growth in check.

Since my last paper on adenomyoma of the rectovaginal septum appeared I have had ten more cases. The majority of these were early cases, and it is in the early cases that we naturally get the best results. History will undoubtedly repeat itself. Twenty-five years ago a subacute or chronic appendix was rarely removed; but appendix abscesses were drained. Now the appendix, in the vast majority of cases, is removed in time. In less than ten years, I feel sure that the surgeon will recognize and operate on these adenomyomas of the rectovaginal septum long before the wall of the rectum or the broad ligaments have been involved. Given a small nodule directly behind the cervix with little evidence of pelvic infection, the diagnosis is relatively certain. If the abdomen is then opened and the rectum is found lifted up and adherent to the posterior part of the cervix, the chances are, nine out of ten, that an adenomyoma of the rectovaginal septum exists. When early operation is performed in these cases, a certain number of our mild pelvic inflammatory cases that heretofore have gone from bad to worse will be cured. In the first week of November of this year, I saw three early cases of

adenomyoma of the rectovaginal septum—all of the patients being residents of Baltimore.

Recently I received a letter from a surgeon in South America in which he sketched his case from the early to the inoperable stages. The history is so graphically given that I believe we shall all profit by hearing it.

Valparaiso, Oct. 18, 1918.

Dear Sir:

Having found your articles on "Adenomyoma of the Recto-Vaginal Septum" of special interest, I take the liberty of sending you details of a case which was a puzzle to two other surgeons and myself until I luckily saw a synopsis of your article on this disease in *Surgery, Gynecology and Obstetrics.* The said article cleared up a mystery which I had been trying to solve for months, as it is impossible to find details of such cases in well-known text-books in English, German, or French. I think it will be of interest for you to know of such a case and hope you will have patience to read this letter, which I make as short as possible.

Mrs. H., aged 30, nullipara, of good health, married two years ago, consulted us (in British and American Hospital) at the beginning of December, 1917, complaining of lumbago. On making a vaginal examination, we asked her about the menses, which she said had been of late painful on the right side; the uterus was normal in position, size, consistency, etc. On the right side, the ovary was painful, but the puzzle was that she had a nodule especially hard and painful near the uterus which we took to be localized parametritis. We advised her to take douches, baths, ichthyol suppositories, etc., but seeing we got no result and that the pain was excruciating during the next period we decided to make a laparotomy.

On January 3, we performed a median laparotomy, finding a right ovary large and of a very dark unhealthy color. The nodule mentioned before was in the broad ligament right over the vagina, and it being impossible to remove it by abdomen, we resolved to leave it. The uterus was normal so we left it as it was, removing the ovary.

For three months, the patient experienced relief in symptoms, but on the fourth month menstruation was very painful and the pain radiated down to the thigh. We made again a vaginal examination and greatly to our disappointment found

Fig. 7 (Case 2).—Adenomyoma of the rectovaginal wall as seen on vaginal inspection. This water color of the uterus and accompanying vaginal cuff was made by Mr. Brödel shortly after operation. The cervix itself is practically normal. Projecting from its surface are a few small Nabothian follicles. Just posterior to the cervix is a slightly bluish black cystic area about 6 mm. in diameter. This bluish black appearance is, of course, due to the accumulation of old menstrual blood in a small cystic area in the adenomyoma. The uterus itself is little if any enlarged. For the appearance of the adenomyoma on section, see Figure 8, and for the microscopic picture, see Figure 9.

now two hard nodules, the same one as before much increased in size and a second one in the recto-vaginal septum which was easier to touch by rectal examination. The pain on palpation was terrible, so we had to give the patient a few drops of ether to examine carefully.

Seeing the condition of affairs, we had a consultation with a third surgeon and he was as much puzzled as we were. We decide to remove these little tumors by the vaginal route.

On May 28, we removed the two tumors by the vaginal route and our pathologist reported adenocarcinoma of an unusual type.

Looking for some information on this subject, I came across the article already mentioned and immediately sent for the more lengthy article in the *Johns Hopkins Bulletin,* which I received the day before yesterday and which has cleared up the condition of affairs to us and corrected the pathologist's diagnosis.

Unluckily our patient's condition is now too bad for us to think of doing a complete hysterectomy and we think she will not live very long. She has not had as yet any rectal hemorrhage, but she has had ovarian insufficiency, very irregular menstruation and her general state is very poor. Locally the condition of the pelvis is one firm mass as you say, like glue.

As I have not been able to procure your former articles, I beg your patience to answer one or two questions by post.

Where does this abnormal muscular and glandular tissue come from? From the uterus, or are these sometimes remains of fetal tissue or rather embryonic tissue which suddenly give rise to the growth?

Thanking you for the special service rendered to us through your articles and hoping you will let me know of any further researches in this line, believe me,

Yours truly,

John Wilson, M.D.

REPORT OF CASES HITHERTO UNPUBLISHED

Case 2 (Septum Case 10).—*Adenomyoma of the recto-vaginal septum recognized as an indurated area just posterior to the cervix, and by a small bluish black cyst shining through the vaginal mucosa.* (Figs. 7, 8, and 9.)

History (C. H. I. No. 18650).—Mrs. M. L., aged 41, was admitted to the Church Home and Infirmary, March 6, 1918, complaining of pain in the right lower abdomen associated

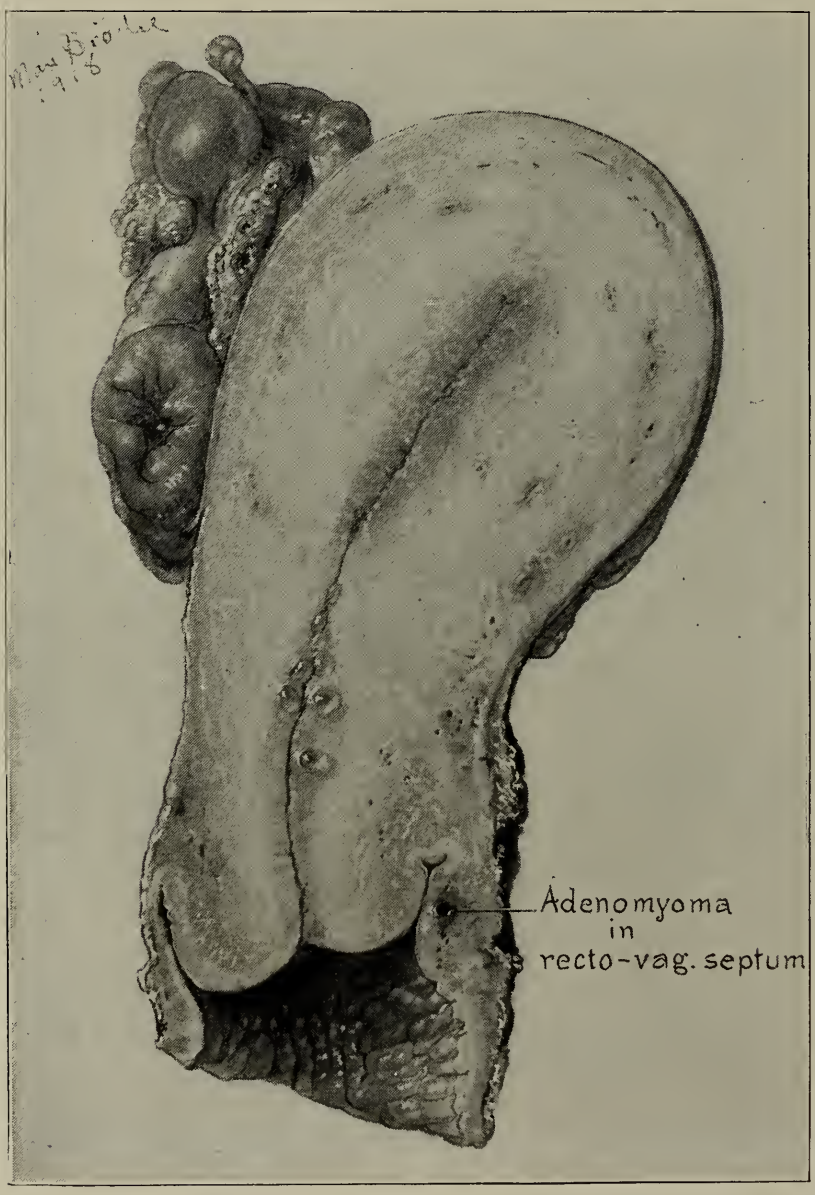

Fig. 8 (Case 2).—Adenomyoma of the rectovaginal septum. This is a longitudinal section of the uterus and vaginal cuff seen in Figure 7. Near the internal os are a few small cysts, otherwise the uterus presents the normal appearance. The anterior vaginal wall is normal. In the posterior vaginal wall near the cervix is an area of thickening with small dark areas scattered throughout it. On histologic examination (Fig. 9), it presents the typical picture of an adenomyoma.

with menstruation. Her general health had not been good. She had had pleurisy in 1916.

Her menses began at 13, were regular, painful, and lasted seven days. Since November, 1917, the periods had been about three weeks apart and exceedingly painful. The last period was shortly before her admission.

Fig. 9 (Case 2).—Adenomyoma of the rectovaginal septum. The majority of the glands are accompanied by the characteristic stroma of the mucosa. A few lie in direct contact with the muscle. For the appearance before operation, see Figure 7. A longitudinal section of the uterus and rectovaginal septum are shown in Figure 8.

Her present illness dated back one and a half years, when she had an acute attack of pain in the right lower abdomen reaching to the back. This was definitely associated with

menstruation. She had always gone to bed on the first day of the period and at times would faint and become giddy. For a year and a half, there had been a great deal of pain in the right lower abdomen at the time of the period. This pain would be sharp and radiating.

Examination.—When the patient was admitted to the hospital, she was in a very nervous and run down condition and her period was just over. Dr. Edmond H. Teeter, the resident who made a pelvic examination, told me before I had seen the patient that she had an adenomyoma of the recto-vaginal septum. This was perfectly definite, as just posterior to the cervix was an area of induration about 2 or 3 cm. across and probably 1.5 to 2 cm. thick. On rectal examination, the anterior rectal wall seemed splinted.

Operation and Result.—March 26, 1918, we made a median incision and found a corpus luteum cyst, 5 cm. in diameter, on the left side. The left tube and ovary were at once removed. The uterus was gradually dissected free as far as its vaginal attachment, and both ureters were carefully dissected out. The vagina was cut across all the way around, after which adhesions to the rectum were got at from the under side. It was possible to remove the growth without going into the lumen of the bowel at all. There was considerable oozing which was readily checked. Two drains were left in the pelvis, one in the lower angle of the incision. The patient made a perfectly satisfactory recovery and was discharged April 21, 1918.

At the time of operation a small bluish-black cyst was noted in the vagina directly behind the cervix. (Fig. 7.) This bluish-black appearance clearly indicated that we were dealing with an adenomyoma.

A longitudinal section of the uterus (Fig. 8) shows that the organ is only slightly altered. In the vaginal wall just behind the cervix, however, is an area of thickening, and this shows the characteristic areas of hemorrhage invariably associated with an adenomyoma.

Histologic Examination (Gyn. Path. No. 25514).—A section through the posterior vaginal wall at the point where the bluish-black cyst was noted shows that the vaginal mucosa is normal. The underlying tissue consists of non-striped muscle running in all directions. The cyst noted clinically is lined with low cuboidal epithelium. It is partially filled with old

blood, which presents a granular appearance, and in the blood are exfoliated epithelial cells which are swollen, have become spherical, and are filled with yellowish-brown pigment. Some of the epithelial cells lining the cyst present precisely the same picture. Projecting into the cyst cavity at one point is a tongue-like mass of normal uterine mucosa. The surface of this is covered with high cylindric epithelium. Beneath it is the characteristic stroma of the mucosa, and embedded in this stroma is a uterine gland, which is continuous far into the depth of the myomatous tissue. Scattered at various points throughout the diffuse myoma are islands of typical uterine mucosa (Fig. 9), some presenting the usual appearance, others showing old hemorrhage. The stroma cells of the mucosa in such areas are swollen and have taken up yellowish-brown pigment.

The mucosa lining the cervix and cavity of the uterus is normal.

In this case the adenomyoma is lower down than usual and appears to have begun in the posterior vaginal wall rather than in the posterior part of the cervix.

Case 3 (Septum Case 11).—*Adenomyoma of the recto-vaginal septum.* (Figs. 10 and 11.)

History (Gyn. No. 24601).—Mrs. C. S. F. L., aged 41, came to see me on Jan. 6, 1919. She looked perfectly well, but complained of pain in the lower part of the abdomen when she walked, and of excruciating pain in the midline above the symphysis at the time of the periods. She was also suffering a great deal of discomfort when the bowels moved.

The patient began to menstruate at 12, and was perfectly regular. The flow for the last three years had been very free, the periods persisting for six days. There was a great deal of abdominal pain on the third day. The last period was three weeks before her admission. She said she had a yellowish discharge between periods, which at times was most irritating. The patient had had four children; no instruments were used in the deliveries.

Examination.—I found the abdomen to be perfectly uniform. There was a small opening at the umbilicus 3 mm. in diameter. The outlet was moderately relaxed, the cervix was retroflexed and slightly lacerated, and a little nodular thickening about 1.5 cm. in diameter could be felt distinctly directly behind the cervix. The body of the uterus was not enlarged,

but was sagging backward. Rectal examination revealed the thickening posterior to the cervix very clearly.

Operation and Result.—The patient was admitted to the Johns Hopkins Hospital, Jan. 19, 1919, and operated on the following day. After tying off the round ligaments and opening up the broad ligaments, we tied the uterine vessels and isolated both ureters. We found a little puckering and thickening just posterior and a little to the right of the cervix near the right uterosacral ligament. We cut both uterosacral ligaments, turned down the bladder peritoneum, controlled the vaginal veins and then cut the vagina across all the way around. This enabled us to lift the uterus and rectum well up so that the nodule posterior to the cervix could be attacked from the under side. The growth was gradually loosened and separated from the rectum completely. We were able to accomplish this with the minimal amount of bleeding. The growth in the rectovaginal septum was about 1.5 cm. in diameter, and where the cervix had become adherent to the rectum the puckered area had developed. As we lifted the cervix away from the rectum, there was an escape of a little old blood. The patient stood the operation perfectly. We removed the appendix, put two drains into the pelvis, bringing them out through the vagina. The patient made an excellent recovery and was discharged, February 13, 1919.

On Saturday morning, June 29, 1919, five months after the operation, the patient was taken with intense discomfort, not exactly pain, in the epigastrium. This was not very severe, and in spite of it she went to Annapolis. On her return there was no improvement, but she had a fair night with the aid of an opiate. On Sunday morning Dr. Frank R. Smith was called, but could discover no alarming symptoms. There was no abdominal pain, and no pain on palpation of the abdomen. Magnesium citrate and bismuth were prescribed, and the bowels moved well. There was no blood passed in the stools. The patient vomited, but there was no unusual odor to the vomitus. Sunday evening a hypodermic was given, and the patient rested until 2 o'clock Monday morning. On awakening she complained of a more generalized pain and of a distress that was rhythmic in character. A little liquid nourishment was given, but this was immediately vomited. About half past six an enema was given, and the water returned clear and free from blood. Suddenly the patient fell over, gasped a few times, and died. The husband, who was a physician, noted the rapid heart-beat and abnormal coldness

of the arms some time before death. There was no clamminess or dyspnea noted at this time.

Necropsy Findings (J. H. H. Necropsy No. 5933).—This was performed by Dr. R. G. Mills. When the abdomen was opened the omentum was found firmly adherent to the under surface of the scar. At no point were there adhesions between the omentum and loops of intestine. As the intestines came into view, they appeared somewhat distended, a little dark in color. The lowermost loop was very dark and purplish, and the serosa of this dark-colored loop had to some extent lost its luster, and the subcutaneous tissue appeared infiltrated with blood. There was a small amount of free clear straw-colored fluid in the peritoneal cavity, and there were a number of small adhesions that connected the various loops of intestine. It was rather difficult to unravel the abodminal picture.

Dr. Mills' summing up is as follows: "Beginning at the point where the jejunum joins the ileum the bowel passes beneath the mass of adherent intestine, it passes under a fold of mesentery, it emerges below in the region of the cecum and is there united with another loop of bowel by a long, slender, strong band of adhesions. The ileum now passes into a long loop that circles around and is adherent once more to the long adhesion just mentioned. Just above this attachment the ileum is kinked into an S-shaped mass as the result of adhesions, which attach contiguous mesenteric surfaces. The bowel then passes on in another loop returning beneath this long, slender adhesion. At this point the lumen of the ileum is abruptly decreased in caliber, and beyond this point is much smaller. At the point of constriction, the serosa is very deeply injected and somewhat consolidated. The bowel is much firmer by reason of a hemorrhage at the point where obstruction occurs.

"Subsequent to operation it is probable that adhesions formed between contiguous loops of bowel. These have organized, producing distortion of the lumen of the bowel. The adhesions are probably responsibile for the long, slender adhesion above mentioned. Probably at the onset of the present acute attack a twist of the whole mass has occurred, producing in effect a volvulus. This has thrown unusual tension on the narrow band, which, producing a bridge-like form, has allowed a loop of ileum to pass beneath it."

Dr. Mills' findings disclose clearly the fact that intestinal adhesions had followed the abdominal operation and that

several months later there was a sudden volvulus of the adherent intestinal mass producing acute obstruction. It is remarkable to find a patient succumbing so quickly after the symptoms of partial obstruction developed. It will be noted, however, that the upper part of the small bowel was much involved. In such cases alarming symptoms usually develop relatively early.

Examination of Specimen (Gyn. Path. No. 24657).—The specimen consists of the uterus with the appendages intact. (Fig. 10.) The uterus is 9 cm. long, 5 cm. broad, and 5 cm.

Fig. 10 (Case 3).—Adenomyoma of the rectovaginal septum. Springing from the posterior surface of the uterus are a few small myomas. Growing from the posterior surface of the cervix just below the peritoneal attachment is a rough nodular growth. This on histologic examination showed typical adenomyoma (Fig. 11). As a rule, I never remove normal ovaries, but in some cases of adenomyoma of the rectovaginal septum it is necessary to leave a small portion of the growth attached to the rectum, and if the ovaries are saved there appears to be a tendency for the remaining portion of the adenomyoma to continue to grow.

in its anteroposterior diameter. Both the anterior and posterior surfaces are smooth. In the posterior wall of the uterus are two small fibroids. These project a little from the surface. Springing from the posterior wall of the cervix is a small, irregular growth about 1.5 by 1 cm. This is intimately blended with the cervical wall. In the depth it contains several small bluish-black areas.

There is a slight rolling out of the cervical mucosa. Situated in the anterior wall of the uterus is a myoma, 1.5 cm. in diameter. The uterine mucosa is normal.

The appendages on both sides are perfectly normal.

Histologic Examination.—The mucosa of the vaginal and cervical portions of the cervix is normal. The growth on the posterior surface of the cervix consists in large measure of fibrous tissue. It also contains a moderate amount of nonstriped muscle. Here and there in this diffuse growth are irregular deposits of uterine mucosa. (Fig. 11.) This in some places presents the normal picture, at other points it shows a mild grade of hypertrophy. Here and there the stroma of the mucosa shows hemorrhage.

We are dealing with a typical adenomyoma of the rectovaginal septum.

Fig. 11 (Case 3).—Adenomyoma of the rectovaginal septum. For the gross specimen see Figure 10. The tissue was very difficult to cut, hence the imperfect section. The glands of the growth are surrounded by the characteristic stroma.

Case 4 (Septum Case 12).—*Adenomyoma of the rectovaginal septum.* (Figs. 12 and 13.)

History (Gyn. No. 24585).—B. L., aged 25, admitted to the Johns Hopkins Hospital January 21, 1919, had had a dilatation and curettement at the Church Home and Infirmary following a miscarriage in June, 1910. On October 28, 1911, she was admitted to the Johns Hopkins Hospital, and a diagnosis of chronic pelvic inflammation was made. I performed a

dilatation and curettement, removed the right tube, the left tube and ovary, and appendix. Laboratory examination (Gyn. Path. No. 16635) revealed acute endometritis, and (Gyn. Path. No. 16625) a double pyosalpinx, a relatively normal appendix, a cystic left ovary. There was nothing in the clinical history at that time to indicate adenomyoma.

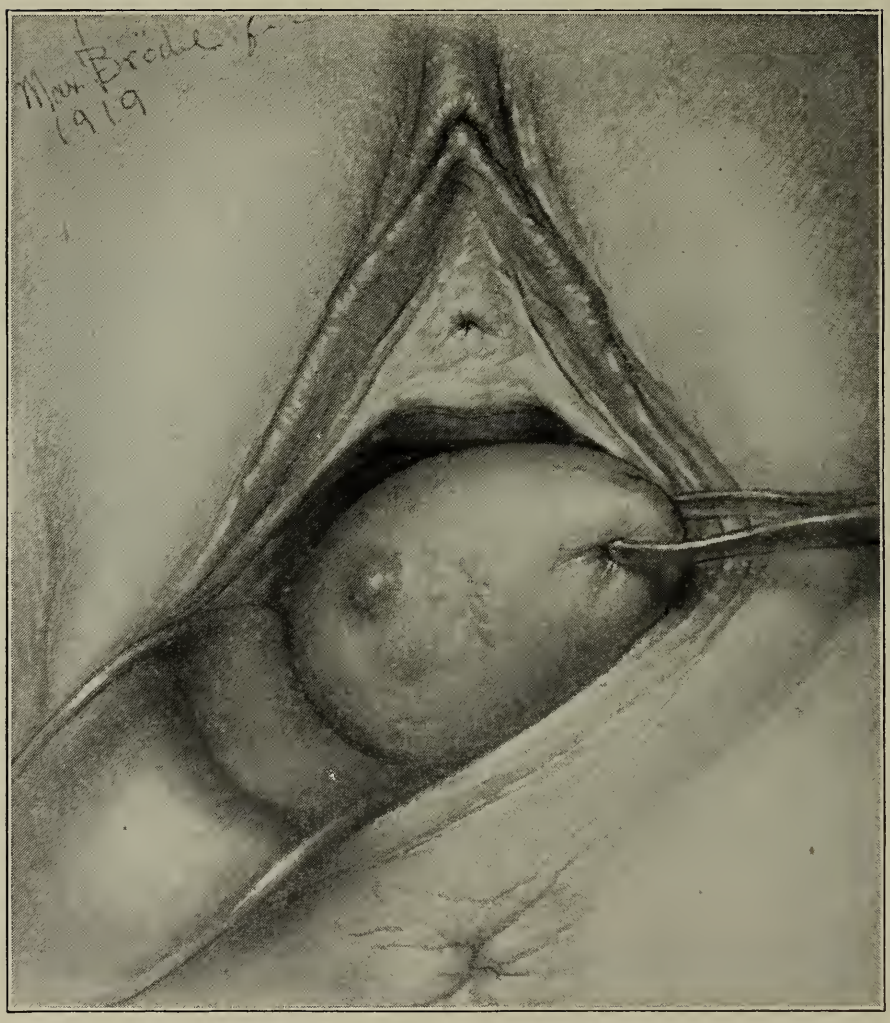

Fig. 12 (Case 4).—Adenomyoma low down in the recto-vaginal septum. The cervix has been drawn strongly to the left. On the posterior surface high up are two small cysts. One stands out prominently the other is rather hazy. Just below them, that is, toward the external os, the mucosa is definitely puckered. The low position of the growth enabled us to remove it with ease through the vagina. For the histologic picture see Figure 13.

The patient began to menstruate at 13, and was regular. Since the operation in 1911, the periods had occurred at intervals of from fifteen to twenty-one days and had lasted

from six to seven days. She formerly had little menstrual pain, but for the last year the discomfort had been growing worse. The pain usually started when the period commenced; it might last for a couple of days. It was dragging, dull-aching in character, and she also had pain in the back. Her last menstrual period occurred after her admission to the hospital. There had been no intermenstrual bleeding except on one occasion, a year before, after severe exertion. There was a slight leukorrhea just before and after the period. The patient has been married two years and a half. She has had no children, but she had had a miscarriage at six weeks in 1910. In 1913 a small lump was felt in the vaginal wall behind the cervix. At that time it was no larger than a pinhead. It had gradually increased in size, and she now had two small nodules. These were not tender.

Examination.—On vaginal examination the cervix was found to be normal in size. The body of the uterus was anteposed and in good position. There was no thickening on either side. In the vaginal vault, slightly to the right of the cervix, were two elastic spherical bodies each about 5 mm. in diameter. They lay close together and seemed really to form part of the same nodule. They were not fixed and occasioned no discomfort. When a speculum was introduced to the side of the cervix, one saw two small bluish cysts with slight puckering of the vaginal mucosa about the center of each of these small thickenings. (Fig. 12.)

Operation.—January 25, 1919, I drew the cervix well over to the left, and on the right side of the vaginal vault lateral to the cervix there appeared two small areas darkish blue in color. These were incorporated in two small tumors lying deep beneath the vaginal mucous membrane. I made an elliptical incision including these two small tumors. They were removed without any difficulty, and the vaginal incision closed. The patient was discharged February 5, in good condition.

Examination of Specimen (Gyn. Path. No. 24652).—The larger cyst reaches a diameter of 6 by 4 mm. Both cysts are surrounded by a definite layer of muscle arranged circularly. The cysts are lined by one layer of cylindric epithelium which is somewhat folded. In one of the cysts are definite projections. (Fig. 13.) Both cysts contained blood, and in the underlying stroma and muscle are quantities of yellowish-brown pigment.

This was undoubtedly another adenomyoma. It was situated much lower down than usual, and we were accordingly able to remove it with the minimal amount of difficulty.

Case 5 (Septum Case 13).—*Adenomyoma of the rectovaginal septum.* (Figs. 14 and 15.)

History (Gyn. No. 24864).—A. A., aged 26, was admitted to the Johns Hopkins Hospital May 2, 1919, complaining of bear-

Fig. 13 (Case 4).—A small cyst in an adenomyoma of the rectovaginal septum. This is one of the small cysts noted in Figure 12. It is lined with one layer of cylindric epithelium of the body type, and extending into the cavity are several small projections. The cyst contained blood and some exfoliated epithelium. At some points, the cyst epithelium lay directly on the underlying muscle, in other places it was separated from the muscle by a definite stroma.

ing down pains in the pelvis and of backache. The patient's mother died of some form of cancer. Menstruation began at

13, was regular, and lasted from three to four days. She had pain for the first day, cramp-like in character. There was no intermenstrual bleeding. The patient has been married seven years. She has had one child. About a year ago she began to have a dragging sensation in the lower abdomen; this was no worse at the periods. The symptoms had increased in severity.

Examination.—The patient was a well developed woman. The outlet was relaxed; the cervix was lacerated. Behind the cervix was a nodule about 1.5 cm. in diameter. This was not very tender. The uterus itself was normal in size and in

Fig. 14 (Case 5).—Adenomyoma of the rectovaginal septum. Attached to the posterior surface of the uterus are a few adhesions. Springing from the posterior surface of the cervix below the peritoneal attachment is a well defined nodule, 2 by 1 cm. For the histologic picture of this nodule see Figure 15.

good position. On the left side there was some thickening, probably due to a prolapsed ovary. The patient had no hemorrhoids.

Dr. H. N. Shaw, the resident gynecologist, immediately thought of adenomyoma of the rectovaginal septum.

Operation.—May 3, under anethesia, I confirmed Dr. Shaw's impressions. On examination I found that the rectum was attached to the nodule posterior to the cervix. The rectal wall did not seem to be invaded, but was somewhat puckered at this point.

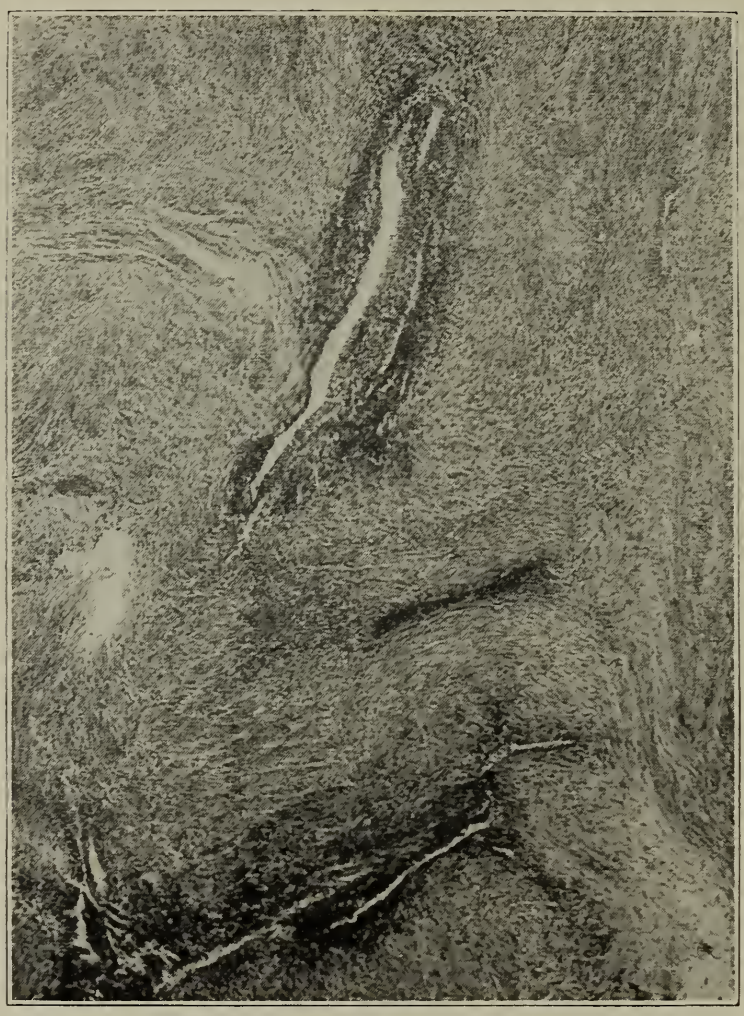

Fig. 15 (Case 5).—Adenomyoma of the rectovaginal septum. This section is from the adenomyoma springing from the posterior part of the cervix in Figure 14. The muscular tissue is very dense. Scattered throughout it are isolated glands surrounded by the characteristic stroma.

When the abdomen was opened, a little puckered area could be seen just posterior to the cervix. The rectum here was lifted up and had become adherent to the puckered area. The picture was that of a typical early adenomyoma of the rectovaginal septum. The operation was begun by tying and

cutting the round ligaments on each side. The right ovarian vessels were clamped and cut. We decided to leave the left ovary. After freeing the broad ligaments on each side, they were spread widely apart, and the inner flap was split down to the region of the ureter. Both ureters were now dissected out, and the uterine vessels ligated. The dissection was now carried down far in the vaginal vault, and the vaginal veins were clamped and tied. After sufficient exposure had been obtained in this manner, the uterosacral ligaments were cut and the uterus drawn well out. The vagina was then cut across well below the nodule in the rectovaginal septum, and the thickened vaginal wall was gradually dissected free from the rectum. The bowel was in no way damaged. The appendix was removed, a small drain was left in the pelvis and brought out through the vagina, and the abdominal incision closed. The patient left the table in excellent condition. She was discharged May 25, 1919.

Examination of Specimen (Gyn. Path. No. 24989).—The specimen consists of the uterus, right tube and ovary, and appendix. The uterus is 8 cm. long, 6 cm. broad and 4.5 cm. in its anteroposterior diameter. The anterior surface of the uterus is smooth; the posterior surface is covered by a few shaggy adhesions, but is for the most part smooth. Projecting from the posterior surface of the cervix near the internal os is a nodule 2 by 1 cm. (Fig. 14.) This is irregular. It blends into the cervical tissue, but the line of demarcation is sharply defined. Its superficial portion invades the surrounding adipose tissue. It contains a few minute brownish areas. The vaginal portion of the cervix shows some laceration. The uterine mucosa reaches 6 mm. in thickness.

The right tube is normal. The right ovary contains an unruptured corpus luteum, and the peritoneum over this area has been adherent.

Histological Examination.—The mucosa of the vaginal portion of the cervix is normal. The cervical glands present the usual appearance. The nodule projecting from the posterior surface of the cervix consists of non-striped muscle and fibrous tissue. Scattered throughout it are small irregular islands of uterine mucosa. (Fig. 15.) Near the point where the growth was attached to the rectum is a rather large area of mucous membrane showing the characteristic gland hypertrophy now and then noted in the mucosa of the body of the uterus.

This is a typical case of adenomyoma of the rectovaginal septum.

Case 6 (Septum Case 14).—*Extensive adenomyoma of the rectovaginal septum; extension to the surface of the right Fallopian tube; uterine mucosa on the surface of the right ovary.* (Figs. 16, 17, 18, 19, 20, and 21.)

History (Gyn. No. 24887).—L. G., aged 40, white, was admitted to the Johns Hopkins Hospital May 9, 1919, complaining of dysmenorrhea and menorrhagia.

The patient had been in the hospital in 1912 (Gyn. No. 18377). At that time I performed a partial resection of both ovaries, released pelvic adhesions, and removed the appendix.

She was again admitted to the hospital in 1915 (Gyn. No. 20850). At that time Dr. Neal, the resident, incised and cauterized a Bartholin's gland abscess.

The patient's menses were fairly regular and lasted seven days. There was a very profuse flow. The last period was April 20. There was no intermenstrual bleeding. The patient had always had very severe dysmenorrhea. This had become more distressing during the last year. The most acute pain was experienced a day before the period started. During the twenty-four hours before the onset of the flow the patient was nauseated, vomited, and had extreme abdominal pain and pain in the back. These symptoms were getting worse.

The patient had been married fifteen years. She had one child, fourteen years ago, and no miscarriages.

Examination.—The patient was a rather delicate, undernourished, middle-aged woman. Her hemoglobin was 75 per cent; white blood cells, 11,000. The lower abdomen was prominent, due to a hard mass extending up from the pelvis and reaching to within about 4 cm. of the umbilicus. The outlet was moderately relaxed, and the cervix was high up in the vaginal vault. It was continuous with the abdominal tumor.

Operation.—May 12, 1919, on examination under ether, the pelvis was found to contain a large mass about the size of a five-months' pregnancy. On the surface of this and also posteriorly a hard nodule could be felt. In the rectovaginal septum on the left side was a dense indurated mass.

When the abdomen was opened, the uterus was found to be quite symmetrical and enlarged from the fundus to the cervix.

The right tube was filled with fluid and was adherent to the uterus. The intestines were adherent to the posterior surface of the uterus. The cul-de-sac was indurated; and the rectum

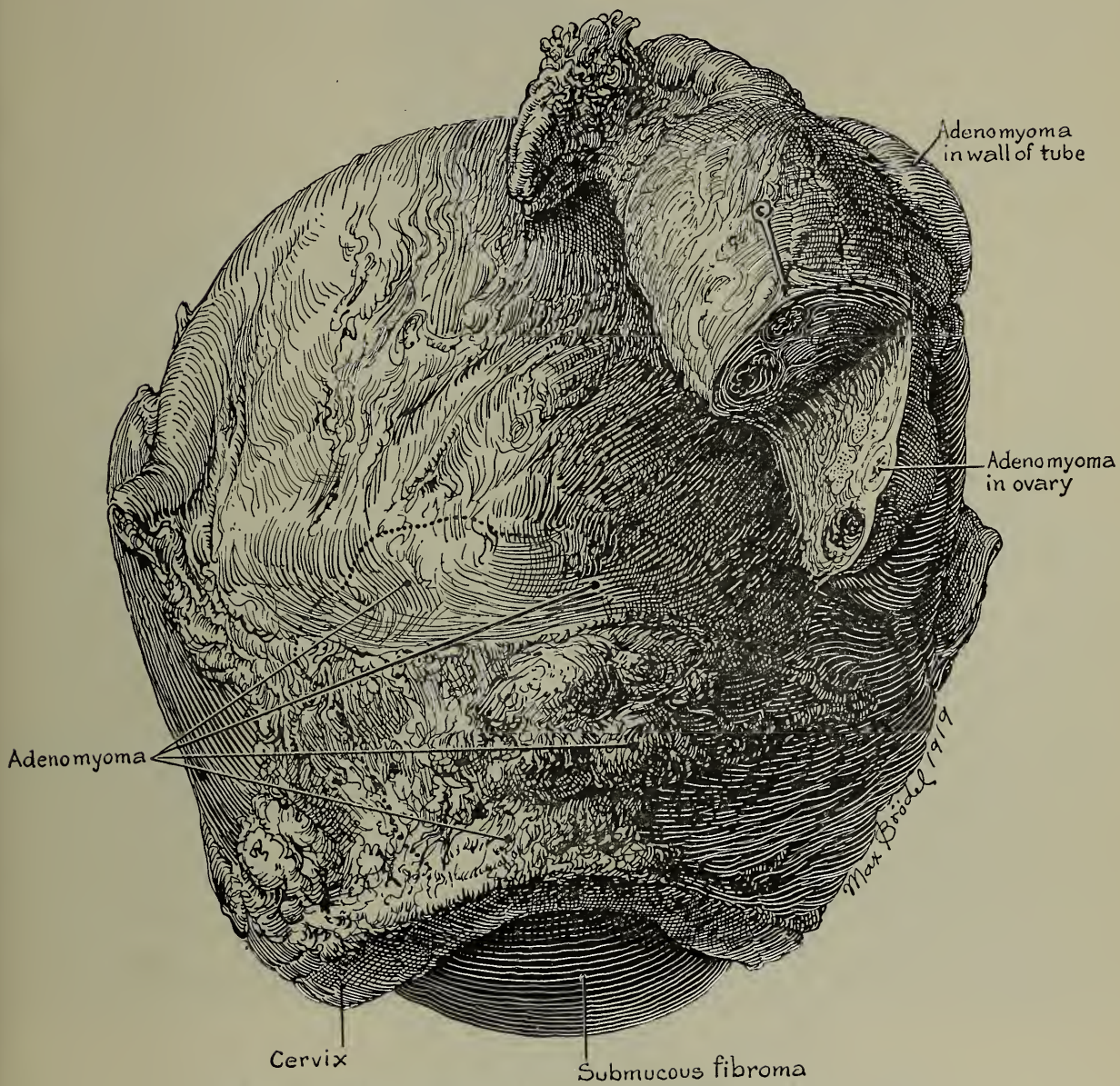

Fig. 16 (Case 6).—Widespread adenomyoma of the rectovaginal septum; extension to the surface of the right ovary and tube. The supravaginally amputated uterus was 13 cm. long and 11 cm. broad. Its anterior surface was smooth, its posterior surface covered by adhesions. Occupying the posterior surface of the cervix and extending well up on the body of the uterus was a diffuse and hard growth. This consisted of typical adenomyoma (Figs. 17, 18 and 19). The right tube and ovary formed one large solid mass, and on the surface of both tube and ovary was typical uterine mucosa (Figs. 20 and 21). This is the most widespread distribution of an adenomyoma of the rectovaginal septum that I have ever seen.

Fig. 17 (Case 6).—Adenomyoma of the rectovaginal septum. This section is from the cervix of the uterus seen in Figure 16. To the left is normal cervical mucosa, to the right we see islands of uterine mucosa from the rectovaginal septum. The area a has been magnified and is shown in Figure 18.

was adherent well up on the posterior surface of the uterus. it was also firmly attached to the left broad ligament. The left tube was partly obscured by adhesions, and the left ovary was buried in adhesions. As a matter of fact, the left tube and ovary and the sigmoid flexure formed one solid mass.

Fig. 18 (Case 6).—This picture is an enlargement of the area a in Figure 17. One sees numerous uterine glands surrounded by the typical stroma of the mucosa. A few of the glands are dilated. In the upper part of the picture is an area of characteristic stroma covered over by one layer of cylindric epithelium.

The operation was begun by separating some loops of bowel from the pelvis, then the left round ligament was cut; the left tube and ovary were clamped off at the uterus and left temporarily in place. The bladder was pushed down and the right round ligament was cut; the right ovarian vessels were

then clamped and cut. After this procedure it was found possible to lift the uterus well up, and we then realized that without doubt we were also dealing with an adenomyoma of the rectovaginal septum. Dissection was gradually carried down on the posterior surface of the cervix as far as possible, and a supravaginal amputation performed. Better exposure could now be obtained, and the stump of the cervix was dissected free. The rectum was densely adherent to the hard mass occupying the lower and posterior part of the uterus, the posterior part of the cervix, and the adjacent rectovaginal septum. During manipulation a little dark blood escaped from the rectovaginal septum. To have removed entirely the diffuse growth of the rectovaginal septum would have been an impossibility. As it was, it was one of the most difficult hysterectomies I ever attempted. The ureters were not exposed on either side, but they could be seen through the pelvic peritoneum; they were well removed from the point where the uterine vessels were controlled.

The cut edge of the vaginal mucosa was then controlled all the way round, and then the broad ligaments were obliterated as far as possible. Nothwithstanding our attempts to leave a smooth surface, a small amount of raw area still remained in the cul-de-sac. Two cigaret drains were placed in the pelvis and brought out through the vagina. The abdomen was then closed in the usual manner. The patient lost a considerable amount of blood during the operation but left the table in good condition.

She was discharged June 1, 1919. There was no induration of the pelvis, and she felt well.

We shall watch the subsequent history in this case with a good deal of interest, as some of the adenomyomatous growth was of necessity left adherent to the rectum.

Examination of Specimen (Gyn. Path. No. 25003).—The specimen consists of the enlarged uterus with its detached cervix and of the appendages from both sides.

The supravaginally amputated uterus is 13 cm. long and 11 cm. in its anteroposerior diameter. The anterior surface of the uterus is smooth; the posterior surface at the fundus is covered by shaggy adhesions. The greater part of the posterior surface over an area approximately 7 cm. from above downward and 12 cm. from side to side presents a rough and ragged appearance. This is the area that will prove to be of

Fig. 19 (Case 6).—Adenomyoma of the rectovaginal septum. This is a section from the adenomyoma of the rectovaginal septum shown in Figure 16. The uterine mucosa is unusually abundant, forming fully half of the section. Even with the very low power it will be noted that many of the glands show hypertrophy.

the greatest interest, the appearance being due to a widespread adenomyoma occupying the posterior surface of the uterus and cervix. (Fig. 16.)

The increase in size of the uterus is in large measure due to the presence of a submucous myoma 10 cm. in length. This projects into the uterine cavity from the posterior wall.

Fig. 20 (Case 6).—Extension of an adenomyoma of the rectovaginal septum to the surface of the adherent fallopian tube. The gross appearance of the tube is shown in Figure 16. The folds of the tube look relatively normal. The solid black areas are blood vessels. On the surface of the tube at a is an area of typical uterine mucosa. It really looks as if the widespread adenomyoma of the rectovaginal septum has literally flowed over on the surface of the tube.

The anterior wall of the uterus varies from 1.5 to 2 cm. in thickness, and the mucosa from 1 to 7 mm. The mucous membrane over the surface of the submucous myoma is very thin, in most places being not over 0.5 mm. thick.

Fig. 21 (Case 6).—Uterine mucosa on the surface of the ovary in a case of adenomyoma of the rectovaginal septum. For the gross appearance of the ovary see Figure 16. The miniature uterine cavity on the surface of the right ovary is represented by a. The lining mucosa resembles in every particular that of the body of the uterus. Some of the glands show hypertrophy. The mucosa of the adenomyoma of the rectovaginal septum seems to have overflowed to the surface of the adherent ovary. The same condition was noted on the surface of the corresponding tube (Fig. 20).

The widespread raw area which occupies the greater part of the posterior surface of the uterus has a very ragged appearance. As noted from the description of the operation, this area had literally to be cut away from the rectum. On incising the raw area, one notes a coarse striation of the tissue, and at various points are small brownish specks. Histologic examination will show that this is adenomyomatous tissue.

The lower portion of the cervix was removed after the fundus had been taken away. The vaginal portion of the cervix shows some eversions of the cervical mucosa.

Right Side: The tube and ovary form a conglomerate mass, which has been densely adherent to the side of the uterus, as well as to the surrounding structures. Nothwithstanding this the fimbriated end of the tube is patent and appears relatively normal. The tubo-ovarian mass measures 10 cm. in length and at one point reaches a diameter of 5 cm. It is impossible to trace the continuity of the tube in its middle portion where it is intimately attached to the ovary and is covered by adhesions. The ovary contains at least two small corpora lutea cysts.

Left Side: The appendages form an inseparable mass, 6 cm. long and about 4 cm. in diameter. They are embedded in adhesions, but the fimbriated end of the tube is patent.

Histologic Examination.—Sections from the cervical mucosa show that it is normal. (Fig. 17.) Sections from various portions of the large raw area on the posterior surface of the body of the uterus and cervix present an amazing picture. (Figs. 17, 18, and 19.) The tissue consists in large measure of non-striped muscle, and scattered everywhere throughout this are tremendous rivers of perfectly normal looking uterine mucosa. So abundant is the mucosa in many places that it forms at least one-half or two-thirds of the section. This mucous membrane in many places shows a tendency toward hypertrophy. (Fig. 19.) Its stroma shows a considerable amount of hemorrhage, and here and there a gland is dilated reaching a millimeter or more in diameter. This is the most widespread distribution of an adenomyoma on the posterior surface of the uterus that I have ever seen.

The myoma occupying the posterior wall of the uterus and projecting into the uterine cavity shows much hyaline degeneration.

Sections from the right uterine cornu show that the tube at this point is perfectly normal, but sections further out, although showing a normal mucosa, reveal typical areas of uterine mucosa on the surface of the tube. (Fig. 20.) One gathers the impression that the uterine mucosa from the diffuse adenomyoma on the posterior surface of the cervix and uterus has overflowed on the adherent tube.

On the surface of and intimately attached to the ovary is a miniature uterine cavity. (Fig. 21.) The glands of its mucosa show a moderate hypertrophy. Other sections from the same ovary show a diffuse adenomyoma intimately blended with the ovarian tissue, so intimately attached that no line of demarcation can be detected. It must be remembered, however, that this ovary was firmly glued to and continuous with the diffuse adenomyoma occupying the posterior surface of the uterus.

Case 7 (Septum Case No. 15).—*Adenomyoma of the recto-vaginal septum.* (Figs. 22 and 23.)

History (Gyn. No. 24984).—C. B., aged 36, white, entered the Johns Hopkins Hospital June 12, 1919, complaining of pain in the left lower abdomen at the menstrual period. She also had severe headaches. The menses began at 13, were regular until six months ago, when they appeared three times in a month; the last period was June 7, the one previous May 28. During the last two months the pain had been severe in the left lower abdomen. She gave no history of rectal bleeding at the menstrual period.

Examination.—On pelvic examination, the cervix was found low in the vagina. The body of the uterus had dropped back, was irregular and nodular in outline. In the left side of the pelvis was a movable, cystic, rather tense mass about 8 cm. in diameter.

Operation.—On examination under anesthesia in addition to the above findings, a small cystic mass could be felt on the right. June 14 the abdomen was opened, and two cysts with rather opaque looking walls were seen in the pelvis. One lay up in under the left broad ligament, the other occupied the floor of the cul-de-sac; both contained dark chocolate-colored fluid, in other words, there was a corpus-luteum cyst on each side. The cysts were resected and a small piece of ovary was left on both sides. After removal of the cyst, there still remained a small adherent mass between the cervix

and rectum, and there was no doubt that an adenomyoma of the rectovaginal septum existed. The ureters were isolated, the uterus freed on all sides, and the vagina cut across. A small amount of adenomyomatous tissue was left adherent to the rectum. Near the completion of the operation, it was found that the left tube and ovary had a very poor blood supply, and for this reason they were removed. The appendix, which was very long, was also removed. A drain was laid in the pelvis and brought out through the vagina. The abdomen was then closed. A considerable amount of blood was lost during the operation. The patient left the table in fair condition. She was discharged July 5, 1919, in good condition.

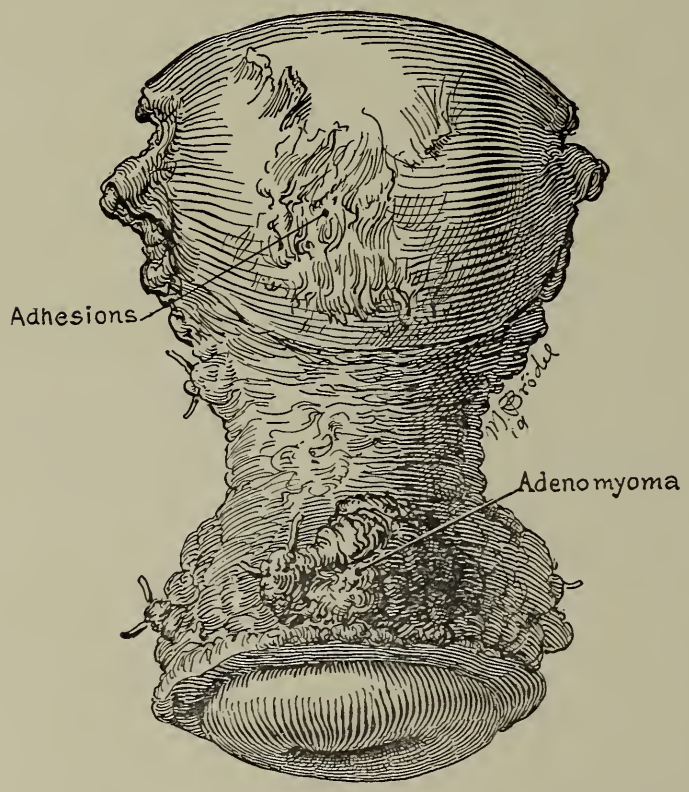

Fig. 22 (Case 7).—Adenomyoma of the rectovaginal septum. The posterior surface of the fundus is partially covered by adhesions. Springing from the posterior part of the cervix near the vaginal attachment is a well defined adenomyoma 2.5 by 2 cm. For the histologic picture, see Fig. 23.

Examination of Specimen (Gyn. Path. No. 25120).—The specimen consists of the uterus and of the much mutilated appendages, together with the appendix.

The uterus is 11 cm. long, 6 cm. broad, and 4 cm. in its anteroposterior diameter. (Fig. 22.) The anterior surface is smooth. The posterior surface almost to the top of the

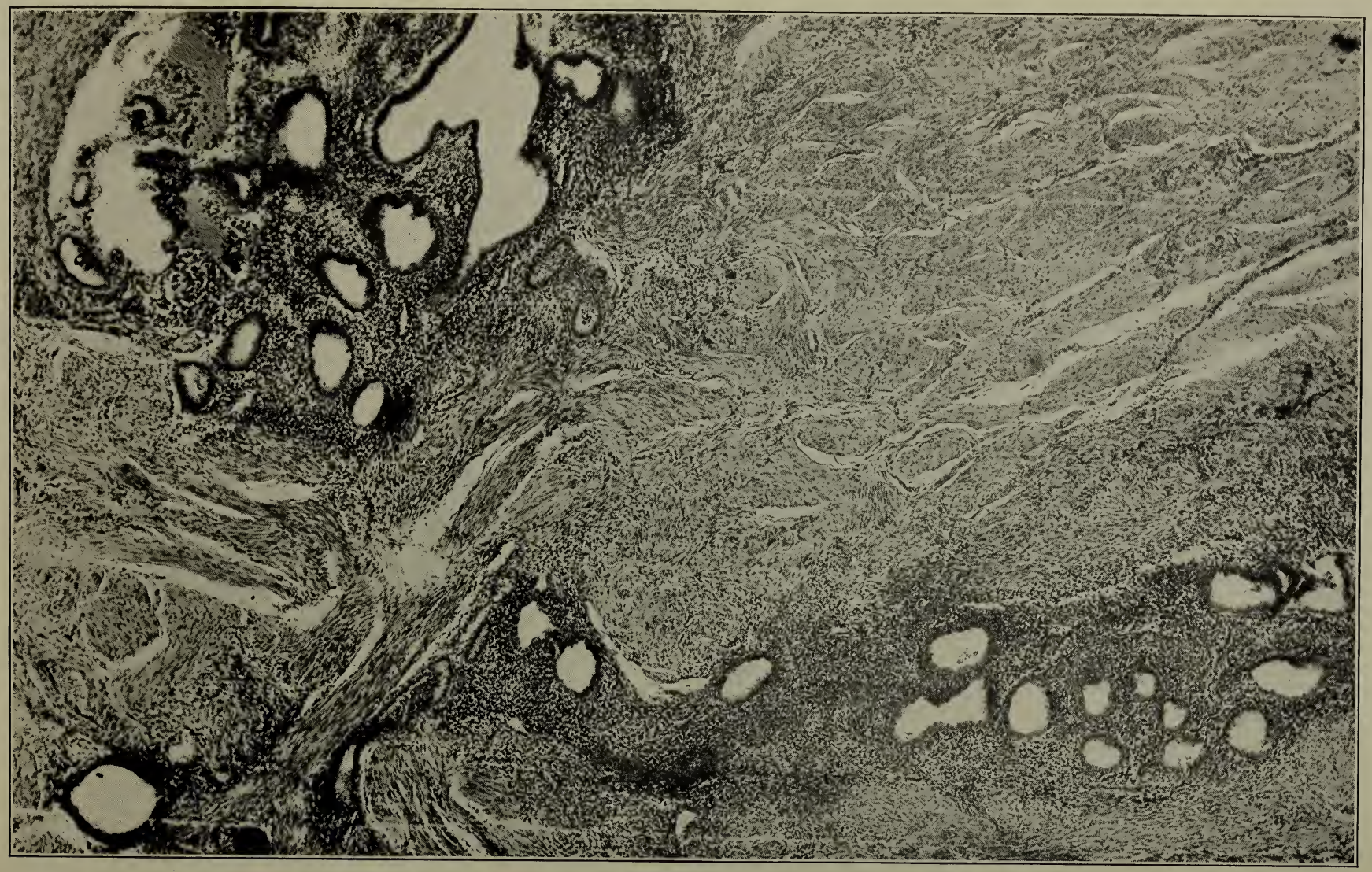

Fig. 23 (Case 7).—Adenomyoma of the rectovaginal septum. For the gross specimen, see Figure 22. The matrix of the growth is made up of nonstriped muscle and fibrous tissue. Occupying fully one-third of the field are areas of typical uterine mucosa. Some of the glands are dilated. Here and there a gland lies in direct contact with the muscle.

fundus is covered by adhesions. Springing from the posterior surface of the cervix is a raised, hard area 2.5 by 2 cm. The tissue here is exceptionally hard and on section it presents a brownish-black appearance. It extends into the posterior cervical wall nearly 1 cm. and spreads out like the broad roots of a tree. It also encroaches slightly on the posterior vaginal wall. The mucosa of the vaginal portion of the cervix is somewhat everted. The mucous membrane lining the cervical canal and the cavity of the uterus presents the usual appearance.

Fig. 24 (Case 8).—Multiple uterine myomas; adenomyoma of the rectovaginal septum. The specimen is viewed from behind. Scattered over the posterior surface of the uterus are several small myomas, and projecting into the left broad ligament is a myoma 3.5 by 2.5 cm. Occupying the posterior part of the cervix is a rather extensive adenomyoma. This was densely adherent to the rectum which had been drawn up. For the histologic appearance of the adenomyoma, see Figure 25.

On account of mutilation it is impossible to tell which are the right and which the left appendages. One ovary has been converted into a thin-walled cyst 7 cm. in diameter. The inner surface of this presents a dirty chocolate-colored appearance. It is a corpus luteum cyst. A portion of the other

ovary is covered by dense adhesions. It contains a corpus luteum cyst, 4 cm. in diameter. Accompanying the specimen is one Fallopian tube, which is perfectly normal. As noted from the history, one tube and a part of one ovary were left in place. We had in this case corpora lutea cysts on both sides, and these were covered by adhesions, while both tubes were normal.

The appendix is very hard, 9 mm. in diameter. The lumen of the appendix is not over 1 mm. in diameter.

Histologic Examination.—The cervical glands present the usual appearance. The mucosa lining the body of the uterus shows some small round cell infiltration in the superficial layers. The growth on the posterior surface of the cervix consists of nonstriped muscle and fibrous tissue. Scattered throughout it are large and small islands of uterine mucosa. (Fig. 23.) The stroma of this mucosa shows a considerable amount of hemorrhage. Here and there a uterine gland lies in direct contact with the muscle.

The picture is that of a typical adenomyoma of the recto-vaginal septum.

Case 8 (Septum Case 16)—*Adenomyoma of the recto-vaginal septum; small multiple uterine myomata.* (Figs. 24 and 25.)

History (C. H. I. No. 22465).—C. W., aged 36, was referred to me by Dr. Carlton M. Cook, Oct. 9, 1919.

She began to menstruate at 14 and was regular; the flow was free and lasted from six to seven days. It was formerly painful for the first two days, but now the pain persisted throughout the entire period and the patient had to remain in bed. Her last period ended a few days ago. It had persisted for ten days.

Twelve years ago she had an abdominal operation; several fibroids were removed, one ovary and part of the other were also taken away.

The patient has been worse since she had influenza in October, 1918.

Examination.—The patient was admitted to the Church Home and Infirmary October 9, and operated on Nov. 4, 1919. On examining this patient under anesthesia, I felt a nodule, about 1 cm. in diameter, just posterior to the cervix, and was

instantly reminded of an adenomyoma of the rectovaginal septum. On the left side was an area of thickening, approximately 2 by 3 cm. As there were evidently many adhesions, a definite diagnosis could not be made.

Operation and Result.—I made a median incision and found a few omental adhesions on the anterior abdominal wall. The left tube and ovary had been removed at a previous operation. The right ovary was densely adherent to the pelvic floor and also to an epiploic appendage. We decided that a removal of the uterus was indicated, more particularly as the cervix was adherent to the anterior surface of the rectum. The rectum was also drawn upward. We removed the uterus from left to right, amputating through the cervix and removing the left tube and ovary.

Fig. 25 (Case 8).—Adenomyoma of the rectovaginal septum. For the gross picture, see Figure 24. The muscular growth is very dense, the glands few and far between. In the upper part of the picture is a definite gland lying in direct contact with the muscle, and the surface at a is covered by one layer of cylindric epithelium.

After removing the uterus I took out the cervix, and it was necessary literally to cut the posterior vaginal wall and the cervix away from the rectum. There was just the slightest area of thickening on the anterior rectal wall.

After controlling all oozing we examined the right ureter and found it normal. The left ureter could not be located without a great deal of dissecting. The appendix was curled on itself and adherent. It was also removed. Two drains were left in the pelvis and brought out through the vagina.

The patient left the hospital in excellent condition on Nov. 24, 1919.

Examination of Specimen (Gyn. Path. No. 25477).—The cervix and body of the uterus when put together give a combined length of 8 cm. (Fig. 24.) The uterus is 6 cm. broad and 4 cm. in its anteroposterior diameter. The anterior surface of the uterus is smooth, but nearly the entire posterior surface is covered by adhesions. Projecting from the posterior surface, high up, is a pedunculated bean-shaped myoma, 1.5 cm. long. There are also a few other minute myomas scattered over the surface of the uterus. Attached to the left side of the cervix and extending into the broad ligament is a myoma, 3.5 by 2.5 cm. Projecting from the center of the cervix posteriorly is a small raised area of thickening, about 1 cm. in diameter. This is where the rectum was attached to the cervix. The cavity of the uterus contains a pedunculated submucous myoma, 2 cm. in diameter. The thickening noted on the posterior wall of the cervix is hard and contains a few chocolate-colored areas.

Histologic Examination.—Sections from the cervix show that the mucosa is normal. The growth on the posterior surface of the cervix consists of non-striped muscle and fibrous tissue. In the outlying portions it is interesting to see the manner in which the diffuse myomatous growth is gradually replacing the adipose tissue. Here and there in the diffuse growth is a uterine gland, usually lying in direct contact with the muscle. (Fig. 25.) Some of the growth has, as was noted at operation, been left attached to the rectum.

Case 9 (Septum Case 17).—*Adenomyoma of the recto-vaginal septum.* (Fig. 26.)

History.—Mrs. E. B. H., aged 36, referred to me by Dr. Arthur Wegefarth, entered the Church Home and Infirmary Nov. 1, 1919. (No. 22461.) I had operated on this patient in 1917 for appendicitis. In August, 1919, while at dinner, she was taken with sharp, excruciating pain beneath the right costal margin, and the pain radiated to a point just beneath the right shoulder blade. She was almost drawn double. This attack was followed by nausea and vomiting, and the pain was relieved only by morphine. Since then she had had eight similar attacks. The patient had been married twenty years and had one child, nineteen years ago. She also complained of pain in the left lower abdomen.

Examination.—On making a pelvic examination, under anesthesia, I found the uterus normal in size. The cervix was normal, but just posterior and a little to the left was a rather globular nodule 1.5 cm. in diameter. (Fig. 26.) This seemed fixed to the cervix posteriorly, and on inspection it was found that projecting from the vaginal vault at this point were two bluish-black cysts, about 2 mm. in diameter. On rectal examination the nodule was made out much more clearly. It was directly beneath the mucous membrane, but

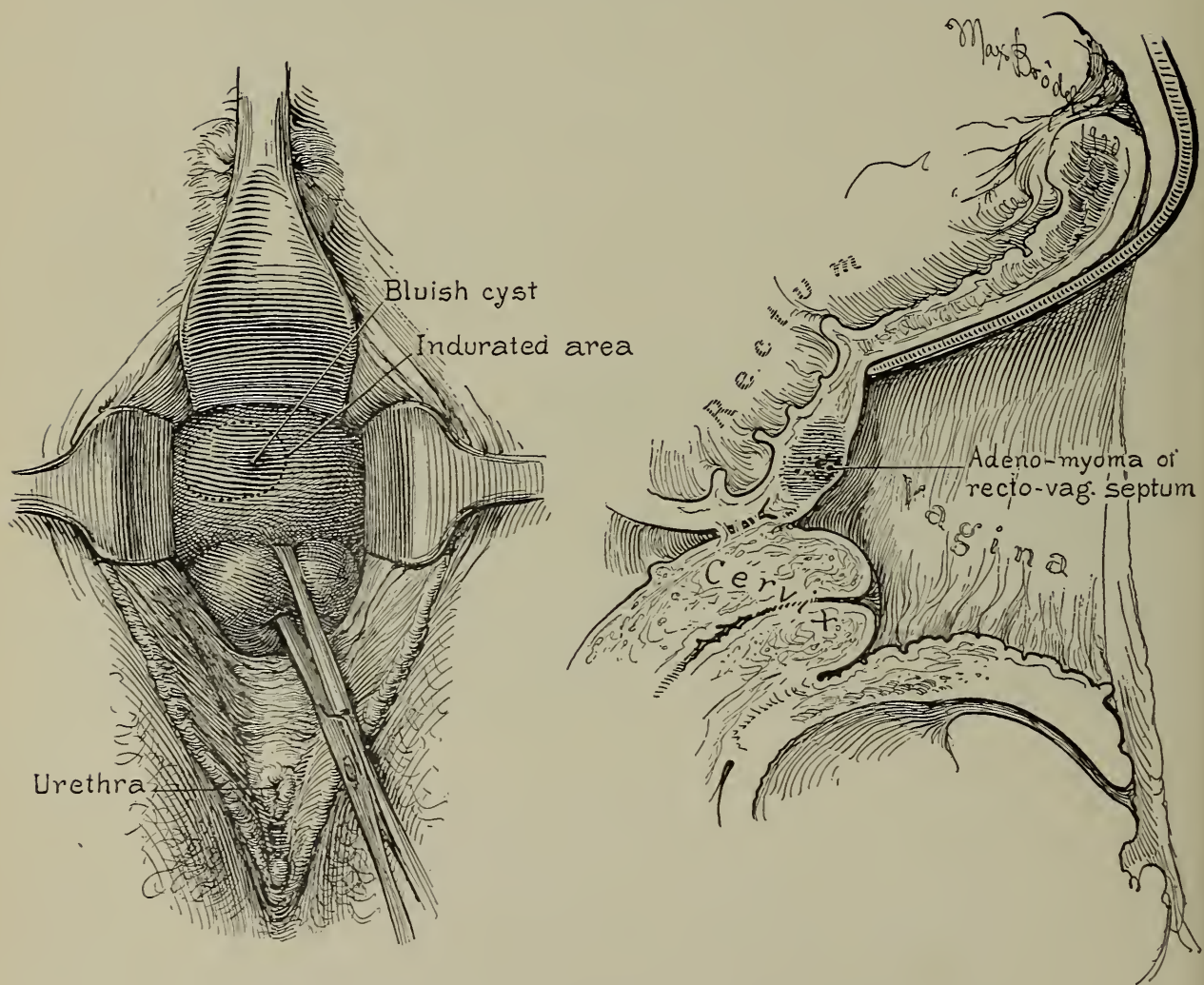

Fig. 26 (Case 9).—Adenomyoma of the rectovaginal septum. The patient is shown in the knee-chest posture. Just behind the cervix and slightly to the left of the median line is a relatively globular nodule about 1.5 cm. in diameter. In this nodule were two bluish black cysts, only one is seen in the picture. The relation of the adenomyoma to the cervix and rectum is clearly indicated in the picture to the right. Although no microscopic examination has been possible, still the diagnosis is certain.

the mucosa had not become adherent. It was a definite adenomyoma.

Operation and Result.—November 4, 1919, I operated and as the patient was not complaining sufficiently of the pelvic condition, and as she had gall-stones, I let the adenomyoma alone. I made a right rectus incision and exposed the gall-bladder, which contained a large number of small stones, the greater number of which formed two conglomerate masses, each about 1.5 cm. in diameter. Some of the smaller stones were in the cystic duct. We removed the stones and drained the gall-bladder. The patient was discharged, much relieved on November 29, 1919.

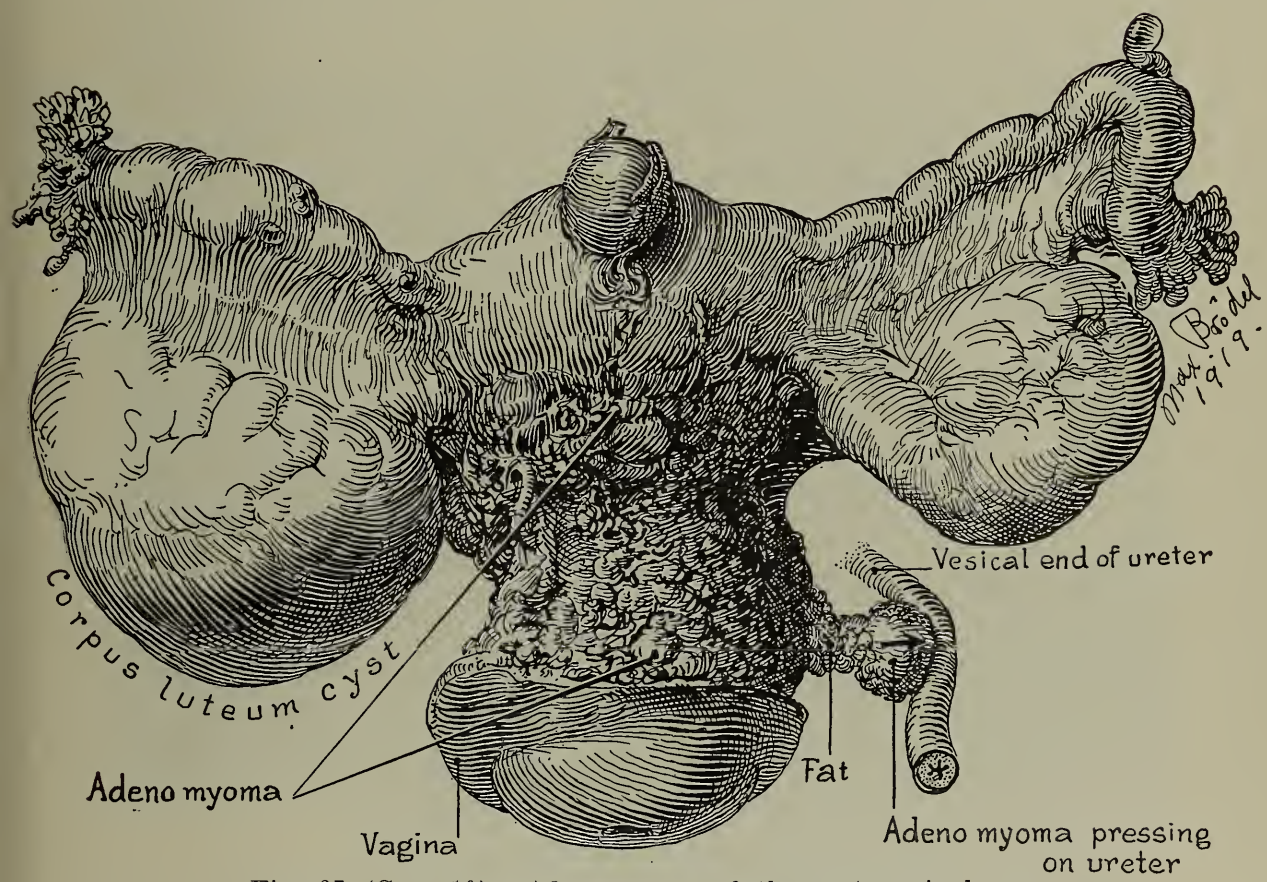

Fig. 27 (Case 10).—Adenomyoma of the rectovaginal septum; discrete and independent adenomyoma in the right broad ligament pressing on and partially obstructing the ureter. Springing from the top of the uterus is a small myoma, and attached to the posterior surface of the uterus are a few adhesions. Occupying the posterior part of the cervix and extending upward is a diffuse adenomyoma. The right tube and ovary are normal. The left tube is normal, but the ovary contains a corpus luteum cyst. In the right broad ligament is a small discrete nodule pressing on the right ureter. It is also an adenomyoma. For the histologic picture of the adenomyoma of the rectovaginal septum, see Figure 28. For that of the broad ligament nodule, Figure 29.

A few weeks later she developed a pelvic abscess, which opened spontaneously into the vagina, and since then she has been perfectly comfortable. It may be necessary to remove the adenomyoma at a later date.

Case 10 (Septum Case 18).—*Adenomyoma of the rectovaginal septum; discrete adenomyoma in the right broad ligament pressing on and partially obstructing the right ureter.* (Figs. 27, 28, and 29.)

History.—Miss R. M., aged 42, was referred to me by Dr. Christian Deetjen on February 27, 1919, complaining of pain

Fig. 28 (Case 10).—Adenomyoma of the rectovaginal septum. The gross specimen is shown in Figure 27. Some of the glands are surrounded by the characteristic stroma, others lie in direct contact with the muscle.

in the left lower abdomen. This had been more or less constant for the last ten years and had been severe for four years. The patient had pneumonia ten years ago followed by empyema. She was admitted to the Church Home and Infirmary on October 20, 1919. (No. 22402.) At that time a small cyst could be felt in the left side of the pelvis. Dr. Hiram

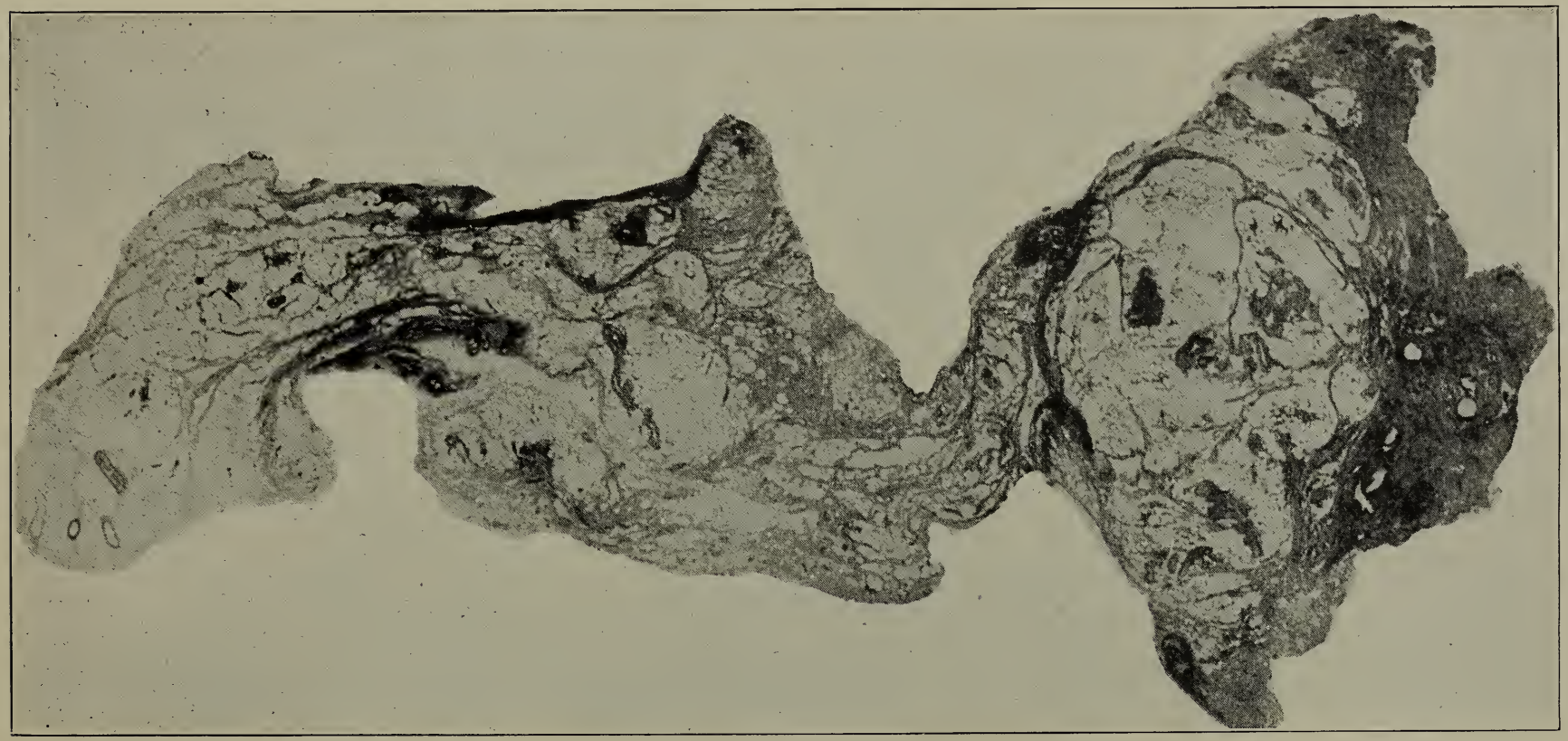

Fig. 29 (Case 10).—Discrete adenomyoma of the right broad ligament pressing on and partially obstructing the ureter. For the appearance at operation, see Figure 27. At the left, where this nodule was attached to the right side of the cervix, most of the tissue consists of fat. As we pass toward the right the adipose tissue is found to be replaced in part by connective tissue. At the extreme right the tissue consists of nonstriped muscle and fibrous tissue, and scattered throughout it are a moderate number of glands resembling those of the uterine mucosa.

Fried, the resident, felt that there might be some trouble with the ureters and suggested their catheterization. A distinct narrowing was felt on the right side not far distant from the bladder. Dr. Guy L. Hunner confirmed this finding. The right ureter was dilated on several occasions, and we finally operated on November 8.

Operation and Result.—On opening the abdomen, I found a corpus luteum cyst, 4 cm. in diameter, on the left side. This was somewhat adherent.

The rectum had grown fast to the posterior surface of the cervix, and at this point the tissues presented a yellowish-brown, rusty appearance. It was perfectly evident that we were dealing with an adenomyoma. We performed a complete abdominal hysterectomy. The posterior vaginal wall separated from the rectum with some difficulty, but after removal of the uterus and upper vagina the bowel showed only a slight thickening. The rectovaginal growth had extended out into the right broad ligament. After its removal we could still feel a nodule far out in the broad ligament This was 1 cm. in diameter, encroached markedly on the right ureter and had given rise to the obstruction that had been noted by Dr. Fried in his catheterization of this ureter. (Fig. 27.) I dissected out the ureter, drew it to one side, and removed the nodule. Two drains were left in the pelvis and brought out through the vagina.

The patient had an uneventful convalescence and was discharged on November 30, 1919.

Examination of Specimen (Gyn. Path. No. 25486).—The uterus is 7 cm. long, 4 cm. broad, and 3 cm. in its anteroposterior diameter. Anteriorly it is smooth. The posterior surface is covered by adhesions. At the fundus posteriorly is a myoma, 1.5 cm. in diameter, and below this a minute myoma. Springing from the posterior surface of the cervix is a nodular thickening, 1.5 cm. in diameter, and extending off from this point is the nodule that pressed on the right ureter. The uterine walls vary from 1 to 1.5 cm. in thickness, and in the fundus the muscle presents a very coarsely striated appearance reminding one somewhat of an adenomyoma. The uterine mucosa is rather thin.

Right Side: The tube and ovary are normal.

Left Side: The ovary contains a corpus luteum cyst, 3 cm. in diameter. The ovary is covered by a few adhesions.

Histologic Examination.—The vaginal portion of the cervix presents the usual appearance. The cervical mucosa is gathered into folds and tends to form small polypi. A few of the glands are dilated, but the cervical mucosa as a whole is relatively normal.

The section from the growth on the posterior surface of the cervix contains a young myoma, 3 mm. in diameter. The diffuse growth consists of non-striped muscle and fibrous tissue. Scattered throughout it are small areas of uterine mucosa. (Fig. 28.) Few of these areas contain more than two uterine glands accompanied by the characteristic stroma. Here and there is a dilated gland.

The nodule from the right broad ligament, the one that pressed on the right ureter, consists for the most part of adipose tissue. (Fig. 29.) Scattered throughout the fat are a good many large blood vessels, and passing off from these are young strands of connective tissue which tend to separate the individual fat globules from one another. The outer end of the growth consists of an irregular mass of fibrous tissue and non-striped muscle. This fibromuscular mass sends prolongations into the surrounding fat, and in the nodule itself some fat still persists. Scattered throughout the muscular tissue are uterine glands occurring singly or in groups. When in groups they are surrounded by the characteristic stroma, which shows some hemorrhage. When singly they lie in direct contact with the muscle. Some of the glands are dilated.

This is a case of adenomyoma of the rectovaginal septum. There is also a discrete adenomyoma apparently independent of the uterus and pressing on the right ureter.

The preceding cases have come under my individual care. The following case of adenomyoma of the rectovaginal septum is a rather advanced one and is well worth recording. The operation was performed at the Hebrew Hospital by Dr. Alfred Ullman, and the specimen was sent to me for examination. This history was furnished me by Dr. E. H. Teeter.

Case 11.—*Adenomyoma of the rectovaginal septum.*

History.—M. H., aged 46, was admitted to the Hebrew Hospital, April 24, 1919, complaining of bleeding for nine

weeks, and said she felt very sore and tired all over. She has not had any previous illness. Her menses began at 13, were regular, and usually lasted from seven to nine days. The flow was always excessive and was accompanied by pain in the left lower abdomen for three days. In June, 1918, her menses stopped for three months, and then there was a little bleeding for a couple of days. The bleeding soon returned and had persisted for the last nine weeks. It had been very severe. On vaginal examination, April 25, Dr. Teeter made the following note: "Vaginal outlet somewhat relaxed, cervix normal. The uterus and cervix are tied hard and fast and

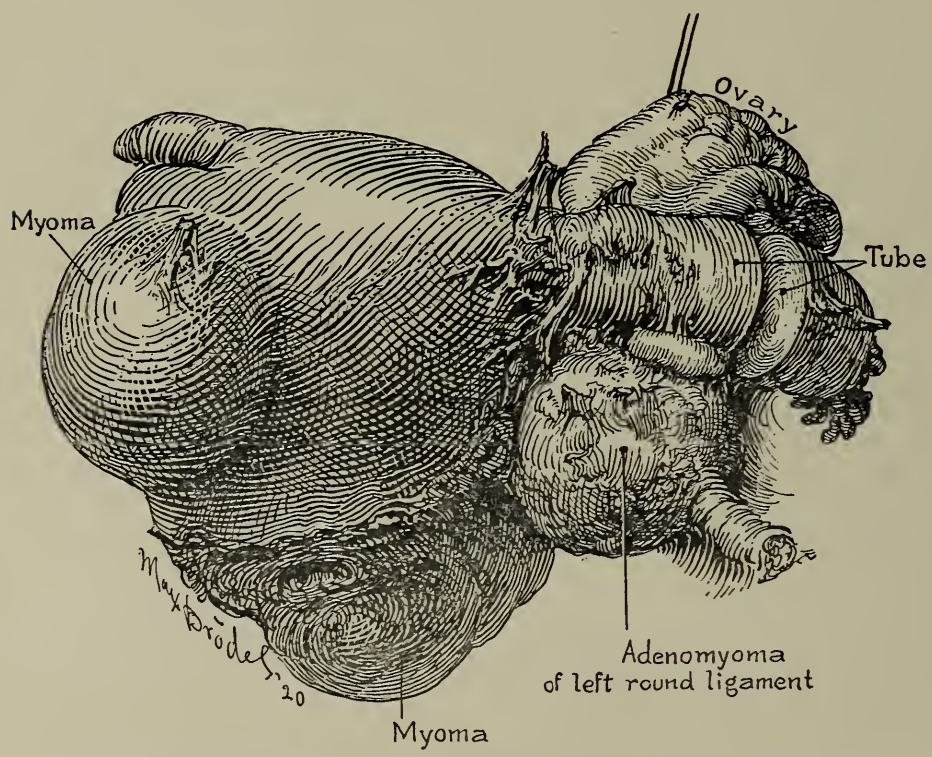

Fig. 30 (Case 12).—Adenomyoma of the left round ligament. The uterus contains several small discrete myomas. The left round ligament near its uterine attachment contains a spherical myoma, 1.5 cm. in diameter. This was adherent to the tube at its inner end. Lying between the round ligament nodule and the tube and adherent to both was a loop of small bowel. The left tube is unusually thick. Its fimbriated end is constricted but open. The tube on histologic examination showed slight inflammation. The ovary contained a corpus luteum. It was slightly adherent. For the low power picture of the adenomyoma of the round ligament, see Figure 31; for the higher power, Figure 32.

cannot be moved. The uterus itself is normal in size. Just posterior to the cervix is a growth in the vaginal vault, causing puckering of the vaginal mucosa. This growth is hard and is glued fast to the rectum. On rectal examination the

mass is found to be adherent to the rectum, but the growth does not involve the rectal mucosa."

There was a profuse bloody discharge from the uterus, and Dr. Teeter at once made a diagnosis of adenomyoma of the rectovaginal septum.

Fig. 31 (Case 12).—Adenomyoma of the round ligament. This is a low power photomicrograph of the round ligament nodule seen in Figure 30. Fully one-half of the tissue consists of islands of perfectly normal uterine mucosa. For the high power, see Figure 32.

A complete abdominal hysterectomy was performed by Dr. Alfred Ullman, on April 26, and the patient was discharged on May 20.

Examination of Specimen (Gyn. Path. No. 25513).—The uterus is 9 cm. long, 6 cm. broad, and 5 cm. in its anteroposterior diameter. The anterior surface is smooth, as is also the posterior surface. Just anterior to the insertion of the right tube is a myoma, 6 mm. diameter.

Springing from the posterior surface of the cervix and extending over to the right side and also involving the posterior vaginal wall is a hard, irregular growth, 4.5 cm. broad and 2.5 cm. from above downward. It is exceedingly firm, and where it involves the vagina are five or six dark-brown areas of discoloration. These vary from 1 to 2 mm. in diameter. On section, the growth reminds one of myomatous tissue, and scattered throughout it are a few irregular cavities filled with a yellowish-brown or yellow material. The cavity of the uterus looks normal.

Histologic Examination.—Sections through the vaginal portion of the cervix and also through the adjoining vaginal wall reveal a normal mucosa. Beneath the vaginal mucosa the dense stroma contains isolated uterine glands. The small chocolate-colored cysts noted beneath the vaginal mucosa are filled with blood. They are lined with one layer of cylindric epithelium, and projecting into one of the cysts is a small knob-like elevation of typical stroma of the endometrium of the body of the uterus. Some of these cysts lie in direct contact with the surrounding muscular and fibrous tissue, others are separated by a definite endometrial stroma.

The growth on the posterior surface of the cervix and involving the posterior vaginal wall consists of non-striped muscle and fibrous tissue. Here and there small areas of adipose tissue have been enveloped. Scattered throughout the growth are isolated uterine glands and groups of glands. Nearly all of these glands are surrounded by the characteristic stroma, and some of them are filled with blood.

The case is one of adenomyoma of the rectovaginal septum. It is in just such a case that we would later expect to find vaginal polypi had the operation been delayed for a year or two.

ADENOMYOMA OF THE UTERINE HORN OR FALLOPIAN TUBE

In addition to the diffuse adenomyoma of the uterus, one finds another variety of adenomyoma in this organ. These are the small adenomyomatous nodules noted in one or both uterine horns. They vary from a few millimeters to about 2 cm. in size and are often associated with an old inflammatory process in the tubes. These growths usually contain many isolated glands embedded in non-striped muscle and inflammatory tissue. The glands usually lie in direct contact with the muscle and are devoid of the characteristic stroma. Adenomyoma of the uterine horn, as a rule, can hardly be looked on as a distinct clinical entity, but, rather, I think, as part of the end-result of a mild inflammatory process.

In a case (Gyn. Path. No. 25515) in which we had a bicornate uterus, and a most extensive adenomyoma of the right cornua, the left tube 2 cm. beyond the uterine horn was 1 cm. in diameter. On histologic examination, it was found to be the seat of an adenomyoma. Some of the glands lay in direct contact with the muscle, others were surrounded by the typical stroma of the uterine mucosa. I know of no other tube presenting such a picture.

In 1896, it fell to my lot to record the first growth of this character. Since then quite a number have been noted. Somewhere along the course of the round ligament, usually near the external ring, a nodule, one or more centimeters in diameter, is detected. On going carefully into the history, it will be noted that this growth swells perceptibly at the period. One patient was sent to me on the assumption that a hernia

4. Cullen, T. S.: Adenomyoma of the Round Ligament, Bull. Johns Hopkins Hosp., vol. vii, p. 112, May-June, 1896; Further Remarks on Adenomyoma of the Round Ligament, Bull. Johns Hopkins Hosp., vol. ix, p. 142, June, 1898; Adenomyoma of the Round Ligament, and Incarcerated Omentum in an Inguinal Hernia, Together Forming One Tumor, Surg., Gyn. & Obst., vol. xxii, p. 258, March, 1916.

existed, but even in this case in the history it was recorded that the swelling was more painful and more prominent at the period.

With gradual increase in size of the nodule it may become intimately blended with the fascia. In my second case the diagnosis was easily confirmed at operation, even before any microscopical examination had been made. The surrounding fascia had imbibed a large amount of golden-yellow pigment,—the remnant of old menstrual blood.

Some of these growths can be removed very readily; others, however, in time may become so intimately blended with the surrounding structures that they must be literally cut away. On histological examination, they are found to be made up of non-striped muscle, fibrous tissue, and the characteristic uterine glands. Strands of fibrous tissue and non-striped muscle spread out into the surrounding adipose tissue.

Just lately (April, 1920) we have encountered another case of adenomyoma of the round ligament in our clinic in the Johns Hopkins Hospital.

Case 12 (Gyn. No. 25776).—*History.*—E. S., aged 36, white, was admitted to the Johns Hopkins Hospital on April 1, 1920, complaining of dysmenorrhea and of bleeding between periods. She has been married four years, but had had no children.

Examination.—On pelvic examination the outlet was found to be relatively intact. Protruding from the cervix was a small polyp. The body of the uterus was in retroposition, was irregular, and apparently contained five or six small myomatous nodules. High up in the left vaginal fornix was a mass 2 or 3 cm. in diameter.

Operation and Result.—April 3, 1920, Dr. Leo Brady operated and found the uterus in retroposition. It contained several small myomas. In the left round ligament near the uterus was a nodule nearly 2 cm. in diameter. The tube was adherent to this and also to a loop of small bowel. The right appendages were free. After the loop of bowel had been freed, a supravaginal hysterectomy was performed. The patient made a satisfactory recovery except for a slight elevation of temperature during the first week following operation, when there was a friction rub. This was thought to be due probably to a lighting up of an old pleurisy. She was discharged in good condition on April 21, 1920.

Examination of Specimen (Gyn. Path. No. 25850).—The uterus, which had been amputated through the cervix, measures 5 cm. in length, 5 cm. in breadth, and 4 cm. in its antero-posterior diameter. It contains several interstitial myomas.

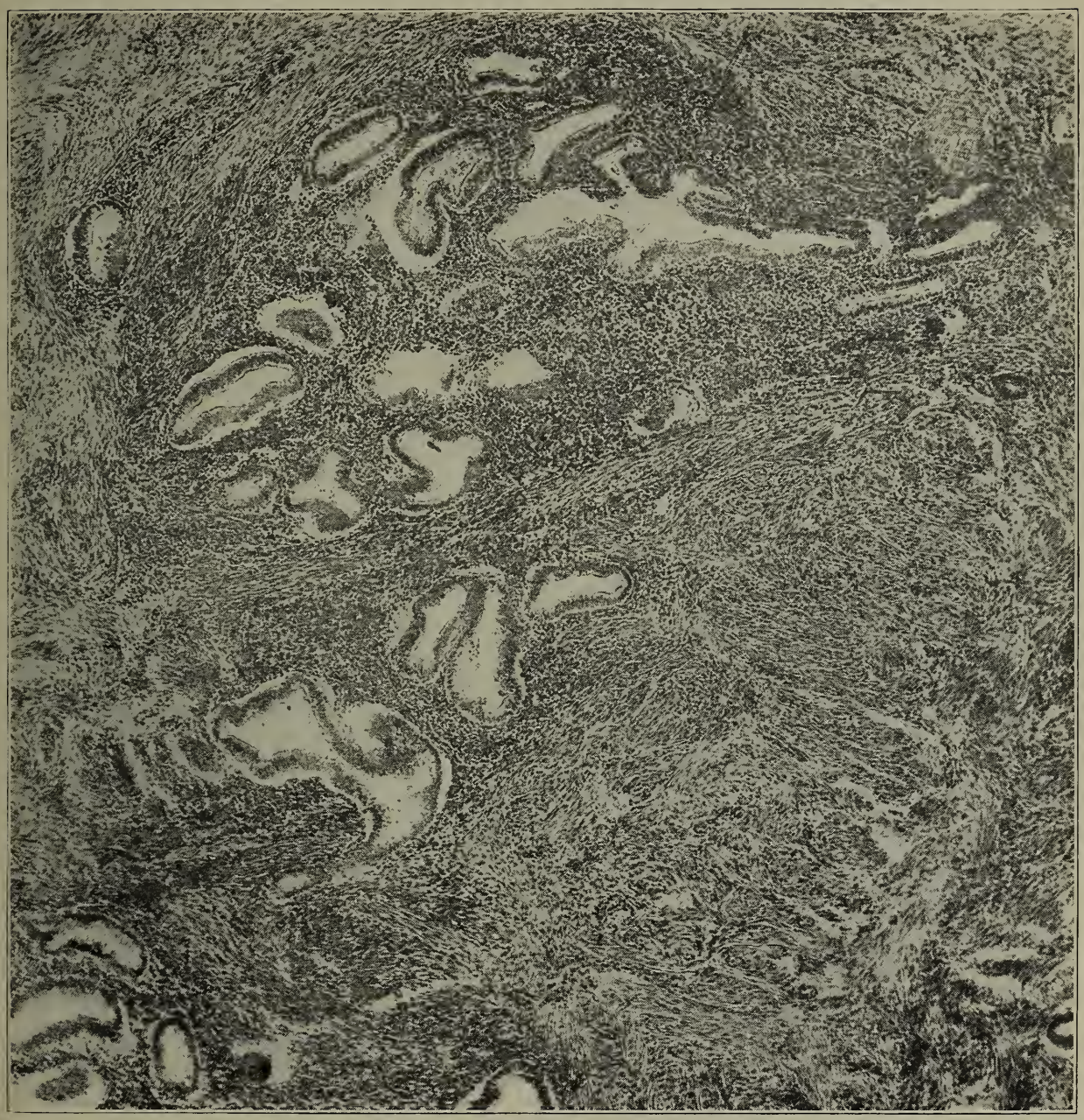

Fig. 32 (Case 12).—Adenomyoma of the round ligament. For the gross appearance, see Figure 30, and for the low power picture, Figure 31. The round ligament nodule consists of myomatous tissue. It contains large quantities of normal uterine mucosa.

In the left round ligament near the uterus is a spherical nodule 1.5 cm. in diameter. (Fig. 30.) This is partly covered by adhesions. The left tube reaches a diameter of 1 cm. Its fimbriated end is constricted but open. The ovary is normal in size. It contains a corpus luteum and is partly covered by adhesions.

Histological Examination.—This shows that the nodule in the left round ligament is riddled with large islands of typical uterine mucosa. (Figs. 31 and 32.)

UTERINE MUCOSA IN THE OVARY

In 1898 my colleague, Dr. William Wood Russell, reported a case in which the ovary, although showing little increase in size, contained large islands of uterine mucosa. The report of this case was published in detail in the *Bulletin of Johns Hopkins Hospital* for that year, and the article is freely illustrated.

Within the last year Dr. Charles Norris, of Philadelphia, sent me a section of a relatively small ovary containing a large island of normal uterine mucosa (Figs. 33 and 34).

Dr. DeWit B. Casler, of our department, at the last meeting of the American Gynecological Society reported a unique case which has a definite bearing on this subject.

The patient, a trained nurse, aged 38, had had excessive periods for one year. On examination the uterus was found to be three times its natural size. Hysterectomy was performed. The increase in size was due to a diffuse myomatous thickening, and scattered throughout this diffuse growth were quantities of stroma identical with that of the uterine mucosa. This stroma, however, contained no glands. The tumor resembled in every particular the picture of an ordinary adenomyoma of the uterus save for the fact that the glands were missing from the stroma.

This patient after the complete hysterectomy still continued to menstruate regularly through the vaginal vault. A vaginal examination about three and one-half years after the hyster-

ectomy revealed the fact that the ovary which had been left was perfectly normal in size. A little later it commenced to grow larger, and when the abdomen was opened, four years after the hysterectomy, this ovary was the size of a medium-sized grape-fruit.

On histological examination great quantities of typical uterine mucosa were found scattered throughout the ovarian tumor, thus clearly explaining why the patient had contin-

Fig. 33.—An ovary containing uterine mucosa. This is a very low power photomicrograph of a section through an entire ovary that was little enlarged. It was sent me by Dr. Charles Norris of Philadelphia. On the left is a relatively small cyst, c. At a in the substance of the ovary is a large area of typical uterine mucosa. This is connected with an irregular cyst cavity. On the upper edge of the section is normal luteal mucosa, b. The tubes have evidently been intimately adherent to the ovary. In Figure 34 one sees a higher magnification of the mucosa.

ued to menstruate without any uterus. The ovary contained all the essential elements, normal ova, and practically normal uterine mucosa and the small tract left where the uterus had

been removed supplied the necessary avenue along which the menstrual flow escaped.

In the following case, in which the uterus was about three times enlarged as a result of interstitial and submucous myomas and in which the appendages were glued together by adhesions, the right ovary contained small areas of typical uterine mucosa.

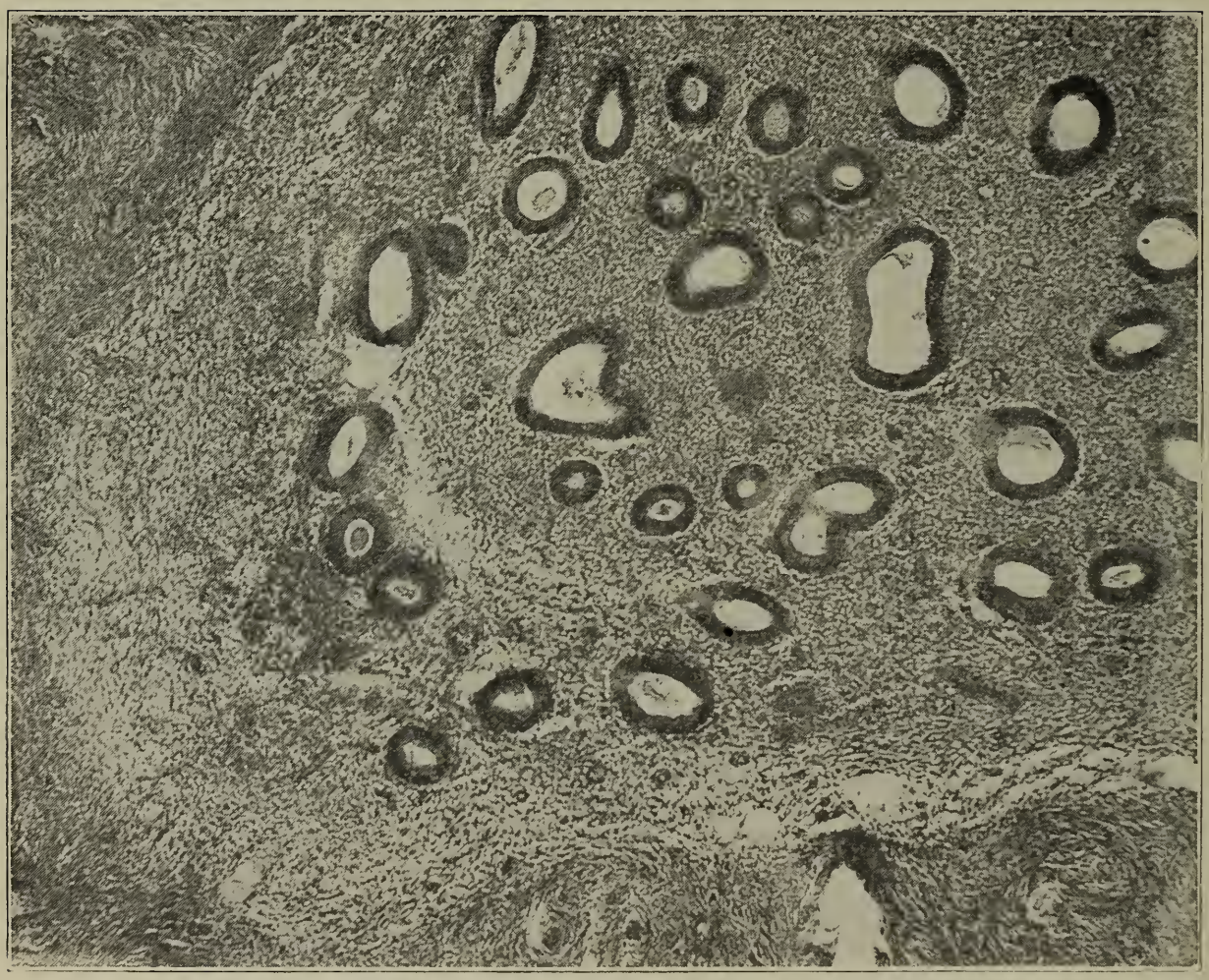

Fig. 34.—Uterine mucosa in the ovary. This specimen was sent me by Dr. Charles Norris of Philadelphia. For the low power picture, see Figure 33. The area of mucosa is sharply defined and consists of typical uterine mucosa embedded in the substance of the ovary.

CASE 13.—*A myomatous uterus with adherent appendages on the right side, and on the left a small ovarian cyst containing uterine mucosa in its walls.* (Figs. 35 and 36.)

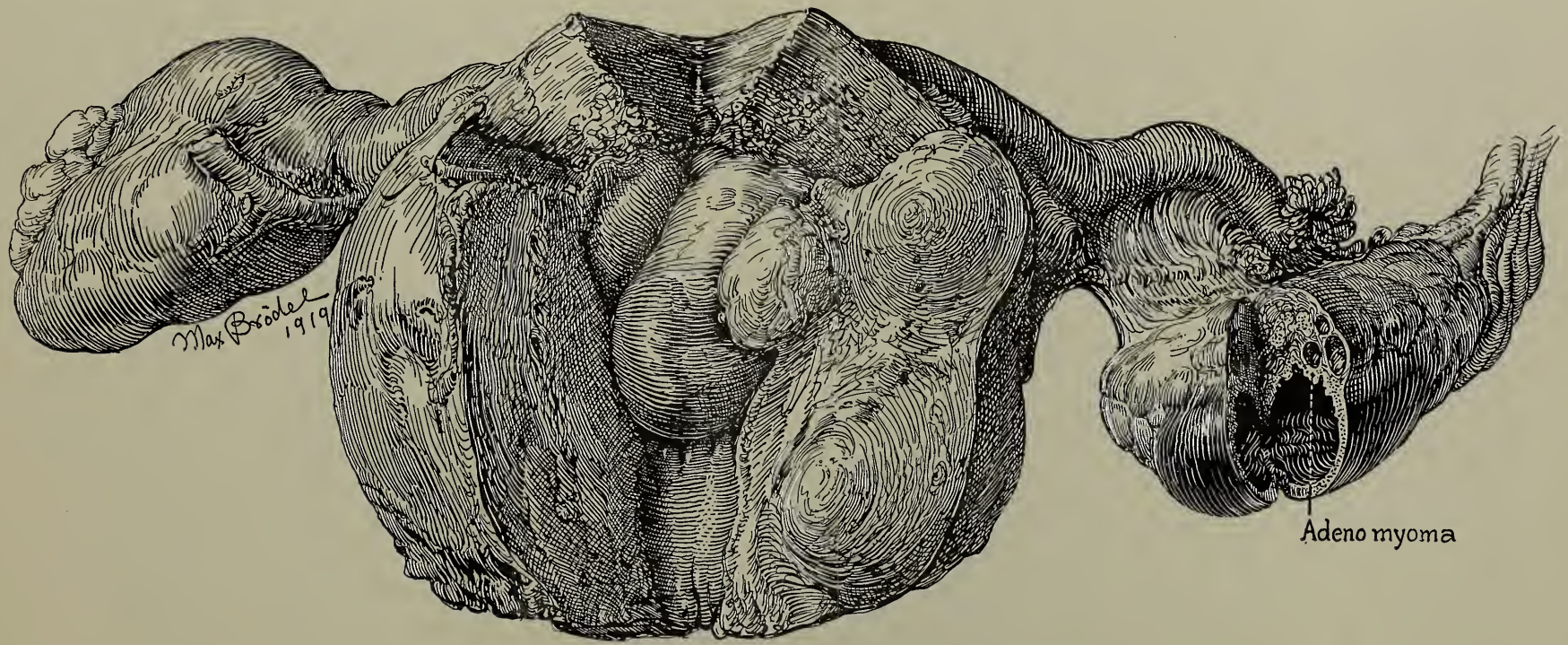

Fig. 35 (Case 13).—A myomatous uterus with adherent appendages on the right side and on the left a small ovarian cyst containing uterine mucosa in its walls. The uterus contains subperitoneal, interstitial and submucous myomas. The left ovary contains a cyst lined in part by uterine mucosa, Figure 36.

Examination of Specimen (Gyn. Path. No. 22505, Sept. 19, 1916).— The specimen consists of the supravaginally amputated myomatous uterus together with the appendages. (Fig. 35.)

The portion of the uterus present is 10 cm. long, 10 cm. broad, and 10 cm. in its anteroposterior diameter. At the fundus anteriorly are a few omental adhesions. Occupying the posterior wall of the uterus is a myoma 8 cm. in diameter. Scattered throughout the anterior wall are several nodules, the largest 3 cm. in diameter. Projecting into and filling the cavity of the uterus is a myoma, 4 cm. long and 2.5 cm. broad.

Right Side: The tube is 8 cm. in length and varies from 8 to 10 mm. in diameter. Its fimbriated end is free. The ovary is 7 cm. in length. It reaches a thickness of 2.5 cm. Attached to the outer end is a moderate amount of fat. This appears to be omental in character. In the lower end of the ovary is what appears to be a collapsed corpus luteum cyst. It is about 4 cm. in length.

Left Side: The tube is 11 cm. long. At the cornu, it is 1.3 cm. in diameter. In its middle portion, it is a little smaller, but in its distal 5 cm. it varies from 2 to 2.5 cm. in diameter. Where dilated it has thin walls, a brownish inner surface and apparently contains old blood. Its fimbriated end is closed and between the closed end and the ovary, omental fat has become densely adherent. The ovary is 6 cm. long and varies from 2 to 3 cm. in thickness. It is covered by adhesions.

Histological Examination.—It is difficult to get the exact relationship on account of the ragged condition of the specimen, but on microscopic examination of the left ovarian cyst, which was lined with a brownish membrane, it is seen that the cyst has an inner lining of cylindric epithelium which here and there tends to form folds. At some points beneath the epithelium there is a definite stroma and embedded in this are a few glands. (Fig. 36.) The cyst is partially filled with blood.

In a case (Gyn.-Path. No. 25003) in which the uterus was 13 by 11 cm., the enlargement was due to a submucous myoma. On the posterior surface of the cervix and lower part of the body of the uterus was the most widespread adenomyoma of the rectovaginal

septum that I have ever seen. (Fig. 16.) I had literally to cut the cervix away from the rectum.

On the surface of, and intimately attached to, the right ovary was a miniature uterine cavity. (Fig. 21.) The glands in this showed a moderate hypertrophy. Other sections from the same ovary showed a diffuse adenomyoma intimately blended with the ovarian tissue, so intimately that no line of demarcation could be detected. It must be remembered, however, that this ovary was firmly glued to, and continuous with, the diffuse adenomyoma that occupied the posterior surface of the uterus. It is quite possible that the uterine mucosa on the surface of this ovary was due to an overflow of the adenomyoma of the rectovaginal septum.

On October 25, 1919, I received a very interesting letter from Dr. Otto Schwarz, of St. Louis. In it he referred at length to several cases of adenomyoma that he had recently seen. Among other specimens examined was one in which the ovary contained uterine mucosa. Dr. Schwarz said:

> The ovarian case was most interesting; this ovary was removed about a year and a half ago. It was about the size of a hen's egg and showed nothing unusual externally. On section it showed several cavities which were filled with blood, partly clotted. Two large blocks were cut transversely across the ovary. . . . In one of the sections I enclose the mucosa appears to communicate with the surface, but this is due to a tear. Throughout the entire two blocks, the abnormal structure was well within the ovary. The sections show the lesion well demarcated from the rest of the stroma of the ovary. There are two cavities. These are lined with tissue similar to the endometrium.

I had the opportunity of examining other sections of the ovary with Dr. Schwarz in his laboratory at the Washington University in St. Louis a few months later. It is a beautiful example of an ovary containing miniature uterine cavities. Figure 37 is a photomicro-

graph that I have had made from one of Dr. Schwarz' sections.

From the foregoing it is evident that in due time a sufficient number of cases will undoubtedly be reported, and then we shall probably be able to give a composite picture of both the clinical course and of the histologic changes that occur in this most unusual group of cases.

Fig. 36 (Case 13).—A small ovarian cyst lined in part by uterine mucosa. The debris in the upper part of the picture is composed chiefly of old blood. The cyst wall is lined by one layer of cylindric epithelium. In places, this lies in direct contact with the ovarian tissue, but here and there is separated by a definite stroma. Near the right, the stroma is very evident, and embedded in it is a gland resembling those of the body of the uterus. For the gross appearance, see Figure 35.

ADENOMYOMA OF THE UTERO-OVARIAN LIGAMENT

These are naturally of little clinical significance and will be recognized only in the laboratory. I have reported one case. A multinodular myomatous uterus was removed, and springing from the utero-ovarian

ligament was a myoma several centimeters in diameter. In the center of this were islands of typical uterine mucosa.

(This case was reported at length in my book on Adenomyoma of the Uterus, page 140, Figs. 41 and 42.)

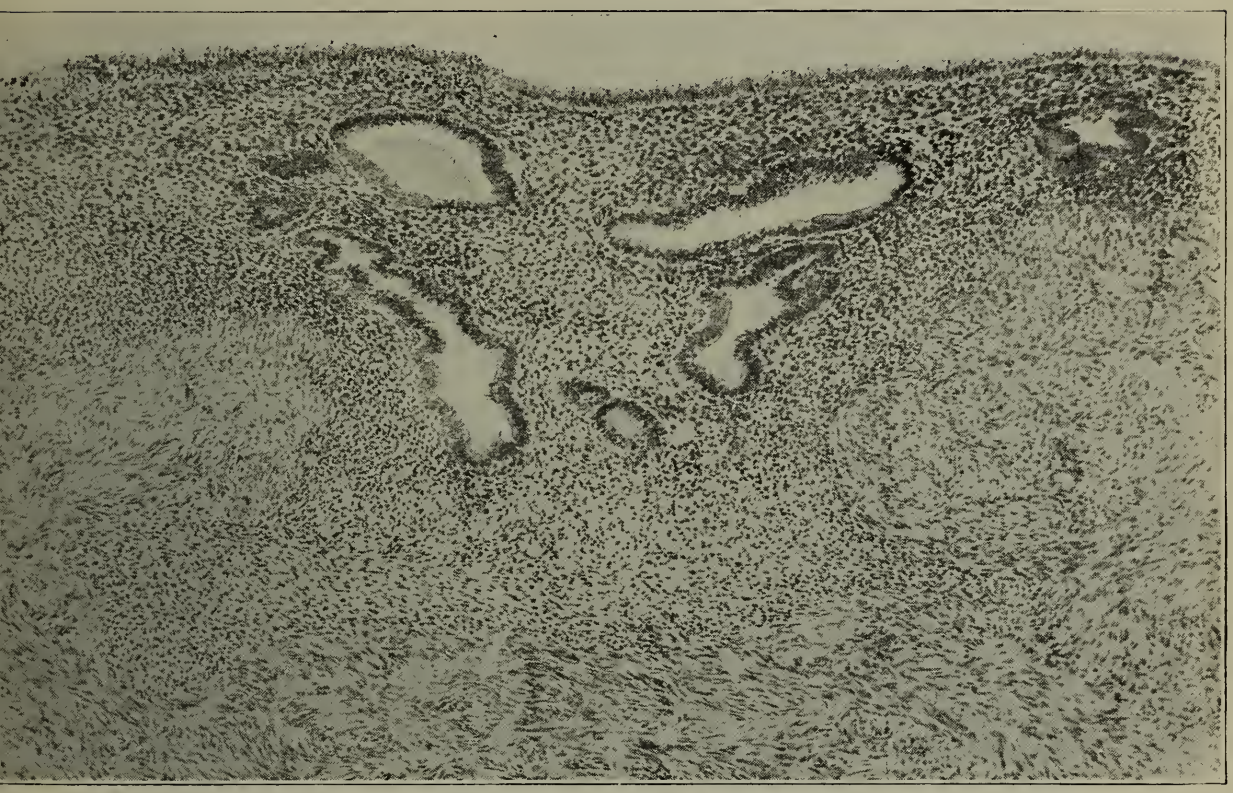

Fig. 37.—Uterine mucosa lining a small cyst in the ovary. The specimen was sent me by Dr. Otto Schwarz of St. Louis, Mo. The cyst wall is lined with cylindric epithelium. Beneath this in the central portion of the picture is a definite mucosa consisting of stroma and glands similar to those found in the body of the uterus.

ADENOMYOMA OF THE UTEROSACRAL LIGAMENT

Several years ago my colleague, Dr. William Wood Russell, removed a pea-sized nodule from the right uterosacral ligament. On histological examination it presented a typical adenomyomatous picture.

Since then I have seen a cyst 1.5 cm. in diameter apparently springing from the right uterosacral ligament. It contained yellowish-brown putty-like material. It may belong to this group, but of this I cannot speak with certainty as the histological picture was not very definite.

Fig. 38 (Case 14).—Cyst of the right uterosacral ligament. During an operation for general pelvic adhesions, the cyst noted in the right uterosacral ligament was found. It is rather spherical, 1.5 cm. in diameter and was filled with brownish putty-like material. It at once reminded me of an adenomyoma. Histologic examination, however, failed to reveal glands or any epithelial lining to the cyst.

Case 14.—*Possible adenomyoma of the right uterosacral ligament.* (Fig. 38.)

History (Gyn. No. 23906).—A. B., aged 28, colored, was admitted to the Johns Hopkins Hospital on April 5, 1918. In the course of an operation for intestinal and omental ad-

hesions and bilateral ovarian cyst, a small nodule was found in the right uterosacral ligament.

Operation and Result.—The midline scar of a previous operation excised. The omentum was found adherent along the line of the old scar. Scattered over the omentum and over the pelvic peritoneum were several small nodules, varying from 2 to 3 mm. in diameter. These were made up of a brownish, putty-like material.

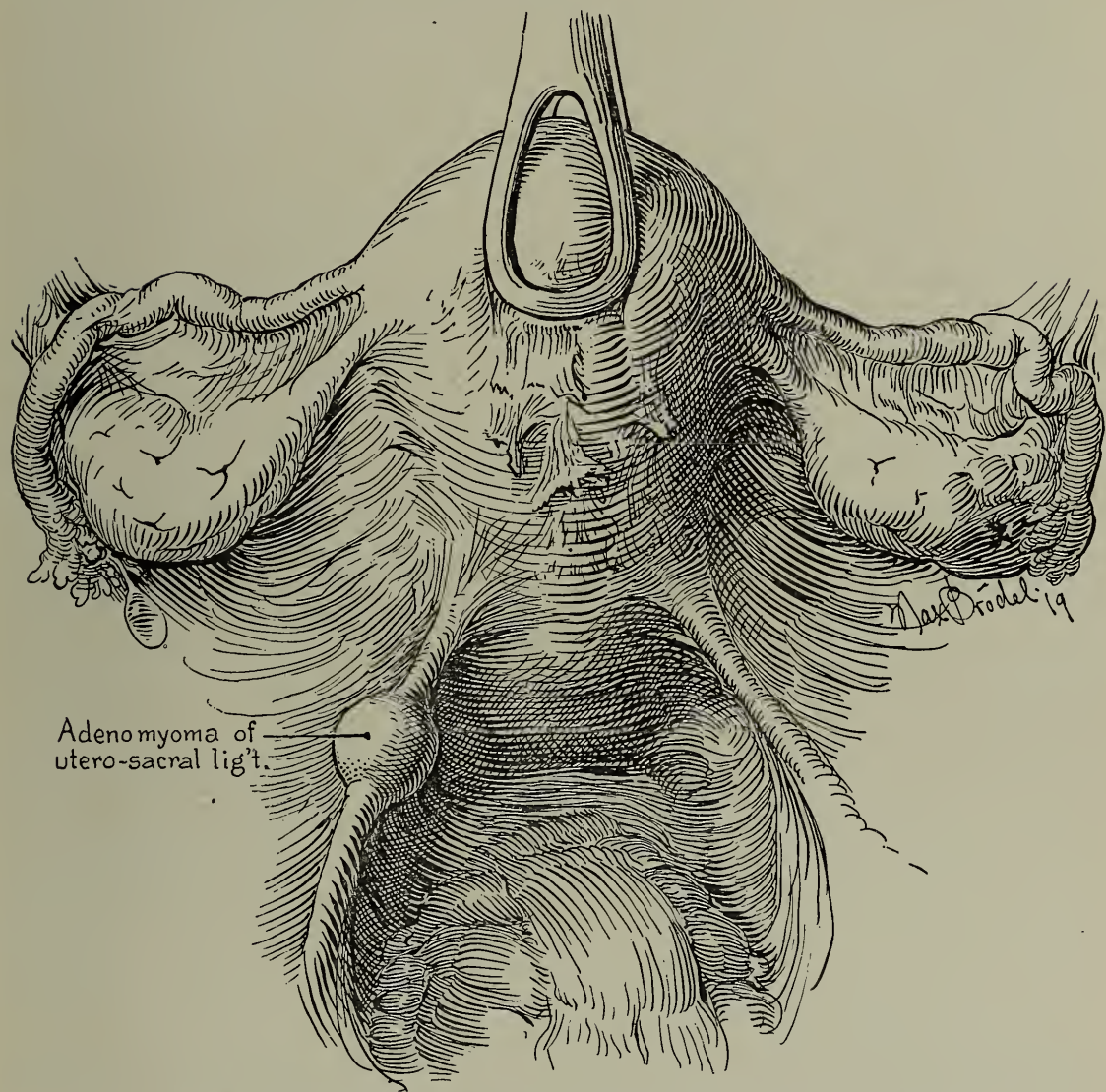

Fig. 39 (Case 15).—Adenomyoma of the left uterosacral ligament. On the posterior surface of the uterus are numerous adhesions. Both ovaries were lightly adherent. It was possible to save all the pelvic structures. In the left uterosacral ligament is a well circumscribed spherical nodule. This had a slightly yellowish brown tinge. For the histologic picture, see Figure 40. It was a typical adenomyoma.

The body of the uterus was firmly attached to the abdominal wall, to which it had evidently been sutured at a former operation. It was freed. There was a cyst about 5 cm. in diam-

Fig. 40 (Class 15).—Adenomyoma of the left uterosacral ligament. For the gross appearance of the nodule, see Figure 39. Some of the glands lie in direct contact with the muscle, others are surrounded by the characteristic stroma.

eter on the left side; this was resected. On the right side was a small cyst; this was also resected.

A tumor about 1.5 cm. in diameter was seen in the right uterosacral ligament, 3 cm. from the cervix. (Fig. 38.) This

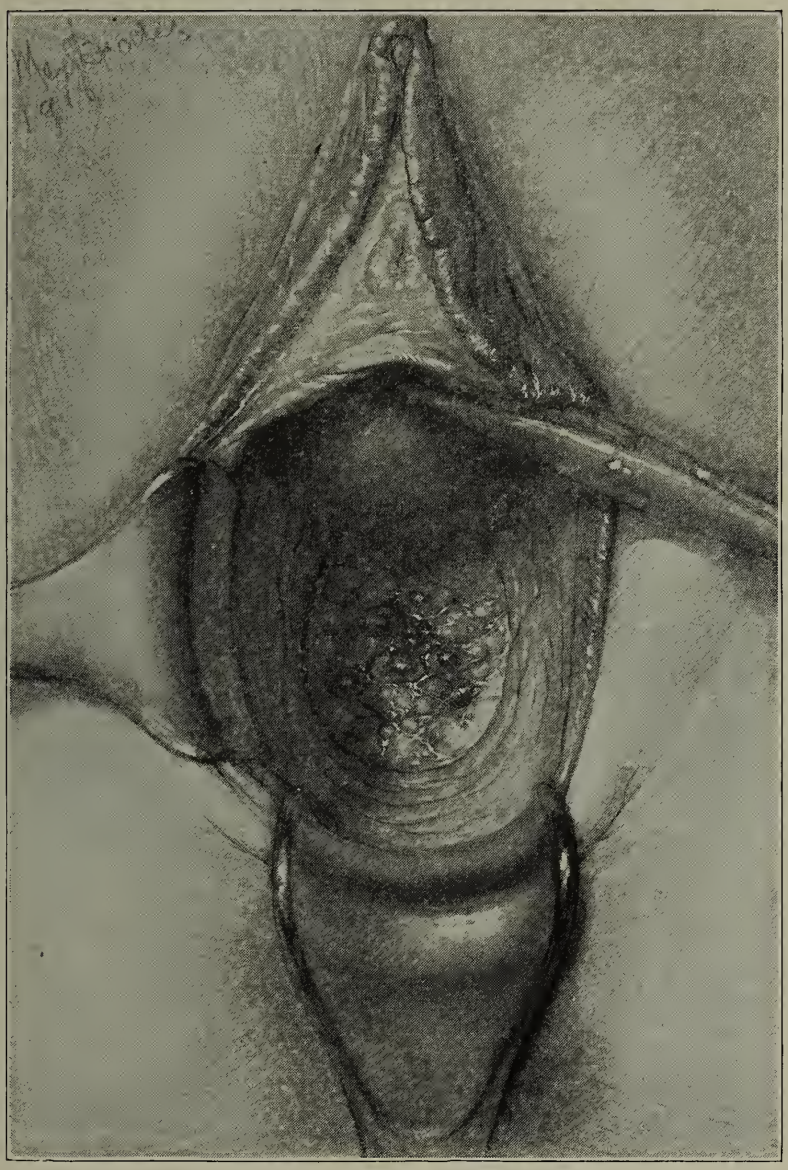

Fig. 41 (Case 16).—Adenomyoma of the rectovaginal septum. The neck of the uterus has been drawn strongly forward. Just posterior to the cervix is an oval and slightly raised area about 2 by 2 cm. The surface of this is roughened and lobulated. The surfaces of some of the lobulations are somewhat cystic and a few of them were bluish black, indicating that they contained old menstrual blood. This area was firmly fixed to the right side of the pelvis. For the abdominal picture, see Figure 42, and for the histologic picture, Figure 43.

tumor felt rather firm and was covered with peritoneum. I dissected the right ureter free and pushed it outward. The peritoneum over the tumor was then opened, and the tumor found to be yellowish red. It was excised. During its removal there was an escape of a light yellow, oily, caseous material. The peritoneum was brought together, and the abdomen closed. A small cigaret drain was laid in the lower angle of the abdominal incision. The patient was discharged April 29, 1919.

Examination of Specimen (Gyn. Path. No. 23986).—The specimen consists of a collapsed cyst, 1.5 cm. in diameter. This, as noted at operation, apparently sprang from the right uterosacral ligament. It contained yellowish-brown, putty-like material, which escaped during the operation.

Histological Examination.—This revealed a wall consisting in large measure of fibrous tissue. There was no trace of epithelium.

Clinically, this case bore a striking resemblance to an adenomyoma, but whether it was actually an adenomyoma that had undergone retrograde changes, it is, of course, impossible to determine. We can think of nothing else that would occasion such a condition.

On May 20, 1919, I operated on a patient who had numerous pelvic adhesions. In the left uterosacral ligament a short distance from the uterus was a rounded nodule 1.5 cm. in diameter. I isolated the left ureter and then removed the nodule, bringing the several ends of the ligament together again. This nodule on histological examination proved to be a typical adenomyoma. The case is as follows:

Case 15.—*Adenomyoma of the uterosacral ligament* (Figs. 39 and 40).

History.—Miss N. E. T., aged 36, white, was admitted to the Church Home and Infirmary (No. 21398) on May 19, 1919. I saw her in consultation with Dr. A. E. Plumb on April 24. Her menses began at 15. At first they were regular, but for a year they had at times been a week ahead. On the second day they were accompanied by a good deal of pain. The last period had begun two weeks before I saw her.

Fig. 42 (Case 16).—Adenomyoma of the rectovaginal septum, independent adenomyoma of the sigmoid almost completely blocking the lumen of the bowel. The right appendages have been removed, the right broad ligament opened up, the right uterine artery ligated and cut and the ureter dissected out. The vagina has been opened and the adenomyomatous thickening on the posterior vaginal wall cut away from the vagina and left attached to the rectum. We were preparing to push the adenomyomatous area together with the adjacent rectum down so that it would be entirely extraperitoneal and so that it could be removed through the vagina a few days later. We at this moment, however, noted the puckered area at the pelvic brim. This bore a strong resemblance to carcinoma, but no metastases could be found, so we came to the conclusion that it also might be an adenomyoma. The peritoneum of the sigmoid was then severed on either side to a point well above this second growth, the entire mass was pushed down to the pelvic floor and the peritoneum so drawn over it that the entire area was practically extraperitoneal. The abdomen was then drained. We expected to remove the entire diseased area from below at a later date. The patient, however, died of infection. At necropsy the sigmoid growth was found, as indicated by the picture, to have almost completely blocked the lumen of the bowel. It was a typical adenomyoma. This accounted for the fact that the bowel symptoms were so marked at the time of menstrual period. For the histologic picture of the adenomyoma of the sigmoid, see Figure 43.

Two years ago, she had an attack of acute appendicitis and for six months had had intense pain above the pubic bone. On examination, I found that she had a good deal of discomfort just above the symphysis and some tenderness in the appendix region. The outlet was slightly relaxed, the cervix was forward, and the body of the uterus back on the bowel. No thickening could be made out on either side.

Operation and Result.—May 20, 1919, we dilated thoroughly. On opening the abdomen we found the body of the uterus adherent to the rectum. Both tubes and ovaries were also adherent. The adhesions were loosened, and the fimbriated ends of both tubes were found to be normal.

In the left uterosacral ligament was a thickening, 1.5 cm. in diameter. (Fig. 39.) This had a slightly yellowish-brown tinge. It strongly suggested an adenomyoma, but I could not say with any degree of definiteness because the ovary was adherent over it. The ovary, however, did not contain any corpus luteum. After releasing the adhesions we dissected out the left ureter, so that we would know exactly where we were. We then cut away the growth from the left uterosacral ligament and in so doing cut across the uterine artery, which was immediately grasped and tied. After cutting away the growth in the uterosacral ligament, we brought the ends of the ligament together with catgut, made a purse-string suture over the area, and drew things together, leaving the site of the nodule perfectly smooth. We then attached the fundus to the anterior abdominal wall with one plain and two chromicized catgut sutures just to hold the uterus up in position for a month or two and give it a chance to diminish in size. We feared there might be a low grade infection and consequently did not attempt to shorten the round ligaments. We removed the appendix, which was small, but the meso-appendix showed scars of old trouble. The patient was discharged June 12, 1919.

September 22 the patient looked very much better. The uterus was in perfect position, and there was no thickening anywhere in the pelvis.

Examination of Specimen (Gyn. Path. No. 25042).—It was noted at the time of operation that this nodule was 1.5 cm. in diameter. On section it is found to be composed of non-striped muscle and fibrous tissue, and embedded in this are one or more minute discrete myomas. This nodule also contains a small amount of adipose tissue. The myomatous and

fibrous tissue tend to spread out into the surrounding fat. Scattered throughout the diffuse myoma are numerous glands (Fig. 40) lined with one layer of cylindrical epithelium. A few of the glands occur singly and lie in direct contact with the muscle. They tend, however, to occur in groups and are surrounded by the characteristic stroma. Some of the dilated glands contain fresh blood, others débris and exfoliated epithelial cells, which have swollen up and become spherical and contain yellowish-brown pigment,—the remnant of old menstrual blood.

This is a well defined example of adenomyoma of the utero-sacral ligament.

ADENOMYOMA OF THE SIGMOID FLEXURE

In February, 1918, Dr. Thomas E. Neill, of Washington, D. C., referred to me a patient, aged 26, complaining of most excruciating menstrual periods. Since April, 1917, she had had diarrhea, and with the beginning of each period she would have definite intestinal spasms three or four times a day. These would last two days and they would occur just at the time the patient went to stool. In September she was put on a milk-and-egg diet. Her digestion was very much upset, and she became constipated. During the last three or four periods she had had pain in the lower bowel commencing about twenty-four hours before the period. She also had some bleeding from the bowel and had spasmodic contraction of the lower bowel causing nausea and retching.

On vaginal examination I found a hard, slightly nodular and raised area in the vaginal vault directly behind the cervix. It was evident that this tumor contained several small cysts.

At operation we found, in addition to the adenomyoma of the rectovaginal septum, an independent growth in the sigmoid near the pelvic brim. This presented the typical appearance of carcinoma, and I at

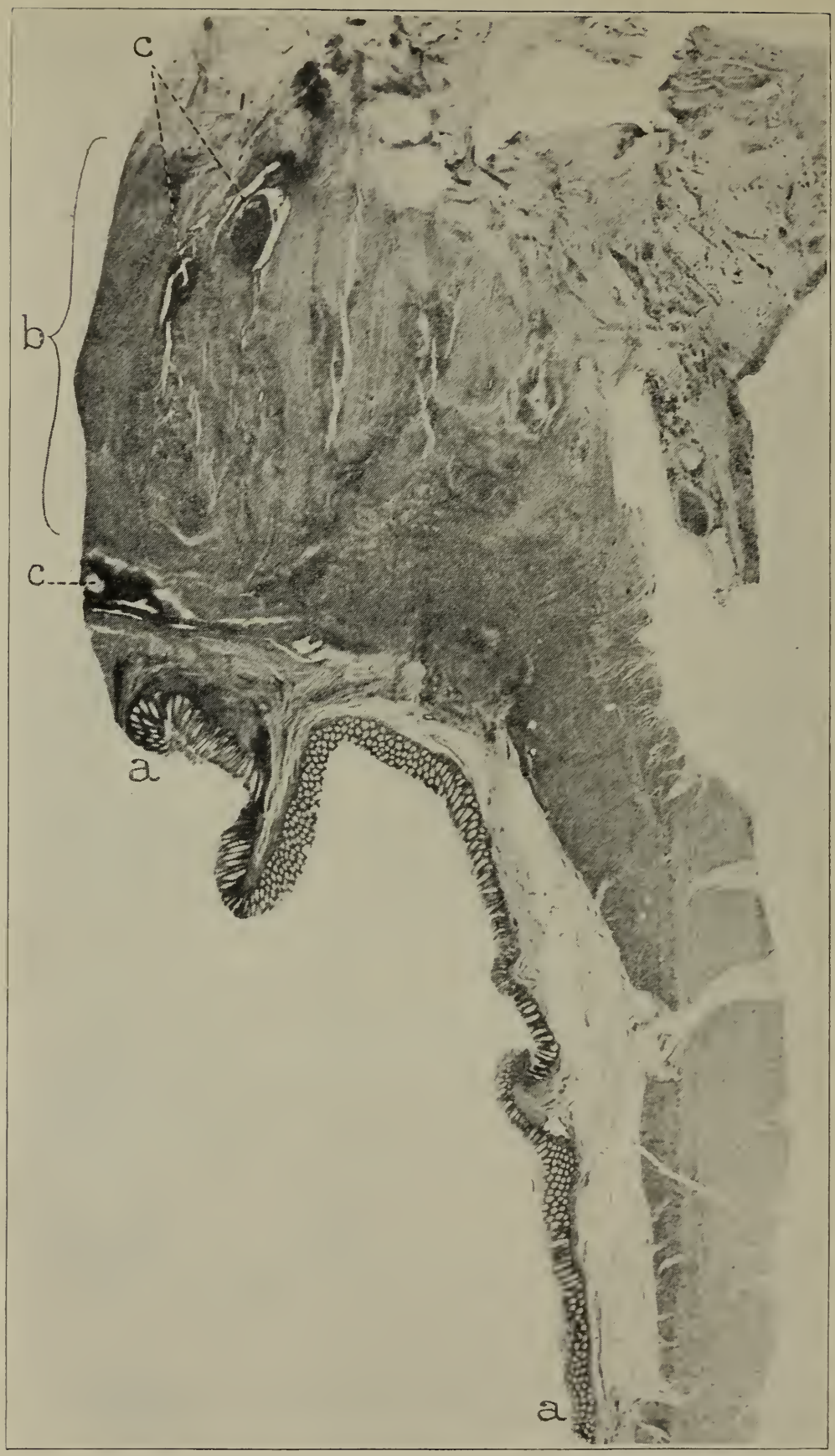

Fig. 43 (Case 16).—Adenomyoma of the sigmoid flexure totally independent of a coexisting adenomyoma of the recto-vaginal septum. This is a photomicrograph of a section taken from the sigmoid growth seen in Figure 42. The rectal mucosa, a, is perfectly normal. At b the underlying muscular walls are greatly thickened. Scattered throughout the muscular tissue were uterine glands surrounded by the characteristic stroma. The tissue was unusually brittle, and it was impossible to obtain thin sections. Nevertheless, at c we can recognize glands and stroma in the muscle.

once carried my hand up to the liver to see if there were any metastases. None being present, I thought there might possibly be some relationship between the adenomyoma of the septum and that near the pelvic brim. As the patient's condition was not very good, we just loosened up the sigmoid and drew it down extraperitoneally, hoping to remove it at a second operation a few days later. Unfortunately, the patient developed a streptococcus peritonitis and died. At necropsy it was found that the sigmoid growth was a typical adenomyoma and that there was not the slightest trace of cancer.

This case is of such interest that I shall report it in detail.

Case 16 (Septum Case 19).—*Adenomyoma of the recto-vaginal septum with an independent adenomyoma in the sigmoid flexure near the pelvic brim, clinically closely simulating a carcinoma of the sigmoid and markedly narrowing the lumen of the bowel.* (Figs. 41, 42, and 43.)

History (Gyn. No. 23764, Gyn. Path. No. 23891).—Mrs. G. S., aged 26, was referred to me by Dr. Thomas E. Neill, of Washington, on February 11, 1918. Her menses began at 13. When 14 they occurred every three weeks. She was dilated and curetted when 16, and was gradually having more comfortable periods. The flow now lasted three and four days; formerly it lasted from ten days to two weeks. She had also had severe headaches, but these had been diminishing.

Since April, 1917, she had had diarrhea. With the beginning of each period she would have definite intestinal spasms three or four times a day. These would last for two days and they would occur just at the time when the patient went to stool. In September the patient was put on a milk-and-egg diet. Her digestion was very much upset, and she was constipated. During the last three or four periods she had had pain in the lower bowel, commencing about twenty-four hours before the period. She had also had some bleeding from the bowel and had had spasmodic contraction of the lower bowel, causing nausea and retching. Her last period was two weeks before I saw her. She gave no history of any previous serious illness.

Examination.—On pelvic examination the outlet was found to be slightly relaxed, the cervix pointed forward. Just behind the cervix was a globular, somewhat lobulated mass, 2 cm. across and 2 cm. from above downward. It commenced directly behind the cervix. The body of the uterus itself was normal in size, in good position, and no thickening could be made out on either side.

On admission to the Johns Hopkins Hospital, the patient had a hemoglobin of 78 per cent. She was in rather poor condition, and I put her on forced nourishment for two weeks

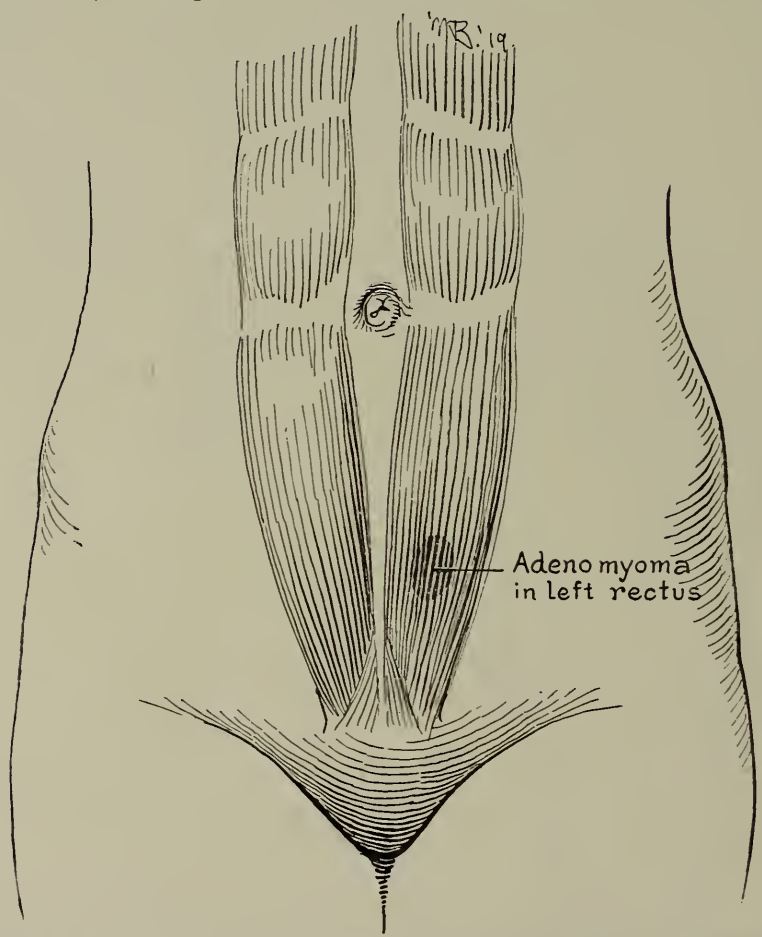

Fig. 44.—Adenomyoma in the left rectus muscle. Dr. Shallenberger's case. For the histologic picture, see Figures 45 and 46.

before attempting any abdominal procedure. Dr. M. Bloomfield examined the lungs and found evidence of old tuberculosis in the left apex.

Operation and Result.—April 4, 1918, we operated. First of all we grasped the posterior lip of the cervix and drew it

forward, put a retractor on posteriorly and then one on the right. We were then enabled to see an oval area, about 2.5 by 2 cm., directly behind the cervix. (Fig. 41.) This was slightly nodular, and in the center of some of the nodules was a shiny condition, indicating that at such points a small cyst existed. One or two of these were bluish-black in color, and there was absolutely no doubt that we were dealing with

Fig. 45.—Adenomyoma in the left rectus muscle. For the location of the tumor, see Figure 44. The nodule consisted of nonstriped muscle and fibrous tissue, and scattered throughout it were areas of typical uterine mucosa.

an adenomyoma of the rectovaginal septum. The edge of the growth was slightly raised, probably 1 mm. from the surface of the vaginal mucosa. We made an incision posterior to the

cervix, separated the cervix from the vagina, and then on the right side we cut the vaginal mucosa near the growth and loosened it up as much as possible. We then packed the vagina tightly with gauze and made a median abdominal incision. The right tube and ovary were removed in order that we might get into the right broad ligament satisfactorily. We dissected out the right ureter, cut the right uterine artery, and then separated the bladder peritoneum from the anterior surface of the uterus to a point slightly beyond the median line. We gradually loosened up the growth in the right broad liga-



Fig. 46.—Adenomyoma in the left rectus muscle. For the location of the tumor, see Figure 44. Scattered throughout the myoma are areas of normal uterine mucosa.

ment from the peritoneum on the right side of the rectum for a short distance and then cut the vaginal mucosa around it so that we finally had the uterus shoved over to the left side and a button of the vaginal mucosa containing the growth still left attached to the rectum. (Fig. 42.) We had partly closed the vagina after pulling the rectal growth down into it when we noticed a constriction about six inches above where the rectal growth had been. Whether the growth in the

upper part of the sigmoid was carcinoma or not it was impossible to tell. After examining the pelvic glands and also the liver and finding no evidence of metastases nor any enlarged lymph glands, I came to the conclusion that this might be another adenomyoma, although I had never seen one in such a position. We cut the peritoneum on either side of the sigmoid up as high as the pelvic brim, and loosened up the rectum as far as possible without interfering with its blood supply. We then pushed the sigmoid well down into the pelvis and drew the pelvic peritoneum over to the pelvic brim so we could wall off this area of the sigmoid. When we had finished the operation, the sigmoid had been pushed down extraperitoneally. A drain was left in the lower angle of the incision down behind the uterus. The patient was in fair condition.

Fig. 47 (Case 17).—Adenomyoma of the umbilicus. Dr. Guthrie's case. Projecting from the umbilical depression is a small tumor. This was 1.5 cm. long. On section it is seen to contain several small cysts. Some of them are yellowish brown in character. For the low power picture, see Figure 48. For the higher magnifications, Figure 49.

We hoped at a later date to draw the bowel out through the vagina and perform an end-to-end anastomsis if possible. To have done anything more at the time would undoubtedly have caused the death of the patient.

For the first twenty-four hours the patient did fairly well, but the next day she commenced to vomit a small amount of greenish fluid. There was a good deal of abdominal distension.

On March 7 the patient was delirious, vomited frequently, and was very restless, tossing from side to side. On March 8, at 3:30 P. M., I performed an enterostomy, thinking there might be intestinal obstruction. The bowel was relatively smooth, but there was some infection low down in the pelvis. The patient died at 9 P. M.

Necropsy Findings.—A definite peritonitis existed. The rectovaginal growth consisted of typical adenomyomatous tissue, and the tumor that projected in the sigmoid near the pelvic brim and markedly constricted the lumen of the bowel also consisted of characteristic adenomyomatous tissue. (Fig. 43.)

Cuthbert Lockeyer,[5] in his excellent book on "Fibroids and Allied Tumors," gives us the best résumé of the literature on adenomyoma. In it he refers at length to an interesting case reported by Robert Meyer.[6] On referring to Meyer's article I found that the patient was 45 years of age, and that Professor Mackanrodt had performed a resection in 1907 as the patient had signs of stenosis of the bowel.

The specimen consisted of a segment of the bowel 8 cm. in length. The bowel lumen over an area 1.5 cm. long was markedly narrowed, there being just a slit-like opening. The mesocolon at this point and also the overlying bowel mucosa were markedly thickened. In the mesocolon between the layer of fat and the muscular wall of the sigmoid was an irregular fan-like connective-tissue tumor, diffuse in character and strongly suggesting an adenomyoma. The tumor projected into the bowel and produced a folding of the overlying mucous membrane.

On histological examination the mucous membrane of the bowel over the tumor folds was found to have practically disappeared, the surface consisting of

5. Lockeyer, Cuthbert: Fibroids and Allied Tumors, New York, The Macmillan Company, 1917.

6. Meyer, Robert: Ueber entzündliche heteroptope Epithelwucherungen im weiblichen Genitalgebiete und über eine bis in die Wurzel des Mesocolon ausgedehnte benigne Wucherung des Darmepithels, Virchows Arch. f. path Ant., clxxxxv, p. 487, 1919.

granulation tissue. The tumor consisted of adenomyomatous tissue.

Meyer's pictures leave no doubt that he was dealing with an adenomyoma of the sigmoid, an adenomyoma of a type resembling in nearly every particular that found in the uterus. This is the first case of this character of which I have found any record. It was clearly described in Cuthbert Lockyer's recent publication.

On October 24, 1919, I received a most interesting letter from my friend, Dr. G. Brown Miller, of Washington, D. C., the contents of which have a definite bearing on the association of adenomyoma of the rectovaginal septum with secondary adenomyoma in the sigmoid.

Mrs. P., aged 36, with no children, came to see Dr. Miller on June 26, 1919, complaining of profuse, prolonged, and painful menstruation, pain in the pelvis, and pain on defecation. She had recently lost a good deal of weight, but was still well nourished although somewhat anemic.

Vaginal examination showed the cervix to be large and hard, and a small polypoid tumor was protruding from the os. In the upper part of the posterior vaginal vault was an irregular, hard, nodular tumor mass the size of a walnut. It was intimately connected with the cervix, rectum and broad ligament. The rectal mucosa over the tumor was intact, but was intimately adherent to the mass. The uterus was retroverted and moderately enlarged. A diagnosis of adenomyoma of the rectovaginal septum was made.

The patient was sent to the Columbia Hospital and was operated on a few days later. I was assisted by Dr. Neill. When more carefully examined, immediately before operation, the nodules in the vaginal vault were seen to contain small bluish cysts the size of a pea.

On opening the abdomen the first thing which attracted one's attention was a mass the size of a large lemon which was situated in the upper part of the rectum or lower sigmoid. This seemed to encircle the lumen of the bowel. The patient gave no history of hemorrhage from the bowel or of bloody stools. A total hysterectomy was performed. It was a difficult operation on account of the fixation of the uterus. In

attempting to separate the growth from the rectum, an opening was made in the bowel, after which the whole involvement of the rectum by the tumor was cut away and the rectum was sutured.

Fig. 48 (Case 17).—Adenomyoma of the umbilicus. This is a low power picture of the umbilical tumor seen in Figure 47. The surface is covered with normal skin. Scattered everywhere throughout the tumor are glands, many of them cystic, and not a few surrounded by a definite stroma that stains rather deeply. For the higher power, see Figure 49.

No attempt was made to resect the growth in the sigmoid. The patient left the table in bad condition. Her pulse was rapid, and she was much shocked. She improved, and the next day was much better. I left town the following day and was hopeful that she might recover, but learned from Dr. Neill that about eight or nine days after the operation she apparently developed peritonitis and soon died.

Mahle and MacCarty[7] report a very interesting case of adenomyoma of the sigmoid observed in the Mayo Clinic:

Case 4.—The adenomyoma of the sigmoid occurred in a patient, aged 31, who had been married eleven years and pregnant once. She had had an appendectomy, salpingectomy, and partial oöphorectomy performed elsewhere. At that time she was told that she had a tumor of the lower bowel which would become a cancer. She presented herself at the clinic because of this tumor. Röntgen ray of the colon, and a proctosigmoidoscopic examination proved negative.

At operation a tumor mass was found encircling the sigmoid, involving a segment of the bowel 4 cm. in length. The sigmoid and the bladder were adherent to a mass around the uterus. Twelve centimeters of sigmoid were removed as well as "tarry" cysts of both ovaries.

Histological examination of the sigmoid growth showed the characteristic picture of adenomyoma. Mahle and MacCarty refer to an adenomyoma of the sigmoid observed by Leitch.

Further studies will undoubtedly bring to light other cases, and it is highly probable that some cases heretofore considered to have been cancer were as a matter of fact adenomyomas.

ADENOMYOMA OF THE RECTUS MUSCLE

These growths are exceedingly rare. Dr. William F. Shallenberger, of Atlanta, kindly sent me a résumé of the history of his case on November 8, 1919.

7. Mahle, A. E., and MacCarty, W. C.: Ectopic Adenomyoma of Uterine Type (A Report of Ten Cases), J. Lab. & Clin. M., v, p. 221, January, 1920.

History.—Mrs. C. E. D., aged 34, had been married more than ten years. Nine and a half years ago she had an abortion. Curettage was performed for retained membrane, and the dilator passed through the retroflexed uterus at the cervical uterine junction. The body of the uterus was torn half loose from the cervix before the accident was discovered. The patient evidenced considerable shock, was rushed to the hospital, the abdomen was opened, and the damage repaired.

Dr. Shallenberger also learned that the patient had a second pregnancy eight years ago. She went to term and had a normal labor, but following labor a hematoma developed in the left broad ligament and vaginal wall. This had to be opened through the vagina. The patient's health has been very good since the last labor, aside from a slight attack of cystitis three years ago and a streptococcic infection of the foot six months ago.

The menstrual history was normal in every way.

Present Illness.—Three days ago the patient noticed a little soreness in the lower abdomen just to the left of the lower angle of the abdominal scar. (Fig. 44.) On feeling this area she noticed a small tender swelling. She thought that a hernia was developing.

On inspection there was a slight fulness just to the left of the midline and slightly above the symphysis. On palpation a small firm nodule can be felt apparently in the belly of the rectus muscle. This did not seem to be associated with the scar of the incision, and there was no impulse on coughing or straining, and the nodule did not increase in size when the patient stood. Dr. Shallenberger thought he was dealing with a hernia or with a dermoid tumor of the rectus muscle.

Treatment.—The patient was put to bed, and an ice-cap was placed over the lower abdomen. The pain and soreness were not relieved, and the nodule apparently increased somewhat in size during the next four days. Dr. Shallenberger then decided to remove the nodule. The entire lower end of the left rectus was removed. The tumor was about 2.5 to 3 cm. in length, about 1.5 cm. in breadth, and 1.5 cm. thick. It had no definite capsule.

On cutting into the tumor Dr. Shallenberger found that it presented a dark-grayish mottled appearance and that it was firm and fibrous in character.

The operation was performed eleven months ago, and the patient made an uneventful recovery.

Sections from this growth sent to me by Dr. Shallenberger consist of non-striped muscle. Scattered throughout this are areas of characteristic uterine stroma containing normal appearing uterine glands. (Figs. 45 and 46.) The cavities of some of the glands contain blood, and in the stroma at some points is brown pigment.

Dr. Shallenberger's tumor is, without doubt, an adenomyoma occurring in the left rectus muscle. It is the first one of this character that I have ever heard of. From its location it could not for a moment be confused with adenomyoma of the round ligament, which, although it presents exactly the same histological picture, is usually situated at or near the external or the internal ring.

Mahl and MacCarty[7] record two cases of adenomyoma of the abdominal wall:

Case 2.—This patient, aged 30, complained of a tender lump, of two years' duration, in the lower abdominal wall, under a previous laparotomy scar. The lump was painful at the time of menstruation.

On examination a palpable mass, 3 cm. in diameter, was found beneath the lower end of a median laparotomy scar; this was hard, nodular, and painful to touch. It was apparently not attached to the uterus and, clinically, was thought to be a fibrous tumor in a previous laparotomy wound.

At operation the mass was removed; it extended through the abdominal muscles and was attached to the left tube about 4 cm. from the uterine horn.

Case 3.—This patient, aged 46, had had a ventral suspension performed several years before and had been pregnant nine times, the last pregnancy occurring ten years before. She complained of lumps in the abdominal wall, which she had noticed for the last year. These lumps have not grown noticeably larger, but were always painful following menstruation.

On examination, a mass was found in the suprapubic region, apparently in the abdominal wall, movable with it, and possibly connected with the fundus of the uterus. Clinically, it was thought to be a fibrous growth, attached to the abdominal wall on a previously ventrosuspended uterus.

At operation, the fundus of the uterus was found attached to the abdominal wall. The tumor, 8 cm. in diameter, was situated to the right of the midline and extended down to the right side of the uterus. It was solid, with glandular, cystic areas filled with black pigment. Because of its extension into the retroperitoneal tissue, and apparent inoperability, only a piece of tissue, 6 cm. in diameter, was excised for diagnosis.

ADENOMYOMA OF THE UMBILICUS

From time to time a small thickening has been noted at the umbilicus in women during the child-bearing period. In some of these cases, the tumor has increased in size perceptibly at the menstrual period, and in a few there has been a discharge of blood from the umbilicus at the period. Occasionally, small bluish-black cysts have been noted in the tumor.

Adenomyomas of the umbilicus are always small. On histologic examination, they are found covered over with normal skin. They consist of fibrous tissue and non-striped muscle, and scattered throughout this are islands of typical uterine mucosa. When the history is characteristic, the diagnosis can be made with ease.

It is not necessary for me to discuss this subject in detail, as I have devoted an entire chapter to adenomyomas of this region in my book on the umbilicus.

Removal of the umbilicus is all that is essential in these cases.

I shall report briefly on the specimens of two cases of adenomyomas that have recently been sent to me for examination.

CASE 17.—*Adenomyoma of the umbilicus* (Figs. 47, 48, and 49).

History.—The specimen was sent me by Dr. Donald Guthrie of the Robert Packer Hospital, Sayre, Pa., in March, 1919. Dr. Guthrie says:

Fig. 49 (Case 17).—Adenomyoma of the umbilicus. This section is from the umbilical nodule seen in Figure 47. In the center of the field is typical uterine mucosa. Some of the glands are dilated.

"The patient is 46 years of age. She has had two children—the youngest 16 years of age. Menstruation has been regular. The patient has experienced severe pain around the umbilicus at the menstrual period. She has noticed this for two years, and at this time discovered an enlargement of the umbilicus. She never has had any discharge from it. At the menstrual period when the umbilicus was paining her, the patient experienced some inflammatory symptoms of the bladder. She has become very nervous and fearful that she has a cancer."

Fig. 50 (Case 18).—Adenomyoma of the umbilicus. The specimen was sent me by Dr. Lester Adams. The overlying skin is normal. The tumor is sharply circumscribed, has a whorled appearance, and has scattered throughout it cystic spaces and dark areas, some of them with glands in their centers. For the histologic picture, see Figure 51.

Dr. Guthrie sent me the specimen shortly after its removal.

Examination of Specimen (Gyn. Path. No. 24792).—The specimen consists of the umbilicus and of the adjoining skin. The umbilical depression is filled with a small growth 1.5 cm. in diameter. (Fig. 47.) This on section appears firm,

but scattered throughout it are a few cystic spaces, some of them yellowish-brown—cancer was suspected clinically.

Histologic Examination.—The low-power picture is well shown in Figure 48. The free surface is covered with normal squamous epithelium. The greater part of the tumor is made up of colonies of glands embedded in a definite stroma. Quite a number of the glands are dilated and filled with grayish or brownish material. Here and there is a perfectly definite miniature uterine cavity.

With a higher power it is seen that the matrix of the tumor is made up of connective tissue with bundles of non-striped muscle scattered liberally throughout it. Everywhere throughout the tumor are glands. Some are minute and lie in direct contact with the muscle; others are larger and embedded in a rarefied stroma. Many occur in groups and are embedded in a stroma identical with that of the uterine mucosa. (Fig. 49.) This mucosa is in some places so arranged that miniature uterine cavities occur. Some of the gland cavities are filled with blood, and here and there throughout the stroma of the growth are areas of yellowish-brown pigment—the remnants of old menstrual blood. One could not wish for a more beautiful example of an adenomyoma of the umbilicus.

Case 18.—*Adenomyoma of the umbilicus* (Figs. 50 and 51).

History.—This specimen was sent me by Dr. Lester Adams of the Eastern Maine General Hospital, Bangor, Me. M. G., aged 37, was under care of Dr. Hunt. An umbilicus growth was removed on Nov. 8, 1916. About a year before the operation she had noticed pain at the umbilicus at the menstrual period, but at no other time. There was some increase in size of the umbilicus at the periods. Recently the pain and tenderness in the umbilical region had increased markedly.

Examination of Specimen (Gyn. Path. No. 22657).—M. G. The specimen consists of a growth, 1.3 cm. in diameter, occupying the umbilical region. On section it is very dense, but at two points are small cysts, the larger being 2 mm. in diameter.

On histologic examination, the overlying skin is found to be normal. (Fig. 50.) The tumor growth is made up of non-striped muscle and fibrous tissue. Scattered throughout the tumor are large numbers of glands. Some occur singly and lie in direct contact with the muscle. The majority, however, occur in groups and are separated from the muscle by a defi-



Fig. 51 (Case 18).—Adenomyoma of the umbilicus. The overlying skin is normal. Some of the glands are partially surrounded by a definite stroma, others lie in contact with the myomatous tissue. For the low power picture, see Figure 5.

nite stroma. (Fig. 51.) This at some points is rarefied, but in other places is identical with that of the uterine mucosa. In at least one place is a miniature uterine cavity. Some of the glands are filled with blood, others with exfoliated epithelium and débris. In the outlying portions of the tumor are colonies of sweat glands.

This is another example of adenomyoma of the umbilicus.

SUMMARY

From the foregoing, we have seen that adenomyomas, consisting of a matrix of non-striped muscle and fibrous tissue with typical uterine mucosa scattered throughout, are to be found in the uterus, rectovaginal septum, tubes, round ligaments, utero-ovarian ligaments, uterosacral ligaments, sigmoid flexure, rectus muscle and umbilicus, and that we occasionally find large quantities of normal uterine mucosa in the ovary. Adenomyomas form one of the most interesting groups of tumors that we have to deal with in the female pelvis.

DISCUSSION

Dr. H. H. Sherk (Pasadena, Calif.): I would like to ask Dr. Cullen whether the menopause comes on late or not, or whether the operation delays the menopause.

Dr. Cullen: Our operations have been done during the child-bearing period, consequently I cannot satisfactorily answer Dr. Sherk's question. I have reported one case, however, where a supravaginal hysterectomy had been done and where the tubes and ovaries had been removed, thus producing the artificial menopause. In this case the adenomyoma of the rectovaginal septum continued to spread, and when the patient came under my obesrvation some two years later removal of the growth was impossible, and the patient promptly succumbed.

Where the entire uterus has been removed and a portion of the growth left attached to the anterior surface of the rectum, radium seems to have held the growth in check.

TREATMENT OF FRACTURE OF THE NECK OF THE FEMUR IN THE AGED.

CHARLES D. LOCKWOOD, M.D.

PASADENA, CALIFORNIA

Extreme pessimism still seems to dominate the medical profession in the treatment of fracture of the femur in old people. One can easily convince himself of this attitude of mind by walking through the wards of any large general hospital and observing the large number of old people lying helplessly in bed with a poorly applied Buck's extension, the broken limb almost in a straight line with reference to the pelvis, with some indifferently applied sand-bags supporting the limb. This pessimistic attitude of mind is further reflected in current articles advocating no treatment or only such as will minimize the dangers incident to old age, such as hypostatic pneumonia.

The wretched results obtained as a result of these methods, or lack of rational effort to obtain union, are only what might be expected. My own experience with these cases, while not extensive, has convinced me that a large percentage of these old people can be given useful limbs with firm bony union.

In order to secure this it is necessary to pay the most painstaking care to every detail of the treatment and to recognize certain definite principles governing the healing of bones. These principles are as follows:

1. *Anatomic.*—The frequent occurrence of non-union in fractures of the neck of the femur, not only in the aged, but also in young adults, is probably due to peculiarities of circulation in this location. The blood supply of the neck of the femur is entirely dif-

ferent from that of the shaft of the bone. In the shafts of all long bones we can trace a definite arterial branch, known as the nutrient artery. Moreover, in the development of long bones definite channels are formed between the lamellæ of bone,—that is, the haversian canals,—and by means of these the entire bony structure is richly supplied with blood. Not so, however, in the neck and head of the femur. There are no definite nutrient vessels to these structures. They derive their nourishment from the periosteum and ligatmentum teres. Numerous small vessels push in from the periosteum, and these are the sole blood supply of the neck of the femur.

Fractures resulting in extensive laceration or stripping of the periosteum are likely to fail of union even in young adults, and in the old with feeble circulation non-union is the rule. In fractures near the head there is rapid absorption of the neck because of the limited blood supply coming from the periosteum. Fractures near the trochanter, on the other hand, have a better blood supply, as this structure has its own nutrient vessels, and union is more likely to result without absorption of the neck. These latter observations were made by Murphy in a paper read before this Association some years ago; but so far as I can discover, no investigation has ever emphasized the importance of the peculiar blood supply of the neck of the femur as a cause of non-union. With the aid of Professor F. H. White, professor of Anatomy at the University of Southern California, I am making an embryologic study of the circulation in the neck of the femur, and a report of this work will be given a later date.

2. *Physiologic considerations.*—The more accurate the approximation of the fragments in fractures the less exudate and callus there will be, and the more

rapid the healing process. Failure of bony contact will often cause non-union in the long bones at any age; it is almost sure to result in non-union in the neck of the femur in old people. Moreover, failure of the blood supply in one fragment will result in failure of reaction on its part and result in non-union.

3. *Mechanical considerations.*—In fractures of the neck of the femur the surgeon has no control over the proximal fragment,—that is, the head of the femur; but he has absolute control over the distal fragment, and by traction and abduction he can bring the fragments into perfect alignment. In conformity with these principles the treatment of fractures of the neck of the femur involves: (a) Reduction by means of extreme abduction and extension: This may be accomplished either by Buck's extension in bed, over a period of two or three days, or by means of anesthesia with immediate reduction. The former method is preferable in old peopde, as it allows time for muscular relaxation and recovery from shock. (b) Artificial impaction: This is an essential part of the treatment as demonstrated by Cotton. It affords immediate bony contact and insures an adequate blood supply for union. With the patient under anesthesia, the limb is placed in extreme abduction, and strong traction with slight internal rotation applied. The great trochanter, protected by two layers of heavy felt, is struck three or four swinging blows with a large wooden mallet. A light plaster-of-paris cast is applied from below the knee to the waist-line and including the sound limb to the knee. The anesthesia lasts only five or ten minutes, and there is no shock to the patient. (c) After-care: The patient is placed upon a fracture-bed equipped with a special frame and elevating device, enabling the nurse to raise the patient with ease, to bathe him, attend to the bowels, and change the bedding. The cast may be removed as

early as the eighth week, but, if well borne, it should be left on for twelve weeks. By the end of the fourth month, the patient is up and about on crutches and bearing some weight on the broken leg.

I have treated these fractures successfully by this method in people of seventy years of age, and all are walking and perfectly well.

I shall report one case and show slides illustrating the progress of the case.

REPORT OF CASE

Mrs. K., age 74, a rather frail woman, fell while alighting from an automobile, striking her right hip against the curb stone. She was immediately brought to the Pasadena Hospital, where the treatment outlined above was instituted. In the fourth week of convalesence, she had an acute exacerbation of an old gall-bladder infection, due apparently to pressure of the cast at the waist-line. This caused much anxiety for a few days and necessitated the removal of the cast. It soon subsided and the patient made a rapid and satisfactory recovery. She walked into my office six months after injury with only a slight limp.

DISCUSSION

Dr. John P. Lord (Omaha, Neb.): As a medical student I was introduced to the treatment of fractures of the neck of the femur by my preceptor, Dr. C. C. Hunt, who was the partner of Dr. Phillips, of Dixon, Ill., who was the real originator of the Ruth-Maxwell method. I mention this to tell you that my attention was early directed to the subject, and I have come up along through these years, nearly forty, and have tried the various means of treatment of fractures of the neck of the femur. I evolved methods of treatment which enabled me to secure union by bone in persons over eighty years of age with shortening of less than one-half inch, many of them one-quarter inch. But when Whitman devised his method I decided that my methods were too laborious and required too much team-work, and that there were other disadvantages. It seems to me that there is noth-

ing to be desired if we follow the Whitman method; therefore I would recommend that general surgeons review the chapter written by Whitman on the treatment of fractures of the neck of the femur.

I take issue with the suggestion made by Dr. Lockwood when he speaks of using Buck's extension for the reduction of the shortening. It is most desirable to reduce these fractures at the earliest possible moment. When reduced, they are free from pain, and you never have any trouble with them thereafter. There is no readjustment of the dressing; a fracture bed is desirable though not essential, and the abduction position is altogether advantageous. You may then roll these patients about; it does not hurt them. You can put them on their sides, you can turn them over onto their faces, and you can have them sitting up in bed on the third day. If I may illustrate: The abducted limb is made to fall outside of the bed and rest on a chair, and the patient sits on the edge of the bed. It is desirable to change the position of old persons of eighty or ninety by rolling them around in this way which can be done without any pain. This abducted position aids and facilitates the care of the patient. There is not the same difficulty that there is when a limb is dressed in the straight position. These patients improve rapidly; they get about on crutches very much earlier, and a cast in the abducted position may be removed at the end of eight weeks, and another cast with less abduction put on simply to protect the limb, and the knee may be released, when motion is begun in the knee to guard against stiffness. It seems to me that there is nothing to be desired over the Whitman dressing. I think it is very far superior to any other treatment, and we are deluding ourselves when we undertake to improve upon it.

Dr. W. W. Richardson (Los Angeles, Calif.): I have always been very much interested in discussions on the treatment of fractures of the neck of the femur. There is no more comparison between a well-impacted fracture of the neck of the femur, with little deformity, and a loose subcapital fracture with great deformity, than there is between two varieties of fracture of the tibia or of the femur, and they must require different methods of treatment.

Dr. Lockwood in his cases reported has shown the beauty of treating a loose subcapital fracture of the neck of the femur by artificial impaction; but in the position shown in

the last picture, where impaction is good, there is no necessity for such treatment. There is no need for a plaster-of-Paris cast nor a Buck's extension, or for any other method of reduction when the fracture is well reduced and in good position.

We all see, especially in old people, impacted fractures of the neck of the femur which do not require reduction; then why reduce them or immobilize them?

Many years ago, thirty or forty years, Lucas Championniere, of Paris, used massage and mobilization in impacted fractures of the neck of the femur, and the advantage of that proceedure in old people is very apparent.

Some ten or fifteen years ago I began using that method of treatment, and it has been eminently satisfactory. We are able to get these old people up in a week; we get them around and comfortable with perfect motion. They do not suffer from lying in bed for a great length of time, and the final results are excellent, and they have not been even discommoded by the treatment.

As an illustration, only recently a young lady, thirty-one years of age, fell with her baby in her arms. She sustained a beautiful impacted fracture of the subcapital variety; there was practically no deformity. I put her in a Whitman cast because she was an important patient. I did not like to vary from the regular recognized treatment. It was insufferable, not from the cast, but from a back condition which she had had. The next day I removed it and treated her by massage and mobilization all the way through, showing the nurse how to do it. She came out with a perfect result. She was up at the end of two weeks, walking around on crutches; she went to the theatre and did everything she wished. She was not discommoded except that she used crutches for five months. Since then she has been able to walk perfectly. This is not a single instance. I have treated a considerable number of them at the County Hospital in Los Angeles, and it has become the recognized method of treatment in my clinic in old people. While I have not had perfect results in every case by any means, the results have been so satisfactory that it has made the treatment in my mind the most ideal treatment for impacted fractures of the neck of the femur.

Dr. F. G. Nifong (Columbia, Mo.): I am somewhat surprised that some of the members of the Western Surgical

Association do not yet know how to treat fractures of the neck of the femur. In dealing with impacted fractures of the neck of the femur in old people you had better let the fracture alone; put them on crutches, and get them moving about as quickly as possible. The science of geriatrics teaches us that the essential thing is to keep these old people up and moving about.

There are certain principles to be observed in the treatment of fractures of the neck of the femur and in fact of the entire femur. These principles, in the order of their importance, are, first, extension. Extension and counter-extension will overcome all muscle resistance and soon reduce the fracture without immediate reduction and fixation. The femur just naturally falls into its proper place when the great fascia lata is stretched, and there is no need for various side pulls and bracings. The second principle, and really a sequence of extension, is fixation or the "setting" of the limb. This is accomplished by various postures of the limb, such as is done in Whitman's abduction, by flexion, by suspension, and such like measures. Abduction is especially applicable in fractures of the neck of the femur. In old people the angle of the neck is less obtuse, and a certain amount of abduction is necessary to coapt the bones. The third principle, of scarcely less importance than the first, is the matter of mobility. It is a matter of such consequence in the old that oftentimes it is best to disregard the fracture entirely if we wish to save the life. Mobility is the third important principle to observe in treating the fractures of the thigh in the aged.

It is a barbarous thing to encase the old people in plaster. It is not to be tolerated. It is both inhumane and bad surgery. It is inhumane and more than uncomfortable to treat young persons in such a manner. It is positively cruel to the aged.

What are we to do about it? If we have an impacted fracture in an old person who cannot be confined let him up and let him get out. If he can stand some confinement, with the maximum mobility that may be secured in bed, put him in a wire cradle suspension splint; do not incarcerate him in plaster. Everything that plaster can do can be obtained much better in the open splint, and in addition, we may have all the other factors so advantageous in securing recovery, the most important of which is the ability to move

about and sit up in bed. Let us remember that our ball and socket hip-joint will permit of the freest possible motion in all directions. With extension and counter-extension within this suspended splint there is no danger of failure in keeping the end of the bones coapted. In addition we have the leg in the open and the care of the soft parts under our eyes. Massage and *x*-ray examinations are easy, and the contour of the limb is always in view. Any amount of flexion or abduction is easily secured as may be indicated by *x*-ray examinations and the character of fracture.

Last winter a case came to me which was an impacted neck fracture in the beginning no doubt, but had become loosened. I had her three months afterwards. *X*-ray showed fracture of the neck. This case united perfectly without shortening after being in a Hodgen splint for nine weeks. She was immediately comfortable when the splint was applied with about thirty degrees abduction. She had a most happy and comfortable time throughout as she busied herself with all the feminine occupations that did not require walking about.

Dr. Grant: Did you have extension first?

Dr. Nifong: I did not have the case at first, but after the third month. She evidently had an impacted fracture at first, which later became loosened, and she could not walk when I saw her. The *x*-ray showed she had a fracture of the neck of the femur. She was placed in a Hodgen extension suspension splint with about thirty degrees abduction and physiological flexion at the knee.

Dr Lockwood (closing): I think we ought, first, to have a fairly definite idea as to what we are talking about. Everyone who has discussed the paper has spoken of impacted fracture, while my paper deals specifically with non-impacted fractures in old people.

Anyone who has had much experience in the treatment of fractures of the femur, knows that he does not need to do anything in an impacted fracture of the femur, especially in old people. I usually treat these artificial impactions without casts. In the case reported, a cast was applied, and was removed at the end of four weeks. The patient got a perfect result.

I defy any of the surgeons who have spoken to secure a larger percentage of good results in non-impacted fractures

in old people by the ordinary methods. Dr. Richardson, I believe, has obtained, at the Los Angeles County Hospital, as good results as anyone. I am familiar with his work. I have been treating fractures for twenty years and have treated them by the Whitman method, and in 50 per cent of my cases in old people I fail to get union.

In cases treated by artificial impaction as advocated in my paper, you can get union in 90 per cent of the cases instead of 50 per cent.

I know of two patients in our hospital, both of them having been in bed over twelve weeks with non-union. They were treated by average practitioners in the ordinary way. It is this class of cases that can be given firm union by artificial impaction.

We are investigating cases embryologically, and we expect to prove that we have not sufficient blood supply in the neck of the femur to secure union without accurate bony contact.

I treat fractures in young people in the same way as Dr. Richardson and Dr. Lord do,—by extreme abduction and a plaster-of-Paris cast,—and it is satisfactory, but not in old people.

SOME RARER FRACTURES—WITH LANTERN SLIDES*

EDWARD EVANS, M. D.

LA CROSSE, WISCONSIN

The title of my paper as it appears on the program is hardly correct. Most of the fractures are not rare. I felt like apologizing for taking your time about them until listening to the discussion of the two preceding papers, when it would appear that there is a great deal of ignorance as to the treatment of fractures and of even the apparently commonplace proper use of plaster of Paris. A paper to a body like this is justifiable only if it presents something new, or presents what may be an old subject in a new light. The lantern slides I show will be of value only in so far as they excite discussion. I would, therefore, ask those of you who are interested in fractures and in bone surgery to make notes that you may discuss and elucidate points brought out by the exhibition of these slides.

Fracture slides shown by Dr. Evans were as follows:

1. Fracture of scaphoid bone.

2. Fracture of scaphoid with dislocation of semilunar in each hand.

3, 4. Showing (a) slight and (b) a very severe fracture caused by kicking back of an automobile crank.

5. A split or fracture at the lower end of humerus, extending from the mid-joint surface upward for three inches, separating the internal condyle without displacement.

---

*Author's abstract of his paper.

6. Fracture of elbow with separation of articular surface below the condyles, elbow being ankylosed in mal-position.

7. Old supracondyloid fracture of humerus with ankylosis.

8. Result of excision.

9, 10, 11. Examples of fractures of scapula.

12, 13. Fractures of posterior tip of the astragalus, brought about by a weight falling on the instep with the foot in extreme plantar flexion. These are of interest because they may be confused with what may be a congenital condition. This small fragment is a separate bone, the so-called os trigonum.

14, 15, 16. Fracture of the os calcis, showing that the chief deformity consists not in the pulling upward of the posterior fragment by the tendo Achillis, this being prevented by the plantar fascia, but rather in the spreading apart of the bone and the destruction of the normal concavity of the os calcis by the wedge-like action of the astragalus.

17. Pathological fracture of the ankle,—Charcot's disease.

18, 19, 20, 21. Pathological fracture of the neck of the femur and shaft of the opposite femur without any undue violence; rarefaction of bones.

22. Pathological fracture of shaft of femur, suffered while walking.

23. Fracture of femur treated by open operation and two Parham bands.

24. Fracture of the neck of the femur with excellent position treated by Whitman's method.

CONCLUSIONS

1. Industrial injuries and employment liability insurance acts of various states have shown that it is

indispensable to take *x*-rays of injuries involving hands or feet, if any suggestion whatever of crushing or sprain exists, as fractures of the small bones of the hands and feet are very frequent, often have very little displacement, and are frequently overlooked unless the *x*-ray is used.

2. Fractures of the bones of the hands and feet require careful and sufficiently prolonged immobilization, after careful reposition if there is displacement, to get good results.

3, 4. It is rather hard to get and maintain exact apposition of fractured parts and to prevent overlapping in fractures of the long bones, and consequently it is not certain if open reposition under favorable conditions—proper surgical and hospital facilities—should not be resorted to more frequently.

5. While the war has helped stimulate a much needed closer study and interest in the treatment of fractures, it is doubtful if we have learned much applicable to, or at least as yet applied in, our practice.

6. No satisfactory explanation has apparently as yet been made for the rarefaction of the bone leading to pathological fracture—no fundamental cause or causes sufficient to explain this condition.

DISCUSSION

Dr. Joseph F. Smith (Wausau, Wis.): I want to say a word or two about fracture of the scaphoid. A few years ago I had occasion to present a paper on this subject before this Association at the St. Louis meeting. At that time I had looked up the subject and found that the general opinion was that union in this fracture was rare, even when treated early, and that excision of the proximal fragment was practically the treatment of choice. This fracture is frequently overlooked and is of great importance from the standpoint of industrial insurance. Just recently I saw a patient who had sustained an injury to the wrist, and his case had been reported as one of tuberculosis of the wrist joint following

an injury, which, of course, from an insurance standpoint, would mean permanent disability. Careful study of the case for some weeks and several *x*-ray pictures threw some doubt on this diagnosis, and we finally decided it was an old fracture of the scaphoid bone. Excision of the proximal fragment of the scaphoid resulted in a perfect cure, and the man returned to work without any disability.

Dr. C. E. Tennant (Denver, Colo.): While not bearing directly on the subject, I have frequently been impressed with a simple method of caring for fracture of the clavicle. It is a rather novel one and has only more recently been reported. It consists of the use of a short barrel stave across the back, with a nail at each end, and a figure-of-eight bandage with thorough padding under the axilla. This permits of frequent change of dressing, with mobility of the arms but immobility of the clavicle and shoulder, and, consequently, no disability of the patient.

Dr. C. W. Hopkins (Chicago, Ill.): I was glad to hear Dr. Evans remarks regarding the Parham-Martin band. There has been much discussion regarding this foreign material, or hardware, as it is sometimes called, in the treatment of fractures; however, there are times when we have to deal with a certain class of fractures in which we are fortunate in securing and maintaining position by any means. The fracture just described by Dr. Evans is one of them. A fracture of this character, on account of the obliquity and manipulation, may cause much damage to the soft tissues with possible injury to the larger blood-vessels, which may slough, or be damaged to such an extent that aneurysm follows, and we all know what that usually means.

There has been much discussion regarding the degree of possible damage to the bone that may be caused by the use of the Parham-Martin band on account of pressure. Some years ago I came to the conclusion that this was brought about by the use of a single band and by the efforts of the surgeon to secure too perfect coaptation of the fragments by using too much pressure in applying it. Another explanation for the temptation to draw the bands down too tightly was the possibility of buckling of the fragments in the application of the plaster cast and subsequent manipulation. It is easy enough to see how such a procedure could cause necrosis. I know of one instance where a large section of bone had to be removed on this account. After hearing

of these cases, and before I got into trouble, it occurred to me that it would be far better to use two bands on this type of fracture, which could be applied with very little additional trouble or additional trauma to the soft parts, neither of them to be drawn down very tightly, but at the same time maintaining the position of the fragments without undue pressure. At the same time I decided that the metal bands could be made of a much more pliable and softer material, but with the same degree of tensil strength, which would allow a careful drawing down without pressure upon the bone or damage to the periosteum, and I had my bands constructed accordingly and at the same time made an improvement in the instrument. I am glad to say that while I have used a great many bands in cases of this kind, since adopting this procedure, I have succeeded in obtaining and maintaining perfect coaptation without any trouble following, and have not had to remove a single one. Some of these bands have been in place for over five years and the patients are doing all kinds of work with a perfect leg and without any trouble or inconvenience from the bands.

One advantage in the use of the bands is that you do not have to drill the bone and introduce screws or plates which so often cause pressure necrosis, and, not infrequently, long delay in union or perhaps non-union, or a long drawn out period of suppuration; this we know frequently takes many months to clear up before a bone graft operation can be performed.

Union is usually very rapid, necessitating a less extensive callus and early calcification on account of the easy application and the perfect coaptation. The recovery is uneventful and early and without shortening or deformity, and in spite of what has been said against the bands I expect to continue their use in a certain class of fractures.

Dr. W. H. Magie (Duluth, Minn.): I would like to ask Dr. Evans whether he has had any trouble with abnormal callus forming around these bands. I have been using these bands for some years and have had two cases, one in particular where I used two bands on the humerus, with enormous formation of callus, which gave a great deal of trouble.

Dr. Evans (closing): My experience with the use of these bands has not been large, but I have never seen any trouble from the use of them. The essential thing is, as Dr. Hopkins has said, to put on two bands. It is irrational to put

on one only. Again, these bands should not be drawn tight. In this particular instance I followed up the case by the use of the *x*-ray, and it shows very little callus. There was practically no irritation, and the man recovered very rapidly. Before he left the hospital he had a perfectly movable knee, which we do not have often, except after a long time, when we treat one of these fractures near the knee in the old-fashioned way.

DISLOCATION OF THE TARSAL SCAPHOID: DOUBLE FRACTURE OF THE ISCHIATIC TUBEROSITIES

WILLARD D. HAINES, M. D.

CINCINNATI, OHIO

DISLOCATION OF THE TARSAL SCAPHOID

Fracture following violence is much more common than is dislocation of the bones of the foot. This is a splendid illustration of the law of Colles, who observed that, when the tensile strength of bone and ligament was put to the test, the bone usually gave way first. But, despite the great strength of the ligaments which bind the component bones of the foot, dislocations of individual bones may and do take place, although fractures of these spongy bones occur much more frequently than do dislocations.

Dislocation of the tarsal scaphoid alone is the rarest of all varieties of foot bone dislocations. The security of position possessed by this bone is due to its anatomical relation with other bones, ligamentous, muscular and fascial supports plus the usual mechanical lines which force requisite in the production of these dislocations usually travels. Although the navicular is not the true keystone of the anteroposterior arch of the foot, it is accurately buttressed by a semicircular facet over the head of the astragalus and firmly held in position by the dorsal, plantar, and interosseous ligaments. The tibials, peronei, flexor hallucis, flexor digitorum, and plantar fascia all lend additional support in maintaining this bone in position.

The inferior calcaneoscaphoid ligament is one of the chief anatomical factors in maintaining the arch by

supporting the head of the astragalus through holding the scaphoid in place; the function of this ligament receives additional support from the tibialis posticus, the tendon of which splits into numerous fasciculi, which are attached to most of the metatarsal bones. The muscles concerned in supporting the articulations of the scaphoid are supplied by the anterior tibial nerve, hence injury to this nerve or impairment of function of the mucles supplied by it will favor destruction of the arch.

Dislocation of the scaphoid alone may be regarded as a traumatic flat-foot, and we may perhaps gain a clearer insight into the pathology of this dislocation by a brief reference to the mechanism in the production of the deformity so frequently encountered, called "flat-foot." Indeed, one very competent clinician has said that tarsal scaphoid dislocation never occurs in a foot possessing a natural arch. In flat-foot we have eversion and abduction of the foot with loss of both the transverse and longitudinal arches in consequence of the unsupported head of the astragalus, which is permitted to point downward.

Owing to the lack of support from the articular surface of the scaphoid, the foot turns outward, increasing the inner side length of the foot and broadening its plantar surface. This condition is due to weakening of the tibialis anticus and posticus, the peroneus longus, and yielding of the internal, lateral, calcaneo-astragaloid ligaments and plantar fascia. This is essentially what occurs in scaphoidal displacements with this difference: one is of slow development and may be unaccompanied by pain; the other is sudden in origin, very painful, and has lacerated ligaments and the additional dorsal surface deformity incident to the misplaced scaphoid.

In a lax condition of the calcaneoscaphoid ligament in the standing posture the weight is supported by the

Fig. 1.—Showing dislocation of scaphoid.

tibial muscles, and, although the ligaments limit the range of joint-motion, the normal strain of weight-bearing falls on the tibial group of muscles. The range of motion in the articular surface of the scaphoid under normal conditions is slight and limited to movement of the inner margin of the foot up and down; turning in and out of the toes has been erroneously attributed to mobility in this joint, but these motions are dependent chiefly upon the hip-joint for their accomplishment. From the intimate relation, with its anatomical surroundings, it becomes apparent that one of three routes is open for uncomplicated luxation of the scaphoid: dorsal, mesial, and plantar. Outward dislocation of this bone would necessarily involve displacement of the cuboid and perhaps also the astragalus and calcaneus. Rupture of the interosseous ligaments and rupture or separation of the fibers of the calcaneoscaphoid ligament must take place before the bone may be completely detached from its position in inward dislocations, and it is this separation of the fibres of the calcaneoscaphoid ligament and the tendency on the part of the scaphoid to rotate on its horizontal or vertical axis which render replacement of the bone difficult or impossible without open operation.

Failure to reduce luxation and the necessity of excising the bone have been encountered in the open operation in a number of instances.

Malgaigne refers to scaphoid dislocation as a middle tarsal dislocation and Sir Astley Cooper in his work on dislocations gives a very accurate picture of the deformity in his report of a case of luxation of the navicular bone.

Stimson, 1910 edition, records 5 cases forward on dorsum; 1 inward and forward, 1 inward, 2 downward, and 1 outward on dorsum; 2 reduced without operation, 2 with operation, 3 unreduced, 1 excised, and 2 amputations for gangrene.

Speed, 1916, "Fractures and Dislocations," collected the records of 43 cases of dislocation of the scaphoid; to this list he added the record of a personal case, making a total of 44 cases, which he classifies as follows: luxation by navicular cuneiform separations, 15; talonavicular separations, 17; and total separation, 10; his own case added to the last class, making a total of 11 cases wherein the bone was wholly displaced from its normal moorings.

The *Index Medicus* contains no record of scaphoid dislocation since 1916.

Case No. 15333.—(Referred by Dr. R. H. Whallon.) Male, age 51 years, laborer, well developed, 5 ft. 11 in., weight 180 lbs. While hoisting a tank with an I-beam and chain, the chain slipped, causing the I-beam to be displaced, whereupon the beam and chain, the combined weight of which was estimated to be 600 to 700 pounds, fell and, in falling, struck the patient a glancing blow on the left side of the head and chest, forcing the patient into a sitting posture with part of the apparatus resting on his left foot.

When admitted to the hospital the foot and ankle were considerably swollen, and the patient showed a mild degree of shock and complained of severe pain present in the left chest and ankle.

Examination revealed, in addition to multiple bruises and abrasions, fracture of the seventh, eight, and ninth ribs on the left side and a protuberance on the inner side of the left foot in front of the head of the astragalus. Crepitus was distinctly felt while examining the foot. An attempt at reduction by the attending physician had partially reduced the deformity.

The clinical diagnosis was fracture of the seventh, eighth, and ninth ribs; dislocation of the tarsal scaphoid; fracture of one, undetermined, of the bones of the foot.

X-ray examination at this time by Dr. Lange confirmed the presence of a dislocated scaphoid (Fig. 1), but failed to reveal a fracture. The general appearance of the foot was that of an exaggerated flat-foot. The head of the astragalus could be distinctly felt on the surface of the foot, the toes were

directed outward, the outer side of the foot was turned upward.

The protruding scaphoid was firmly fixed and could not be easily moved, neither would the hollow space recently occupied by the bone admit the tip of the examining finger although a sense of absence of bone at the plantar site could be detected. The foot and ankle were steeped in hot saline solution for twenty-four hours, at which time the patient was etherized with a view to reducing the luxation. The scaphoid could now be moved for a short distance in all directions, the outward direction of the toes and other deformities could also be increased by slight manipulation. With the leg and thigh in a position of full flexion, the heel of the injured foot was placed on the margin of the foot of the operating table and firmly fixed by an assistant. A leather belt three-quarters of an inch in width was thrown over the foot by a second assistant with a view to forming a fulcrum pressing against the displaced bone.

Seizing the heel with the left hand and the toes with the right, the injured foot was forced into a position of extreme extension, and while in this position the assistant made firm traction on both ends of the belt in an upward aud outward direction. The foot was now quickly placed in extreme flexion, at which time the scaphoid slipped back into place with an audible thud. When the foot was released and the belt pressure removed, partial dislocation followed, which was easily corrected by pressure with the thumbs. The foot was dressed in a position of semiflexion and slight inversion, with a plaster-of-Paris case, which extended well up to the knee.

The dressing was continued for six weeks, and the patient was permitted to get out of bed and on crutches at the end of ten days.

Although the patient could not use the injured foot until after the reduction of the luxation had been accomplished, the functional result is very good, three months having elapsed since the receipt of the injury.

DOUBLE FRACTURE OF THE ISCHIATIC TUBEROSITIES

Viewed from an anatomical point the pelvis is the strongest bony cavity in the body. Force requisite in

the production of fracture of the pelvic bones and continuance of the force after the bone gives way is relatively so frequent that extensive damage to the urethra, bladder, intestine, and blood-vessels is the rule rather than the exception in this type of fracture. Search of the literature did not reveal the record of an uncomplicated case of fracture of the tuberosity of the ischium, although some of the text-book authors speak of the possibility of such fractures. Fracture of the tuberosity of the ischium is an unusual occurrence and might be said to be the most infrequent variety of pelvic fractures.

Case Record No. 13842.—A farmer, aged 33 years, seen in consultation with Dr. B. K. Menefee, was thrown to the ground from a wagon, landing squarely upon his buttocks, in which position he was dragged some distance. When admitted to the hospital the patient was suffering from a certain amount of shock and complained of an agonizing pain in the region of the anus. Under full anesthesia the finger in the rectum encountered a hard mass in either ischiorectal fossa. The mass in the right fossa was easily moved by placing the opposing thumb of the examining hand over the site of the ischiatic tuberosity and making a lateral motion. This manipulation elicited crepitus.

The mass on the left side was larger, more firmly fixed, and required more force in moving it, but this movement also elimited crepitus.

There was a considerable displacement of the fragments inward toward the rectum and upward toward the tip of the coccyx. So far as could be determined the rectal wall had escaped injury and the urine was free from blood.

It was concluded that there was present a double fracture of the ischiatic tuberosities. The fragments were replaced in apparently complete alignment by the same method which had been employed in examining the patient. A plaster-of-Paris spica was applied and retained for six weeks. Radiographic examination showed simple fracture of the right tuberosity, but the fracture line on the left side, after separating the tuberosity, continued through the ramus and body of the bone into the wall of the acetabulum.

Complete functional recovery followed and there is no apparent deformity.

Dr. Herman E. Pearse (Kansas City, Mo.): The interesting paper presented by Dr. Haines leaves very little room for discussion on the treatment of these cases reported, excepting to compliment him on the method by which he pulled the bones in place.

The paper brings out one point in regard to injuries, dislocations, and fractures, as well as the orthopedic injuries, from the use of the foot in so-called flat-foot. I would like to speak for a moment upon the condition we are all finding to exist in the human foot.

As the doctor pointed out carefully in the first part of his paper, when a man falls upon the foot, or receives an injury of the foot, if he is to be considered correctly during his lifetime, the ligaments will take the strain off of the foot while neither dislocated or broken.

Recent investigation of the school children of Kansas City showed 40 per cent of them had flat-foot, and with such a condition we can look for an increased number of dislocations and fractures of the tarsal bones.

The lesson we should take home from this paper is the necessity of more careful supervision of our patients in our public-health work.

The human race is standing too much upon the skeletal structures, and I was glad to hear Dr. Haines say the foot should support the weight of the arch by means of the anterior tibal muscles. I differ with him as to the condition which arises from changes at the hip. The foot has a double arch. There is a heavy anterior tibial muscle with its tendons which swing inside the instep, and that tibial muscle should hold up the arches.

The child who stands correctly bears his weight upon the outer side of the foot. To do this he can not "toe out" very well. Better that he have a forward pointing foot, even though he "toe in." But they must not allow the foot to swing out and the weight of the body to fall upon the bones of the arch. The body weight must fall upon the toes, heel, and outer edge of the foot. The arch must be held by the muscles of the leg.

Dr. Haines (closing): Dr. Pearse misunderstood that part of the paper wherein I called attention to the erroneous teaching of those who attribute turning inward and outward

of the toes and distal end of the foot to mobility of the scaphoid articulations.

Normally, there is but very slight motion between the scaphoid and the head of the astragalus or between the cuneiform bones and the scaphoid. Clinical recognition of the scaphoid dislocation is not difficult in the light of experience in dealing with the case reported in my paper, but how to set about reduction of the displaced bone gave me much concern. When the unusual case confronts one he is led into the bogs and fens of unwritten rules that will suggest themselves to the mind of the resourceful operator in dealing with surgical problems, but the interposition of torn ligaments, rotation of the displaced bone upon its axis, and numerous other imaginary difficulties rapidly passed through my mind while examining the patient.

With the details fully assembled for open operation in case of failure to reduce the luxation by manipulation, one feels a little embarrassed at such elaborate preparation after experiencing the simplicity and ease with which reduction had been accomplished in this case, and I was reminded, for the thousandth time in my clinical experience, of the forceful and comforting words of Madame De Stael who said, "The worst things never happen."

TUBERCULOSIS OF THE GREAT TROCHANTER OF THE FEMUR

Malvern B. Clopton, M. D.

ST. LOUIS, MISSOURI

Three cases of tuberculosis of the great trochanter of the femur have come under my observation in the last three years, and have presented certain points of similarity. As the condition is not frequently seen and has been confused with hip-joint disease, it deserves to be mentioned, because it is a condition that can be relieved by excision, while operation for tuberculosis of the hip ordinarily is not indicated.

The universal opinion, up to very recent years, has held that tuberculosis of the long bones begins in the epiphysis. This opinion has been amended by Stiles and Frazer that in certain bones the shaft (metaphysis) is the primary seat of tuberculosis. As far as I can learn, the profession in America hold to their original belief in the primary bone focus being practically always in the epiphysis, although admitting that a small number of cases begin in the metaphysis.

The great trochanter is developed as an epiphysis, which begins to ossify in the fourth year, and the attachment becomes complete about the eighteenth year. The late ossification and attachment may account for the fact that tuberculosis in this location has come to us as a disease of adolescence, the ages of our three cases being twenty-five, twenty-nine, and twenty-five, respectively, on admission, but the disease started at fifteen, twenty-two, and twenty-three years. In over 500 cases of tuberculosis of the skeleton in children, admitted to the Children's Hospital, we have never encountered a similar case. In 148 cases of tubercu-

losis of the bones and joints in adults, admitted to the Barnes Hospital, two of the above cases occurred. Terry and Allison, in an analysis of over 22,000 cases, found the hip-joint diseased in 31 per cent of the cases, and Hutchinson, in discussing injuries to the epiphysis, points to the relative instability of the body in the erect posture and the special liability of the growing regions of the bones to injury, and believes that tuberculosis subsequently and consequently develops in the traumatised parts. While weight-bearing makes the great risk to the epiphysis of the head of the femur, we must also bear in mind the fact that some of the strongest muscles, which maintain balance in the erect posture, are attached to the great trochanter, and through them this epiphysis is subject to constant stress. That this strain is at times great enough to cause a dislocation of the trochanter, shows that it is not an inconsiderable force. Its almost subcutaneous position would give occasion to numerous external traumas. It is, therefore, surprising that more cases of tuberculosis of the trochanter are not encountered.

The pathological changes are such as are usually found in red bone marrow, characterized by tubercles, giant-cell formation, fibrosis, and caseation, osteoporosis, and osteosclerosis, resulting in the destruction of part of the epiphysis. In two of our cases the process had spread into the soft tissues, forming abscesses. One of these abscesses extended over a big part of the outer side of the thigh beneath the fascia lata.

The clinical features can be shown best by giving abstracts of the histories of two of the cases:

K. C. E., Surg. No. 4011-4137, April, 1917, aged 25, male.

At the age of six had pneumonia and pleurisy and effusion. Effusion never drained, but was allowed to take care of itself.

Since then the patient has had no definite trouble of any sort. About ten years ago he became conscious of a limp or peculiarity in his gait, which has persisted. There is no pain to indicate any definite location of the trouble. He has engaged in the most active sports and has enjoyed excellent health. This winter he has been working hard, and playing most vigorous games,—notably, ice hockey. He had several very bad falls. Three months ago there was a slight increase in his lameness, and a swelling was noticed in the upper part of the thigh. This swelling was painless. Aspiration of the swelling gave pus containing a few white blood-cells. Cultures showed no organisms, but injections into a guinea-pig showed tuberculosis. He had had a slight fever for about a week before admission.

Examination showed a disproportion between the sides of the chest. The left side was very much smaller than the right. Breath sounds are distant, but are otherwise fairly normal.

The attitude in standing is rather peculiar. The pelvis is dropped down on the left, and the thigh is abducted, giving an appearance not unlike a sacro-iliac pose. There are no symptoms directed to either sacro-iliac joint. There is no muscle spasm on flexion of spine. Examination of the hip-joint shows no trouble in the joint, but there is limitation of motion on inward rotation and adduction. There is also marked atrophy of the buttocks over the gluteus minimus and maximus.

The *x*-ray shows a lesion of trochanter major. This has progressed since pictures were taken three months ago by another physician. The lesion seems to be entirely confined to the upper portion of the trochanter, which shows an irregular cavity above with slight hypertrophy of the outer surface.

The left limb is one inch shorter than the right. There is a collection in the outer side of the thigh in a pocket, which extends from the trochanter down to the middle third of the femur. This pocket can be distinctly brought out by changing position of patient. When the patient stands the lower part fills.

Red blood cells, 4,300,000.

White blood cells, 9,000.

Polymorphonuclear, 65 per cent.

Urine, negative.

Operation, May 4, 1917.—Morphine, atropin, nitrous oxide, and ether.

Incision and drainage of cold abscess.

Excision of great trochanter. Closure.

A lateral incision six inches long exposed the trochanter, and a cold abscess, which extended from the insertion of the tensor fasciæ latæ to the middle of the thigh, was evacuated. The outer surface of the trochanter was denuded over one square centimeter. Beneath this there was a cavity in the trochanter which contained grayish granulations. This cavity easily admitted the end of the finger. The trochanter was excised by chiseling until healthy bone was exposed. The fascia was sewed into the defect with fine catgut. The abscess cavity was wiped out thoroughly with gauze. The fascia was closed with fine catgut, and a cast was applied in abduction.

The wound remained healed until the tenth day, when a discharge began at lower end of wound. This continued slight in amount, evidently coming from the remains of the cold abscess beneath the fascias of the thigh. At the end of seven weeks the patient was allowed to walk using an apparatus that kept him abducted.

His improvement continued, and after three months he was actively engaging in sports and business, and has remained well. At present, except for a slight limp, which is hardly noticeable, he is well.

Pathological report No. 2,127. Tuberculosis of the bone and of soft parts. Mrs. Anna M., Surg. No. 7,575, August, 1919, aged 29, white female.

The patient came to Out-Patient Department on December 15, 1918, with pain in the left hip which was worse at night. At that time the findings were negative. Almost three years later she was admitted to the hospital with the same complaint. Her history was irrelative, except that when nine years old the left heel swelled and was incised and drained, pieces of bone for over a year coming out. It has been well since. There has been a slight cough, which was worse in the winter. Seven years before, pain began about the left hip, becoming worse at night. The pain was not continuous, but each subsequent attack has been worse. There have been two children born to her, one twenty months and another seven months ago. Since the birth of the last child the pain in the

hip has been worse, and the hip has become so sore that it hurts to lie on it. There is no pain in the joint, but a long walk will start up the pain.

Examination shows an area over the upper right lung which is suspicious of healed tuberculosis. There is a scar over the left os calcis, where there had been a discharging sinus. The left hip-joint is unimpaired except for a slight pain on forced adduction. Rotation, abduction, flexion, and extension are normal. Deep pressure over the great trochanter gives rise to deep pain. There is no redness or swelling.

Red blood cells, 4,500,000.

White blood cells, 9,500.

Hemoglobin, 70 per cent.

Temperature, normal.

The *x*-ray shows a slight lipping of the lower end of the epiphyseal line between the great trochanter and the shaft. Aside from this the findings are negative.

August 27, 1919, T. B. C. complement fixation test, positive. Wassermann, negative.

September 1, 1919. Tuberculin 1 mg. Reaction noted in increased pain in the region of the great trochanter.

September 4, 1919. Tuberculin 5 mg. Temperature reaction to 102.2°; pulse 130. Complains of pain over the left trochanter, very tender on pressure. Slight cough.

Operation, Sept. 18, 1919, under morphine, atropin, and ether.

Excision of the great trochanter left femur for tuberculosis.

Through an external incision the outer face of the trochanter was exposed. A small bone cavity filled with very cellular grayish material had broken through into the overlying tissues, making a sac, which resembled a chronically infected bursa. There was no evidence of tubercles. The trochanter was excised, and the overlying, invaded tissue cut away. The wound was closed with fine catgut for the buried suture and silk for the skin.

The wound healed kindly except for a slight discharge, which continued for about ten days.

The patient was discharged from the hospital at the end of the fourth week, walking on crutches, which were shortly discarded. She had no pain after the first few days following the operation, and has remained well the eight months since.

The third case was in a British soldier, who had served two years in the line. He came down to the base complaining of pain in his hip. When on light duty he did not complain, but heavy duty, such as long marches, incapacitated him. He showed none of the usual signs of hip-joint disease, limitation of motion, deformity, or muscle spasm, but deep pressure over the trochanter was painful.

The *x*-ray disclosed a focus in the trochanter major, and this was excised. The examination of microscopic section showed tuberculosis of the bone.

The points that I want to bring out are, that tuberculosis of the great trochanter is a condition met with after childhood; that it is not attended with marked symptoms; that pain about the trochanter is the chief complaint, and this is increased by use; and that tenderness of the diseased part is elicited by pressure. The diagnosis by the *x*-ray can be fairly definitely established. The absence of adductor-muscle spasm on moving the joint will rule out hip disease in the early stages, and the characteristic deformity of old hip disease is lacking. The condition should be treated by excision of the diseased trochanter.

FOR DISCUSSION SEE PAGE 189

TUBERCULOSIS OF THE JOINTS AND ROLLIER'S HELIOTHERAPY

GUSTAV SCHWYZER, M. D., F. A. C. S.

MINNEAPOLIS, MINNESOTA

We realize that a large amount of material should be the foundation for conclusions in such a vast subject as joint tuberculosis. It is, therefore, with some hesitancy that I bring before you my small amount of operative work on such cases; still some valuable deductions at times may come from a limited number of cases as we observe them in private practice.

The study of the different phases of tuberculous joints is so extensive that we can only touch upon the most important features.

Etiology.—The two main channels by which the human body becomes infected with tuberculosis are the lungs and the alimentary canal.

In children, Fraser has found 60 per cent of all the joint tuberculosis to be of bovine type, an infection directly traced to tuberculous cow's milk. The alimentary route in children, therefore, is predominant.

In adults the bovine infection becomes negligible. The tuberculous infection of the joints is here of more secondary nature; in the lungs we have to look for the probably primary focus.

Of less importance are the channels for tuberculous infection from the tonsils, from the pharyngeal mucous lining, and from infected gum tissue. They are the direct source of lymph-gland infection in the neck.

Joint tuberculosis is prevalent in the first two decades of life.

The question whether trauma is an etiological factor in the start of the disease has given rise to much dispute. Not only do we find almost constantly a minor trauma mentioned by the patient in the history of the sickness, but also experiments point to the fact that traumata, and surprisingly often light ones, have a distinct significance in the start of the disease. (Krause, Pietrzikowski, etc., cited by Fraser.) It is obvious that a previously dormant tuberculosis of a joint when exposed to injury may progress to an acute state.

The hip- and knee-joints are most frequently affected by tuberculosis; the elbow, ankle, wrist, and shoulder follow in frequency as enumerated.

Pathology.—There are two principal types of infections to be considered: one an invasion from a nearby bone-focus; the other through the capsule from a tuberculous focus in the neighborhood, especially tuberculous synovitis.

The most frequent is the infection of the joint from the side of the bone. Years ago Volkmann said that in children the tuberculous arthritis always starts from an osteitis, respectively osteomyelitis, and even Koenig in his monograph on coxitis avoids speaking of a primary and secondary synovitis. Still he admits that he has seen cases of simple tuberculous synovitis in children. The start of the arthritis is then overwhelmingly from a bone-focus. For some reason this focus may become walled-off by osteosclerosis.

We have observed such a case in the upper epiphysis of the tibia in a girl of sixteen. The *x*-rays showed us a well defined focus in the bone, of the size of a hazelnut. Early operation brought on a definite cure and the imminent joint tuberculosis was thereby prevented. The process in the bone during

fourteen years of observation has not recurred to date.

If contrary to this the process in the bone is of more acute, more violent character, this osteomyelitis spreads rapidly; great rarefaction of the bone takes place; the bone lamellæ become destroyed; are replaced by tuberculous granulations; and caseation and necrosis set in.

This can lead to a secreting fistula toward the outside, or the process can perforate into the joint. In the latter case, erosion and perforation of the cartilaginous covering of the bone follow, and the joint cavity has to surrender to the entering tuberculous infection.

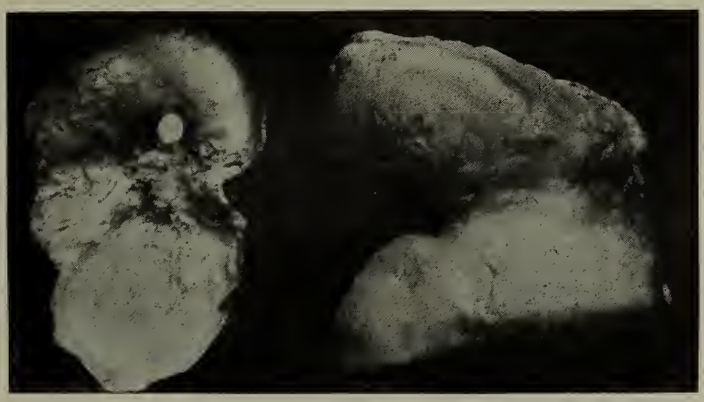

Fig. 1. Case 12. Resection of tuberculous knee-joint in Mrs. W., aged 58.

On the other hand, the primary tuberculous synovitis, also called synovitis fungosa granulosa (the white swelling or tumor albus), is of a more chronic character. It has a greater tendency to heal, especially in children.

Numerous, distinct tubercles form in the synovia, which is ultimately replaced by tuberculous granulations. In lighter form of infection, the joint contains a serous hydrops. (Koenig.) The fluid is yellowish and clear. Here conditions can remain unchanged for a long period of time. White flakes in

that hydrops are fibrinous deposits (hydrops fibrinosus). At times we find rice-bodies, probably originating from this fibrin.

In the tuberculous process the cartilage does not take an active part.

The peculiar white swelling, so characteristic in the knee- and elbow-joints that the diagnosis often can be made *prima vista,* is due to hyperplasia and infiltration involving not only the capsule, the ligaments, and the tendon sheaths, but also the subcutaneous tissue.

The tuberculous granulations can spread into the surrounding tissue outside of the joint proper. If they undergo caseous or purulent degeneration, cold abscesses or fistulæ will result. Such abscesses have become significant for the diagnosis, as in psoas abscess. If in coxitis we find an abscess at the groin and upward from it, the bone-focus lies in the acetabulum, while an abscess directly in front of the hip-joint tells us that the focus is in the femur.

For the knee the formation of bulky masses of fungous-granulation tissue on the capsule is a characteristic and outstanding feature for this joint. The elbow- and shoulder-joints are more frequently the seat of caries sicca. The hip-joint infection is characterized by a particularly great destruction of bone tissue, of the femur head, and of the acetabulum.

Our cases of joint tuberculosis were of a distinctly advanced character. Conservative treatment had failed to bring on a cure. We were compelled to do extensive arthrectomies and resections in all of our cases.

In every case the pre-operative diagnosis was established beyond a doubt. We make merely mention that radiography and at times the subcutaneous tuberculin test always allowed definite conclusions.

Fig. 2. Case 11. Resection of tuberculous knee-joint in Mr. A., aged 33.

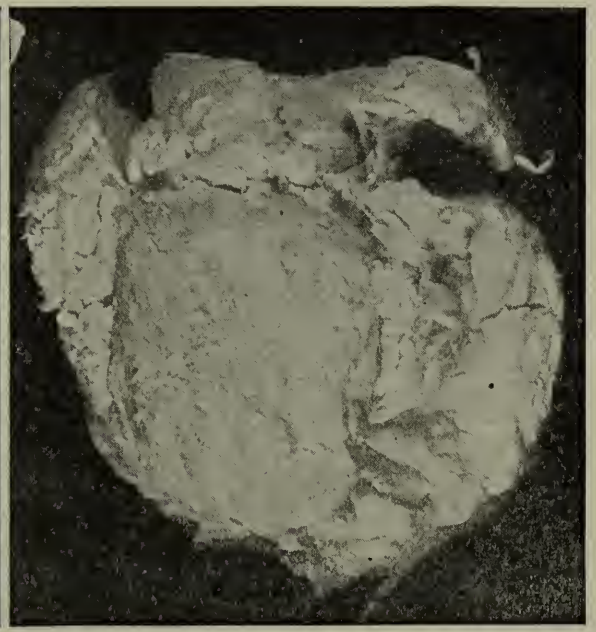

Fig. 3. Case 11. Knee-cap with tuberculous fungi.

TREATMENT IMMEDIATELY PRECEDING OPERATION

We are holding the view that a general preparatory treatment has to precede operations, regardless of the mode and length of time of the previous conservative treatment. By this we aim at an improvement of the resistance of the body in general, providing for fresh air and light; we encourage the patient's appetite as much as possible in order that a large amount of substantial food will be taken. In the majority of our cases Sahli's tuberculin treatment was given.[1] This preparatory period, extending from one week to two months, gives us a good chance for closer observation of the patient. We must obtain a very exact knowledge, especially of his lungs and kidneys,—and, furthermore, an exact temperature picture, which is of additional value for comparison later on. Very accurate notes should be taken, telling us as much as possible of the clinical pathology of the diseased joint. We must try to locate the bone-foci. We must thoroughly test the function of the joint actively and passively. In young people the examination is often hampered by lack of self-control or by involuntary muscular contraction. In these cases a general anesthesia for the examination is recommended. *X*-ray examination is, of course, indispensable.

PREPARATION FOR OPERATION

The preparation for operation has always been done with a view to attain an ideal asepsis. The field of operation is carefully shaved, and the covering skin surgically prepared the day previous to the operation. The patient arrives at the operating-room with an aseptic dressing covering a wide area.

1. We carefully followed his instructions, avoiding any elevation of temperature, which, in our estimation, can safely be done by using Sahli's tuberculin prepared in the hands of Dr. Beraneck, at Neuchatel.

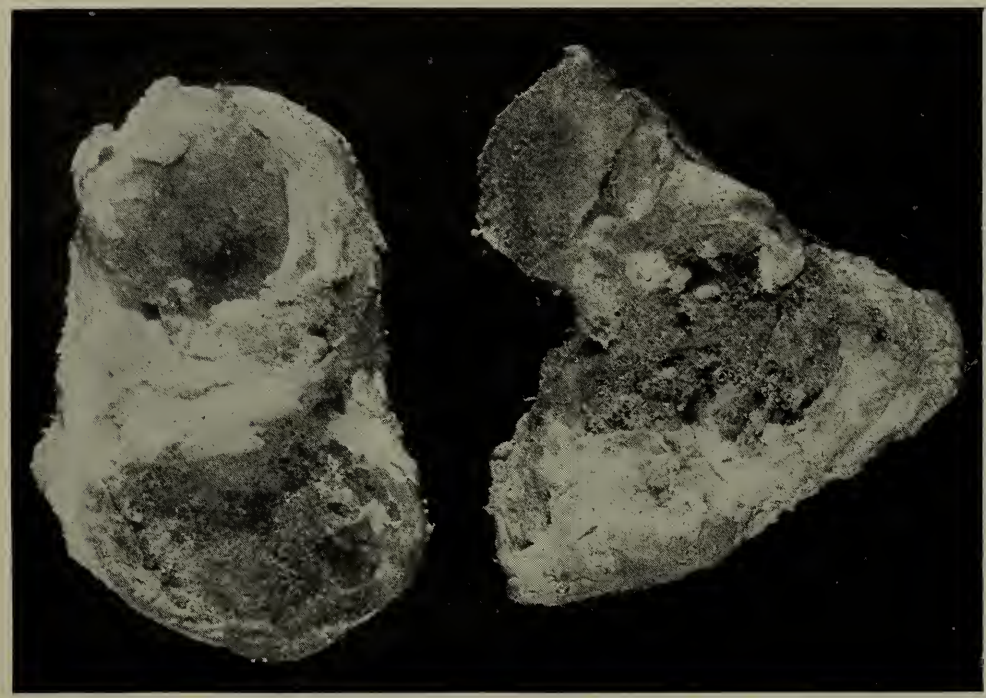

Fig. 4. Case 13. Resection of knee-joint for advanced tuberculosis in Mrs. A., aged 25.

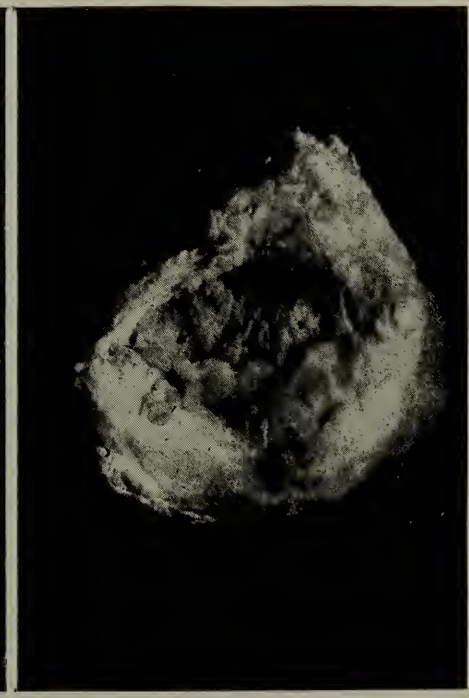

Fig. 5. Case 13. Eroded knee-cap.

It is our practice to operate upon such joints under Esmarch constriction wherever feasible. Only with this bloodless procedure under Esmarch are we able to differentiate between healthy and diseased tissues, particularly bone tissue.

OPERATIVE PROCEDURE

As to the methods of operating, incision and so on, we can briefly say that we generally followed Kocher's ways. We always were impressed that through his incisions good access could be gained to the entire diseased area, and it is most important that all the tuberculous tissue be carefully excised by exact dissection.

If the disease is confined purely to the synovial membrane of the joint, we limit our work entirely to the removal of this membrane, thus avoiding complete ankylosis; but, if the bone is involved, the bone ends are exposed by energetic dislocation. We strip back the healthy outer integuments and turn them back like the cuff of a sleeve. Now the diseased part of the bone is cleanly removed. If we aim at a complete ankylosis, a good apposition of the bones is imperative.

In every case we have used iodoform powder. Contrary to the general routine, we prepared the iodoform powder previously by boiling the same for half an hour in a 1:500 bichloride solution. This powder is rubbed into the entire wound surface, the bone, and the soft tissues. The superfluous loose part of it is washed away with saline solution. Thus we always have avoided dangerous degrees of iodoform intoxication.

In all our resections we drained the wound cavities with rubber tubes surrounded by washed-out iodoform gauze strips. Our buried suture material consisted of silk and linen. Silkworm-gut is the best material

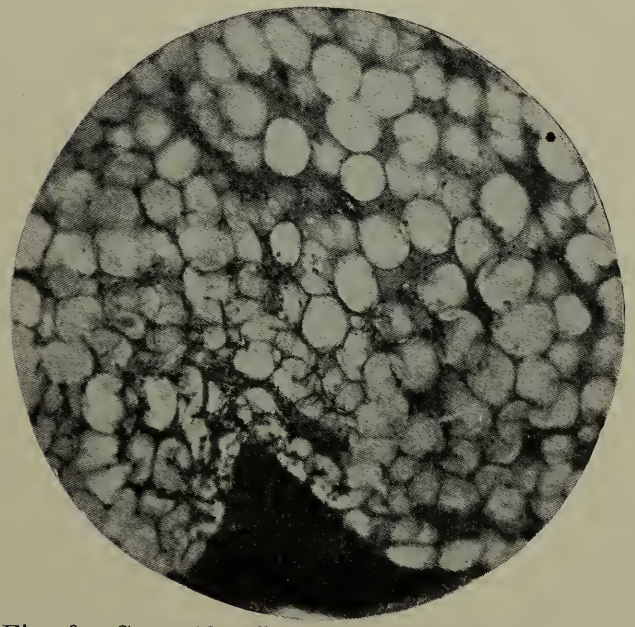

Fig. 6. Case 13. Leucocyte infiltration in superficial fat layer.

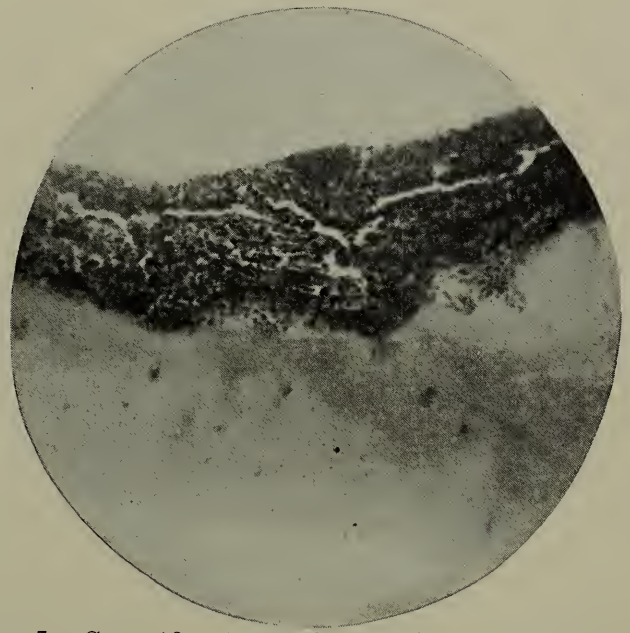

Fig. 7. Case 13. Area of necrotic cartilage.

for the surface. An abundant amount of absorbent gauze and cotton is used for dressing. A plaster-of-Paris cast is put on before the Esmarch bandage is released. The drains are removed through windows in the cast within a week.

Though the bleeding into the cast was often considerable, we never noticed any alarming hemorrhage. The first cast was always made quite heavy with the intention to leave it on from four to six weeks. After that time the wounds were closed, and in affections of the lower extremity the patient was allowed to leave the bed in a lighter cast. None of our hip or knee resections remained in bed longer than six weeks. The patient was sent home in the second cast with the advice to return in two to three months. A much shorter time is needed following operation on the upper extremities.

Fortunately, in all our cases we did not have to resort to amputation. Only one patient left with a fistula after a resection of the elbow-joint. A second resection, eleven months later, brought on a definite cure also in this case.

REVIEW OF THE CASES

Case 1. Mrs. Maud R., aged 24. Resection of right middle metacarpophalangeal joint and removal of the corresponding metacarpal bone. The patient insisted on keeping her middle finger on account of appearances and the result showed that this finger without any metacarpal bone back of it did not become an obstacle in the usefulness of the hand. Wound healing was prompt. A year later a tuberculous tendovaginitis developed on the dorsal side of wrist of same hand, was surgically treated. Since then (six and one-half years ago) there has been no recurrence of tuberculosis.

Case 2. Edward C., aged 20. Tuberculous wrist of the right hand. Resection. The family history is negative. A year before there was serious lung involvement with hemorrhages. The pulmonary condition is now quiescent; no fever.

Fig. 8. Case 13. Tuberculous osteitis, partial necrosis of bone tissue, giant cell.

Fig. 9. Case 13. Extensive bone necrosis.

Slight injury in form of a twist of the hand is mentioned as the beginning of the trouble. The function gradually became limited, and the hand slightly flexed. The wrist was swollen, extremely painful to touch, with no active movements; pressure on ends of ulnar and radial bones, and carpus is very painful. He is unable to close the hand or straighten the fingers; he is unable to hold a pen in the hand. There is no fistula.

Through a Langenbeck's dorsal incision the diseased carpus was removed, leaving only the pisiform and multangular major. The ends of the radial and ulnar bones were also removed on account of caries. A splint was applied with the hand in strong dorsal flexion. Recovery was uneventful. The patient was able to hold a pen in his hand when he left the hospital four weeks after operation. A splint was used for another six weeks. After this, the hand was in useful condition and was painless.

The patient contracted a cold six months later, and died from pulmonary hemorrhage.

Case 3. Mrs. Sarah L., aged 50, had a tuberculous elbow of the left arm. The family history reveals no tuberculosis. The patient was formerly a strong woman, the mother of ten children. In August, 1903, she wrenched her elbow in wringing out a heavy garment. Since then movement in the elbow has been limited. Eight months later, April, 1904, the patient suffered a second trauma. She fell striking her elbow against a fence-post. Three weeks later a discharging fistula developed at the outer side of the elbow. The fistula closed spontaneously a few weeks later. There was a gradual increase of pain, and more marked limitation of motion.

Status—In June, 1906, she presented a much thickened left elbow, with striking atrophy of the upper and forearm muscles. Elbow at right angle; fore-arm in pronation. There was a large fistula behind the inner epicondyle of the humerus. There was only seven degrees active motion in the sense of flexion; about ten degrees active supination, quite painful. Pressure on the olecranon and the head of the radius was very painful; less on epicondyles of humerus.

A typical resection of the elbow through Kocher's outer incision was done July 4, 1906. There were abundant tuberculous granulations in the joint; the cartilage of the three bones was mostly destroyed. The bone-ends were carious. An irregular sequestrum of hazelnut size was re-

moved from the middle of the epiphysis of the humerus. The bones were wired. Healing with outer and inner fistula. Result: a flail-joint.

A second resection was done eleven months later, June 11, 1907. There were no more granulations in the joint, but caries of humerus and fore-arm bones. Again the bones were wired. The wound healed perfectly, and has remained without fistula until today. She has an astonishingly useful joint, although still too loose. She does all her house and garden work, and feels very much benefited by the operation. She has gained twenty-five pounds.

Cases 4 and 5 are patients with resections of the ankle-joint. In Case 4, a girl aged 12, the immediate results on one side and six months later, on the other side were beyond reproach, but the girl died four months after the second operation, from meningitis.

Case 5. The other case of resection of the ankle-joint, is that of 14 year old boy. The result was more gratifying. Here we removed the entire astragalus, in addition to the epiphyseal ends of tibia and fibula. The young man was seen six years later, and, although limping somewhat on account of the shortening, he could walk freely without any pains.

Case 6. Viola G., aged 4, presented tuberculosis of the tarsometatarsal joints. Two fistulæ existed. The little girl was unable to step on her foot. Through two side incisions we gained access to the middle of foot, removed the ends of the astragalus and calcaneus and the entire middle foot, including the base of the metatarsal bones, thus bringing the front part of the foot in contact with the heel-bone, and the astragalus. The result was a striking one; not only did the wound heal without fistulæ, but the girl, who is now a young lady of 20, presented to us about a year ago a well-formed and useful foot, though of course shorter than the other. She walked without limping.

Cases 7, 8, and 9 had tuberculous coxitis. Within eight weeks after the operation they were all up and about on crutches. As they were city hospital cases, we were unable, unfortunately, to follow them up.

Case 7, a boy of 16, had an extensive synovitis and partial destruction of the femur head.

Case 8, a girl of 13, with a previous conservative treatment of over one year, had extensive bone destruction of the head of the femur and acetabulum; the latter perforated in two places. The patient was walking on crutches six weeks later.

Case 9, Tilda S., aged 8, had a negative family history. She was ill nearly two years. She was treated conservatively for seven months. As the case is of special interest, a somewhat detailed report follows:

She had a noticeable deformity of the right hip with a swelling above and behind. The right superior anterior spine was one inch lower than the left when the patient lay flat on her back. The right trochanter appeared flattened on account of the swelling. The right groin has a chain of swollen glands. Active movements in the hip-joint are absent. When lifted on her feet the child cries out in agony. Examination by rectum shows a very painful region of the acetabulum and some softening.

Examination under anesthesia: Rectal examination repeated. We recognize a distinct gland of the size of a peanut directly above the acetabulum. We find both trochanters in equal distance from the corresponding anterior spines. The right knee, somewhat stiffened, is easily loosened; the joint is otherwise normal. There is a slight pes equinus. In flexing the right femur we notice a bony crepitation. Flexion of the femur up to 90 degrees and full extension are possible; rotation to about 20 degrees; abduction 5 degrees; no adduction. All this is possible in narcosis. The leg is three centimeters shorter than the other.

Fresh air and tuberculin treatment for about six weeks, precedes the operation.

Operation, October 9, 1907.—Kocher's angular incision. An abscess in the gluteal region was found before incising the capsule (bursitis glueti maximi). After the capsule was opened, we found the inflamed synovial membrane thickened with granulations. The bone destruction was very marked. There was no cartilage anywhere; the socket seemed to be a good deal deeper than normal. In its middle we found a softened place of the size of a peanut, filled with granulations, evidently a perforation, which admitted the tip of the little finger. There was another smaller perforation at the lower border of the acetabulum. The ligamentum teres showed partial destruction, and was therefore removed. The synovial membrane, including the diseased capsule and all

the carious bone tissue of the acetabulum and head of femur, was carefully removed. Iodoform powder was rubbed into all the pockets, and its surplus washed away. Iodoform gauze drainage was placed in the perforation of the acetabulum, and drainage established in front of and behind the head of the femur. The wound was closed in the usual way. A plaster-of-Paris cast was placed from the knees upward, including the pelvis. Both legs were extended in abduction.

Nine weeks after the operation, although, of course, the patient has a stiff joint, she walks without crutches, without assistance, and without pain.

Cases 10, 11, 12, and 13 form a group of typical knee-joint tuberculous infections.

Case 10, Lizzie B., a girl aged 17, is especially characteristic for a tuberculous synovitis of the entire joint without involvement of the bones. As the case made an uneventful recovery, left the hospital in three weeks, remained well until now, that is for twenty years, and has retained a partial function of the knee-joint so that she walks practically without limping, it will prove to us that a primary synovial tuberculosis does exist and that here an arthrectomy with removal of the entire synovial membrane leaving the bones and cartilage intact can be of great advantage.

We proceeded as follows: Lateral, longitudinal incision, chiseling off the insertion of the patellar ligament with the tuberosity of the tibia and also detaching with a chisel the insertions of both lateral ligaments with the epicondyles, thus giving a perfect access to the joint. Contrary to the procedure of resection of the joint where the capsule is incised at the start, we removed the entire diseased capsule, as much as possible *in toto* starting on the outer side of the femur, and opening the joint cavity as late in the procedure as feasible. The entire capsule was thus dissected away. The menisci were removed, together with the capsule. But the cruciform ligaments were saved, requiring a careful dissection of the synovial membrane which was wrapped around these ligaments. In this way the result was a fibrous ankylosis of the joint with a partially preserved function.

Cases 11, 12, and 13 showed bone involvement of the tibia and femur, and required a resection of the epiphyseal ends.

Case 11. Alfred A., aged 33, was operated upon on August 4, 1910, for tuberculosis of the left knee. Healing took place

within four weeks. After this another lighter cast was applied for two more months. Perfect ankylosis resulted. We heard from the patient in 1917 and again now. Previous to the operation the man was unable to make a living on his farm, due to the severe pains in the knee. He now, after the operation, 9 years, writes that he does all his farmwork without the least discomfort.

Case 12, Mrs. Mary W., aged 58, was operated on on August 5, 1916, for tuberculosis of the left knee. The case is of interest because of her age. The infection had started after trauma. The bones were less diseased than in the previous case. Healing took place with perfect ankylosis. A report from her a year later was good and exceedingly cheerful.

Case 13, Mrs. Magnil A., aged 25, was operated on on December 6, 1917, for tuberculosis of the right knee. The sickness extended over many years. She came to us on crutches with the knee flexed, unable to step on the foot. The long standing of the disease probably explains the extensive destruction of both bones, more so than in any of our previously mentioned cases. As the patient was a frail individual with a positive family history and having had one child, we performed, four months later, the operation for sterilization. In a recent letter she states that she enjoys excellent health.

ROLLIER'S HELIOTHERAPY

European surgeons of late years have given Rollier's heliotherapeutic treatment for surgical tuberculosis due consideration. Men, like Bardenheuer, after personal inspection of the hospitals at Leysin, have become very enthusiastic about the treatment. De Quervain, in Berne, as a leader, advocates the view that heliotherapy applied in the sense of Rollier is taking the place of bloody operations for closed surgical tuberculosis.

We have learned that Rollier's treatment is being used, and apparently with success, at the J. N. Adam Memorial Hospital, at Perrysburg, New York.

For those who are less familiar with Rollier's sun-treatment, I will say that the sun-rays are combined with open-air treatment at an altitude of from 3,500 to 5,000 feet. I can only briefly state that the body of the patient is cautiously, that is very gradually, allowed to be influenced by the solar rays, as well as by the open air. It is astonishing how the body, which at first is exposed to the rays for only a few minutes a day, can stand, later on, the solar rays for hours. Complications of the skin, headaches, and tachycardia are cautiously avoided. The skin soon becomes tanned. It changes from a light brown to a deep copper color. It is characteristic that the dark-complected individual tans deeper and that his prognosis is better. The immobilization of the joints is done only when needed and then only by removable splints and extensions not interfering with the treatment.

The sun-rays show their beneficial influence within days, and the analgesic action is striking. Rollier's statistics show that uncomplicated, closed tuberculosis of the joints is definitely and permanently cured within two to three years with a *restitutio ad integrum.*

De Quervain says that the treatment with the alpine solar rays for surgical tuberculosis in the human has ceased to be an experiment.

Though Rollier speaks of an analgesic, a bactericidal, and a sclerogenetic action of the solar rays, a clear understanding of the theoretic side concerning the most important points of the sun-rays and their influence upon the human body has not as yet been reached. We do not know how deep the sun-rays enter into the human body, and we are left in the dark as to their action upon the tissue cell.

The sun-rays are divided into two classes: long waved and short waved ones. In the latter group belong the ultraviolet rays. This portion of the spec-

trum of the sunlight is the therapeutically active one. These rays are the cause of the pigmentation of the skin. They differ in action and influence in different altitudes. In the lower altitudes, contrary to the higher altitudes, these shorter waves (the ultraviolet ones) are principally absorbed by the denser atmosphere that contains more dust and moisture.

It remains for us to state that Rollier is earnestly attempting to create a scientific basis for the heliotherapy. As former assistant of Kocher he does not discredit the employment of operative procedures in the treatment of tuberculosis when such measures cannot be avoided. The difficulties he encounters are the same as ours,—the open tuberculosis brought on through negligence or ignorance. And if he decries opening tuberculous foci under any but the strictest aseptic conditions, we must heartily agree with him.

No doubt, it would be taking another great step ahead in the treatment of surgical tuberculosis to establish numerous institutions in our country where Rollier's sun-treatment could be used intelligently; but, not having the benefit of such institutions at the present time, we must face the situation as it lies before us today. Granted that we have the advantages of hospitals specializing in heliotherapy, there may always be cases which cannot spend a year and a half to three years in such institutions waiting for a definite cure. For these patients surgery may be preferable, as the ability to work with a painless limb outweighs for them the drawback resulting from an ankylosed joint.

FOR DISCUSSION SEE PAGE 189

TRAUMATIC OSTEOMYELITIS

Richard W. Corwin, M. D.

PUEBLO, COLORADO

When requested to present a paper at this meeting it was understood that it was not to exceed ten minutes.

Some of the slides shown are from war specimens in the Royal College of Surgeons Museum at London, England, which, through the kindness of Professor Arthur Keith, permission was given to photograph. The rest are from the Minnequa Hospital collection.

The only object of showing these slides is to call attention to at least one surgical difficulty, namely, that of preventing or promptly arresting osteomyelitis.

Case—Leg crushed beneath car wheels. Compound comminuted fracture of left tibia and fibula; complete laceration and detachment of all tendons at the lower third of leg.

Amputation was not permitted.

The wound was freely opened, and all suspicious tissue, soft and osseous, was removed.

The Carrel-Dakin treatment was applied until swab specimens were negative.

An autogenous bone-graft was inserted, and the wound closed and healed and was pronounced cured.

Ankylosis at ankle, of course, had taken place.

The laboratory reported "four plus," and specific treatment was continued.

Some months later infection reappeared. An *x*-ray picture revealed necrosis and cavities. The patient, realizing the uselessness of the foot, requested its amputation; amputation was performed and the stump healed promptly and satisfactorily.

Post-Mortem of Specimen. The graft which the *x*-ray showed prospered for a time. After infection reappeared the graft was absorbed at its middle portion. A cavity had

formed beneath in the soft parts, and within the lower fragment of the tibia a second cavity existed, which was probably the first, and where the infection was secreted and developed.

Every surgeon has unfortunate or, at least, unsatisfactory cases which he has treated skillfully, but, in spite of treatment, infection reappeared because of overlooking hidden infection or because of a focus of infection remote from the seat of injury, whether directly or indirectly connected with the injury, or because of disease for which injury is in no way responsible, or because of lowered vitality and resistance. Therefore, when a case has been received early, oprated on promptly, and surgically, and aseptic after-treatment skillfully given, yet infection again becomes active, is it not pertinent to ask—

Is there no means of preventing or promptly arresting traumatic osteomyelitis?

Is there no safe and sane prophylaxis that will destroy infection beyond the reach of the surgeon's knife or chisel?

Is there no possibility of such a prophylaxis being discovered?

Is there no help for the widow's son, even if wayward and even unfortunate enough to fall upon unfertile surgical soil?

An experiment: An interesting double compound fracture and osteomyelitis of the femur of a wild duck.

Middle third fractured at both ends.

Rotation of lower third 45 degrees.

Middle third over-riding and uniting upper and lower thirds.

Osteomyelitis at upper portion of middle third and lower portion of upper third.

Autogenous cure.

Treatment. Alkali lake water periodically applied.

DISCUSSION OF THE THREE PRECEDING PAPERS

Dr. William Jepson (Sioux City, Iowa): I desire to report one case of tuberculosis of the trochanter which came under my observation about sixteen days ago for the purpose of supporting the views presented by Dr. Clopton, and, furthermore, to indicate how the condition may be readily overlooked. Briefly, the case is as follows: A young working girl, aged 16, had been constantly engaged in her duties. She had been a servant in a home until the night before the time I saw her, at which time her attending physician sent her to the hospital for the purpose of having removed from the outer aspect of the left thigh what was supposed to be a lipoma. I did not examine the girl until she came to the operating-table. Upon examination I found it was not a lipoma, yet I will be frank to say I did not know exactly what it was. In other words, it presented a mass about the size of half of an apple stuck under the skin, slightly lobulated, covered with a dense limiting membrane, and fluctuating, but gave apparently, a pasty consistency. It was found to be caseated tuberculous material which found its way through the fascia lata, and it was found to have its origin in the trochanter major, where there existed a cavity which, after it was curetted, was large enough to permit a filbert to drop into it. The girl is up and about now, and there is no reason why she should stay in bed. Later *x*-ray examination of the skeletal structure failed to reveal the presence of tubercular areas elsewhere, and the girl otherwise is in good health. I may say that only a period of eight or ten days prior to this time did she experience any pain, and this pain was down at the site where the tubercular débris was present underneath the integument.

I would like to say a word or two about heliotherapy, not because of the fact that I have had any experience with it, but because of the fact I had hoped Dr. Schwyzer would have presented to us the statistics of Rollier.

It was my good fortune a couple of months ago (I am sorry I have forgotten some of the details) to read Rollier's article, which came to me at a late date, because most of you know that the foreign medical literature has not been coming to us regularly until recently. I want to say to the gentlemen who have not read this article to do so at their earliest convenience. When I had read it I felt a little doubt as to whether the man was telling the truth, and that, if he was,

I had been a bungling surgeon for a long time, if not for the whole of my professional life. He reports over 1,200 cases of surgical tuberculosis of all types, as shown by x-ray photographs and otherwise, and these cases include renal tuberculosis and tuberculosis of the peritoneum, and what is the mortality? Only 28 deaths, if I remember correctly. As Dr. Schwyzer has said, he has records of operative procedures, but I think the total number of his operations up to that time was something like 30 or 35.

Dr. George N. Kreider (Springfield, Ill.): I am glad Dr. Schwyzer brought up the matter of the Rollier treatment, and to those who are not familiar with the treatment I will say that in 1913 I had the privilege of visiting Dr. Rollier's clinic at Leysin, Switzerland. He made such an impression at the International Medical Congress in London that year, that everybody was astonished at his results. Dr. James F. Percy, the President of this Association last year, visited Leysin with me, and I tell you the Rollier treatment was a revelation to us. He is telling the truth, and there can be no question about it. He does not do any operating. Every one ought to read the Rollier article that Dr. Jepson has referred to. If you remember, there was one picture where there was extrusion of a tuberculous bone at the ankle joint. He did not even apply a forceps to take it off. That would be considered an operation in the mind of the patient.

Cases of tuberculosis of the spine with curvature are cured without a plaster jacket. He puts the children on the belly and then, by their individual movements unfolds the curvatures.

Our visit there was very satisfactory and instructive. For instance, what happened as a result of it? When I came back, in finishing up our hospital I suggested a sun deck on the roof to expose patients whenever it was possible to get them up for sun treatment. There is nothing like good, pure air and sunshine for these patients. Dr. Percy told me a short time ago that he had had wonderful success in cases of empyema at Camp Kearney as a result of what he saw at Leysin. I am glad this matter has been brought up because this sun treatment is so valuable, I think all practitioners should know about the Rollier treatment at the earliest possible moment. He absolutely avoids any operation in a large percentage of these cases of surgical tuberculosis.

Dr. Emil G. Beck (Chicago, Ill.): I had the opportunity of visiting Professor Rollier's Institute some five years ago,

and I am convinced that his methods of treatment for surgical tuberculosis, both in the early and late cases, are the best. I have read his reports and have compared them with reports from the largest clinics in Germany. This report of Rollier was presented at the Congress, where he presented his results and compared with the results of other surgeons at the Surgical Congress, it was found that the surgeons in Germany and all over the world had not as many good results as Rollier had had from his treatment. In fact, Rollier had five times as many cures without operation as other surgeons had with operation.

It is very strange that in a country like America, where money is so plentiful, somebody does not build an institution like Rollier's. The conditions are as favorable here as they are at Leysin, and still we see cases of tuberculosis operated on every day in clinics. If the end-results are favorable in some of the cases the surgeons are satisfied, but those patients who have not been cured by surgery hobble around from one clinic to another. I have seen many hundreds of such cases that have been operated upon, with sinuses that have incapacitated them for work.

When I came to Chicago after my visit to Leysin,I thought I would try to imitate Rollier in a small way. Accordingly, I took some children that had tuberculosis, built a small platform on a window over a radiator in the hospital, took the window out during several months, and kept them there in the same position, keeping a pillow under the chest during the whole day, and at night turning the child over and putting a sort of brace or sandbag against the back. I have had six cases, and all of them got well, without any casts. I have never yet put on a cast in a case of tuberculosis of the spine, and never will, because the inconvenience to the child, the blocking up of all the excretions, and the abrading of the skin, do more harm to the child than if you leave off the cast and wash it every day, exposing it to the sun in a window, and keep it on an inclined board, and the child can play and eat.

I brought this matter before the Chicago Surgical Society two years ago, demonstrating six cases, showing that fibrocartilage was regenerated in those cases where the bones were collapsed by keeping the spine in this position.

Dr. D. P. Mayhew (Colorado Springs, Colo.): In my younger days I was very enthusiastic about operations on cases of tuberculosis, but some years ago I received a lesson

in that regard from my good friend Dr. Powers, of Denver. A nurse presented herself with tuberculosis of one of the metatarsal bones of the foot. I was enthusiastic about removing the lesion, but she had the good sense to see Dr. Powers who had advised against operation. The foot was simply kept quiet, and in a short time she was well and has remained well since without any shortening of the foot. This was some fifteen years go. That was a very good lesson to me, and I began to study the subject of tuberculosis in its relationship to operation. I made up my mind that in general terms we can divide cases of tuberculosis into two wide classes,—those occurring in children and those in adults. In the case of children I would say you should hardly operate even if you have to. That statement seems a paradox, but I mean it. We have learned methods that are infinitely superior to operation. Those of us who have seen many of the very bad results which so frequently follow surgical intervention in tuberculosis of children, from secondary infections, approach these cases with a great deal of hesitancy. It seems as if the tubercle bacillus has an affinity for certain tissues only, and among those are the bone, but not the soft connective tissue. We see evidence of that in the white swelling, so-called, where the tuberculous pus has escaped from the bone and is lying innocuous in the soft tissues, these soft tissues not being infected. If we put in by operating, a secondary infection, we get a condition which may be likened to that of symbiosis. The tubercle bacillus with the assistance of the secondary infection becomes competent and is able to infect the soft tissues and does so. We have as a result the formation of sinuses, which persist for months and months, and that pathetic picture of a little child, almost uncomplaining, but reduced enormously in strength and vitality, who so frequently dies in spite of what we can do.

In the case of adults I think the question of operation is more to be considered. Just why that is I do not know, but I have observed that tuberculosis in the bones and joints of adults is not quite so susceptible to healing as it is in children. In children we can say that tuberculosis of bones and joints is a condition which will get well of itself if given a chance, and that chance is practically putting the parts at rest with the use of heliotherapy. Rollier has added to our armamentarium the most valuable single thing of which I know. It is perfectly surprising to see these children and adults who are given the treatment of heliotherapy pick up in weight and see their lesions heal. Heliotherapy is of

value, not only in joint and bone tuberculosis, but in all types of tuberculosis, including that of the kidney.

The technic is very simple, and it can be used in conditions which you would not believe at first. Dr. Webb introduced this method of treatment into Colorado Springs some years ago. I have had the opportunity of seeing his cases, as well as a number in my own practice, and observing the results following exposure of the body to the direct sun rays without the interposition of anything. The patients are exposed to the sun's rays for one minute per day, at first, on each side. This is increased about a minute per day, and at the end of a month the patient is getting thirty minutes on each side. These patients quickly become accustomed to the out-of-door air, and in Colorado Springs we can continue this treatment during the winter months even when snow is on the ground.

We can show photographs of children alongside the snow bank with not a stitch of clothing on them and perfectly comfortable.

I have noted that these cases fall into two classes. One of these is marked by a very deep browning of the skin. Such will be improved. A few cases will not respond by browning. These cases will not be improved. Why they do not, I do not know. The value of heliotherapy suggests something which is apparent to every Coloradoan; that, as in Colorado we get twice as much sunlight as they do in the east or around the Great Lakes Region, Colorado is twice as valuable for the treatment of tuberculosis. At the Children's Hospital in Detroit we treated the children in a solarium. The amount of sunshine was marvelously small, and what we had was a pale filtered sunlight very different from that which we get in Colorado.

I do not operate on cases of tuberculosis in children, but immobilize the joints and give them heliotherapy.

Dr. W. W. Grant (Denver, Colo.): I would like to say just a few words on this subject. I do this because *nature* has provided Colorado with these heliotherapeutic conditions and that, naturally, we have to go to very little expense in knowing how to treat these tuberculous patients. As a matter of fact, unconsciously this system has been applied for many years in Colorado under different names. We send patients into the mountains, let them, in the coldest weather, sleep out of doors, and during the day get the sunshine. If you

would visit the Children's Hospital in Denver, which I think is one of the most nearly perfect hospitals ever built—complete in every sense—and look at the material there, you will always find from thirty to fifty children in a sun-parlor the whole day—some of them lying on their backs in casts and not permitted to sit up. They are comfortable and happy in a fixation apparatus.

Operations on these children are very rare. I know of nothing that is more unfortunate, that excites more pity, than to see, as was done not many years ago, a complete exsection of the head of the femur for tuberculous infection, and while it is true that by removing the head of the femur you may have a much quicker recovery, you have left the child in a much more unfortunate condition, for under these natural climatic conditions, with plenty of fresh air and dry sunshine and conservative measures of treatment, these children get well, with less shortening of the leg, even with suppuration and infection of the head of the bone, and some of them will have fistulous tracts, but they are not, as a rule, operated on by any extensive procedure for necrosis. I have had in some of these fistulous cases following suppuration no hesitancy in injecting bismuth paste, which will find its way into the little devious tracts and under this conservative treatment, repeated as often as you may feel it is necessary, the discharge ceases, and a larger proportion of these children will get well with good nutritious food and pure air and sunshine in Colorado than under any other medical or surgical treatment.

Dr. Schwyzer (closing the discussion on his part): As to Dr. Jepson's remarks: I think the answer has been given by Dr. Beck and other gentlemen who have taken part in the discussion. Unfortunately, I have not been in Leysin, but I have read the contributions that have emanated from Rollier's clinic and have been very much interested in them.

As I said in my paper, Rollier has put the treatment of surgical tuberculosis by heliotherapy on a scientific basis, and has taken the sun treatment out of the hands of the charlatans. Again I can heartily endorse the creation of institutions in different parts of this country where the sun treatment will be given intelligently and advantageously. Naturally some states like Colorado and so on with certain high altitudes are preferable. Nevertheless, it looks to me that heliotherapy could be carried out in states of lower altitudes. At the present time, when we cannot give our patients sun

treatment in the sense of Rollier, we certainly must make allowance for surgical procedure. Poor people cannot be sent away into other states. Furthermore the time it requires for the cure by the sun treatment is often prohibitive. Take, for instance, a working man who has to support a large family: he is excluded from such benefiting treatment at the present time, and must depend upon a prompt surgical cure.

With reference to the remarks of Dr. Grant, I will say that Rollier does not inject bismuth paste, iodoform mixtures, etc., into fistulous canals. In his opinion it is important to preserve the natural outlet of secretion.

Dr. Corwin (closing the discussion): With regard to the case in which the four plus Wassermann was reported, I will say the patient was admitted to the hospital, and treatment instituted from the beginning.

Dr. Gregoire, of Paris, through the assistance of The Pasteur Laboratory, is making vaccine at present for his idiopathic cases. He showed me last summer a number of his cases, which are improving satisfactorily. I had a letter from him about a week ago in which he still further reports "whether I will be able to do what is hoped that may be done is a question."

In regard to infection elsewhere than local, there is no question. Dr. Rosenow, of Rochester, gave a most scientific and interesting talk the other day at Denver before the medical and dental societies of the state and told of the relation of mouth-infection to the appendix, the gall-bladder, and the nerves. In a person suffering with pyorrhea and at the same time with inflammation of the gall-bladder or appendix, if pus be taken from the root of the tooth and injected into a rabbit, the rabbit, like the person, will suffer from infection of the gall-bladder or appendix. A woman came to him suffering with facial neuralgia, at the same time with pyorrhea. Pus from the tooth was injected into the rabbit and up went the rabbit's jaw. When asked how he accounted for pus selecting its location, he answered, "I do not account for it, I simply know it is a fact."

With regard to Dr. Dehelly: He was at my house last year, and I was with him last July in France and was also with him at Compiegne in 1916. I am familiar with his treatment; I also know the work of Dr. Chutro and the manner he cleans up his cases, which is most satisfactory.

Those who have been with Chutro know how skillfully he handles his cases.

With reference to the Carrel-Dakin treatment: I am not going to talk about it other than to say I have faith in it.

Relative to what has been said about Colorado Springs and other cities in Colorado, I will add that Colorado Springs is an excellent place for sunshine, as is also Denver. I have the greatest respect for Denver and the sunlight they get there, but *the* place you get more sunlight than anywhere else is Pueblo. (Laughter.)

A NEW METHOD OF APPLYING PLASTER-OF-PARIS SPLINTS

Lewis H. McKinnie, M. D.

COLORADO SPRINGS, COLORADO

I have considerable hesitancy in presenting to this body of men so simple a thing as a plaster cast, but this little cast has been a good deal of help to me, and I thought it might be of considerable help to you. The principal things that recommend it to me are ease of application, cleanliness of application, and the accuracy with which it can be placed upon almost any part of the body.

I here show a cast that actually has been in service for five weeks for a fracture of the olecranon, and fractures of the styloid processes of both ulna and radius. (Demonstrating.) The method by which it is applied is this: I take cotton flannel or muslin sufficiently large that it will go around the part where it is to be applied and enough excess so that it can be pinned around the arm or leg, or around the body. If it is the forearm I now measure at the elbow, at the wrist, and then the length I wish the cast to be. A drawing is made upon muslin or cotton flannel, corresponding to these measurements, and the plaster of Paris bandages put backward and forward, filling in the picture. It is put on dry. On top of that, to protect the arm and keep it from becoming adherent, I put on a layer of gauze, or cotton wadding, then soak thoroughly with salt solution, slip it under the arm or leg, as the case may be, pull tight, and pin. This, you will see, gives you the shape, size, and everything that you want for the arm.

I have the material here, and I will put on one of the easiest casts, rather than attempt one of the more complicated ones, because, if you once see the principle, your own ingenuity will allow you to put this cast on almost any part of the body.

In the meantime I will talk about some of the modifications. In putting on a straight cast it is simple, but, if you have the elbow or ankle or some part that is not straight, you need some ingenuity in outlining your cast. In turning the elbow and putting this cast on at an angle of 90°, you do it in the one piece, as for the forearm. When the form is laid out flat the outline will be in the shape of a capital T. You put the long tail on the forearm, fit it around the front of the forearm, and pin. One arm of the T goes on the outside of the arm; the other on the inner. You then pin in two rows front and back, instead of in one row, as on the forearm. This is an exceedingly easy cast to put on, and is one that is as easy to remove. You may inspect any part of the wound you want to; and you can cover as much of the circumference of the arm or leg as you wish. It is a valuable cast to apply in any bone work,—simple fracture, compound fracture, or any bone-grafting work,—in that you can see and watch the wound all the time throughout the convalescence without disturbing the cast.

In putting it on, you can hold the parts absolutely while the nurse or an assistant pins it in place, and you know when it is in place, the bones not having slipped.

One of the larger fields in which it can be used, and has been used, successfully, is in the application of the corset for any of the middle-spinal conditions, where you want support between the hip and shoulders. A pattern can be made of heavy muslin. Here cotton flannel is too flexible and will not give you the strength

that you need and desire. I have used rabbit wire in the plaster cast; it makes the cast much stronger without additional weight, and I think it helps the cast very materially. If you are going to use six layers of plaster, put the rabbit wire in the middle. It will be thoroughly embedded in the plaster and makes a very nice cast. I have used this cast for tuberculosis of the hip where it is not necessary to use an extension apparatus with the splint. In applying this cast, encircle the abdomen, the hip and the leg down to and including the foot. It may be removed every day. The nurses put in eyelets and lace the cast. It is laced on and off every day when the dressing is changed. It has worked very satisfactorily in these cases.

In a Colles' fracture, when you want any particular position, hold the parts until the cast is slipped on, pinned, and hardened. I have gotten so that, when I go out to take care of the simpler fractures, I take plaster-of-Paris bandage, cotton flannel, a pair of scissors, and a tape measure, and find it much easier, quicker, and more accurate than a splint cut out of a shingle or the top of an orange box. It is safe, and I have never had to unpin the cast to allow for swelling.

This is ordinary cotton flannel you see here, and we will put this on Dr. Donaldson, of Kansas City, who has kindly offered to let us demonstrate the application of the splint on him. We take measurements for the length and width of the forearm. Dr. Mayhew is helping me. The length of the forearm from the elbow to the wrist is eleven inches, so we allow eleven inches for length; at the elbow we find it ten inches and at the wrist six inches. You can put plaster just as far around as you wish, clear around, half way around, two-thirds or three-quarters the way round, according to the requirements of the case. If you have a large abrasion or incision on the front of the arm, leave the cast so that you can see it by removing the pins. You

can make the cast just as heavy as you want. You can mold it into any position or shape.

You can see the outline on this muslin. This is one of the simplest and easiest ones. We take the dry plaster; you keep it dry until absolutely ready to apply. If you get this ready and find something has gone wrong with the arm, you can fix it. Take all the time you want. When you have the part as you wish it, have an assistant or nurse soak the plaster, slip into place, and pin. You will observe that Dr. Mayhew is running the plaster of Paris bandages back and forth until he has the required thickness. You may use four layers, six layers, or as many as you want, and then one thickness of ordinary gauze or cotton batting, as you prefer. If you put it around the heel, a rest of lamb's wool is a great comfort. Your bandage is now ready to apply. Dr. Donaldson has not a broken arm, but we will take it for granted the bone is set and the fracture properly held.

The cast is in position and pinned. For a Colles' fracture, where I want the wrist in any particular position, I put the cast on from the side of the arm. I have not had a patient complain of one of these plaster casts in any way. It is perfectly comfortable and can hardly be otherwise because it can be made to fit so absolutely. It is simple, easy and clean. I do not think we have gotten much, if any, mess in applying this cast. You can put it on in any home without newspapers all over the floor and without getting plaster all over the neighborhood.

This model I brought has been put on from the side. I found by the fluoroscope when I put the wrist in a certain position it held the styloid process where it belongs. In using a plaster cast for the back or the spine you can get the patient ready, take your measurements, put in extension, apply the cast, pad the axilla, and put the cast on as you would a corset. You can fit it in

the axilla and over the hips perfectly. When you let the patient down he is in a corset that fits; and re-enforced with rabbit wire it is there to stay.

The only thing that approaches this cast was the cast used years ago, then known, I believe, as the Bavarian cast. The shell that is used in some parts of the country is similar to this and is put on with many tail bandages. I think the pins are superior, in that you can put the tension where you want it.

This cast has not been pinned on tightly. With the cotton flannel it must be pulled tight, just as tight as it can be pinned. If it is too tight, take the pins out. This one (indicating) is too loose and has not set very much.

Dr. Donaldson will be glad to walk around so that you can see the cast while it is wet and how easy it is of application.

DISCUSSION

Dr. W. T. Coughlin (St. Louis, Mo.): I do not believe there is much I can say for or against the new method of applying a plaster-of-Paris splint, which the doctor has described. It looks very easy and simple.

We have often applied a sort of slab splint made of plaster-of-Paris. Our method is a very old one. One takes a piece of old or thin muslin about four inches longer than one wants the splint to be and about two-and-one-half times as wide as one desires to make the splint. This is laid out on the table, and one then takes a bandage, and, beginning two inches from the end and in the middle of the piece of muslin, he unrolls until the bandage is within two inches of the other end of the muslin. He now sprinkles dry plaster on the unrolled piece of bandage and works it into the bandage. He next unrolls the bandage backward over this layer, presses it down, sprinkles on more plaster, and works it in to this layer as before. And so on, layer by layer, until the desired thickness is obtained. The ends and sides are now folded over the plaster and folds of bandage. The limb is prepared; the reduction made and maintained; and layers of cotton are applied. Then the plaster splint is rolled loosely

and dipped in water, and when bubbles cease to rise it is taken and applied as desired and fixed to the part with a bandage. The part is held in proper position while the plaster "sets." When hard the bandage which holds and molds it to the limb can be removed and the splint taken off and re-applied whenever need be. It has been satisfactory. One can turn a corner or round a prominence with it very readily. No pattern is needed. It is not necessary that a splint extend all the way around a limb. With a slab splint one can inspect the limb and even dress a compound fracture without ever removing the splint. I think it is about as clean as the method demonstrated and about as good; however, I shall be glad to give the method of Dr. McKinnie a trial in practice.

Dr. Samuel C. Plummer (Chicago, Ill.): Dr. McKinnie spoke about the Bulgarian splint. I think it should be Bavarian. I was very familiar with this splint years ago when I was an interne in the Cook County Hospital, Chicago. We took a number of layers of light flannel, sewed them together in such a way as to have the surfaces of the various layers in contact along a strip half an inch wide, and then plaster of Paris was put between the various layers and molded to the limb. This left a sort of hinge where the layers were sewed. Where you wanted to remove the splint daily, we found these splints were convenient and comfortable.

Dr. John L. Porter (Chicago, Ill.): I am not a member of the Western Surgical Association, consequently I feel a little hesitancy in getting up to criticize the method that has been described and demonstrated. I cannot see the slightest reason for doing a thing of that kind if one knows how to on a plaster cast, however, without protecting the skin too a plaster cast, then it is a good excuse for this makeshift. If you have a good plaster bandage, properly made and the skin properly protected, I do not see any reason for using circular bandages and making a roller splint. If you have to depend upon the plaster-of-Paris bandages that you buy in a tin box, made of material that is altogether too thick and too heavy, such as I had to use at a hospital here, and if you have not had the proper training in protecting the skin and placing the broken arm or deformed limb, and do not know how to put a splint on, the method that has been described is all right.

I cannot see any reason for not protecting the skin and doing a lot of other things that might be done in connec-

tion with this method. Really, I think all of us ought to learn how to put on plaster casts. (Laughter.)

Dr. Leonard Freeman (Denver, Colo.): The gentleman who has just spoken (Dr. Porter) tells us that Dr. McKinnie ought to learn how to put on a plaster cast—that the skin should be protected by a thick layer of cotton. You can put on a plaster case, however, without protecting the skin too much. If he says he wants always to protect the skin with a lot of cotton, it shows that he does not know too much about the subject himself. A plaster cast is for the purpose of holding the bones in proper position, and if too much padding is put between the plaster and the skin the cast may be useless.

Dr. McKinnie has described an excellent method. We have used something similar; but he has worked the procedure out mathematically, and I think we owe him much.

Dr. McKinnie (closing): I have nothing further to say except to bring out the one point that I do not expect this to take the place of other kinds of plaster-of-Paris splints. I have been impressed, however, with its ease and accuracy, and to be able to keep track of the limb until the cast is absolutely on and set is worth while.

VOLKMANN'S CONTRACTURE OF THE FOREARM, WITH PRESENTATION OF A PATIENT

Clifford U. Collins, M. D.

PEORIA, ILLINOIS

On March 16, 1903, M. H., aged 7, living at Vandalia, Illinois, was playing on a hay-stack ten feet high and fell off, breaking both bones of the left forearm at the juncture of the upper and middle thirds. Dr. M. was called and applied anterior and posterior splints and a small interosseous splint, all of wood padded with cotton, which were bandaged snugly to the forearm. The splints were removed in three weeks, and, judging from appearances, a good result had been secured. There were good unions and an almost normal contour of the forearm.

But the parents soon noticed that the thumb and fingers were closing down into the palm of the hand, and there was little or no sensation in the third and fourth fingers. An effort was made with massage and manipulation to overcome the condition, but it grew worse in spite of all efforts.

In June, 1903, the patient was brought to the St. Francis Hospital, in Peoria. A typical Volkmann's contraction of the flexor muscles of the forearm was found. (Fig. 1.) When the wrist was flexed the fingers could be made straight, but the fingers and wrist could not be extended at the same time. The finger-nails showed degeneration, the entire hand was smaller than its mate and bluish in color, and there was no sensation in the third and fourth fingers. A radiograph was taken, and showed a fracture and faulty union of both bones (Fig. 2), but the fracture

of the ulna seemed to be causing the most trouble, judging from the facts that the muscles flexing the fingers lie more to the ulnar side of the forearm, and the third and fourth fingers, the fingers supplied by the ulnar nerve, were anesthetic.

On June 11, 1903, a longitudinal incision was made along the posterior surface of the forearm over the ulna. The muscles and fascia were separated from the bone, except at the point of fracture where it was impossible. The muscle and fascia had been transfixed by a sharp fragment of the fractured ulna. A portion of the muscle and fascia was caught in the

Fig. 1

callus, which had to be cut before the muscle could be freed. A partially organized hematoma, about three centimeters in diameter, was found in the muscle near the site of the fracture, and removed. Neither the hematoma nor the transfixed muscle could be detected by the *x*-rays.

The ulna was sawed through at the point of fracture with a Gigli saw, and the ends were trimmed off and united in a better position with two aluminum-bronze wires. (Fig. 3.) The muscles and fascia were separated from the fractured point of the radius as much as was possible through that incision. While the

patient was under the anesthetic his fingers were forcibly extended considerably, but it was impossible to extend them completely. The fascia and skin were united with two longitudinal aluminum-bronze wires, and the forearm was placed in an ulnar splint of perforated tin.

The patient left the hospital for his home on June 20. An earnest effort was made from then on to

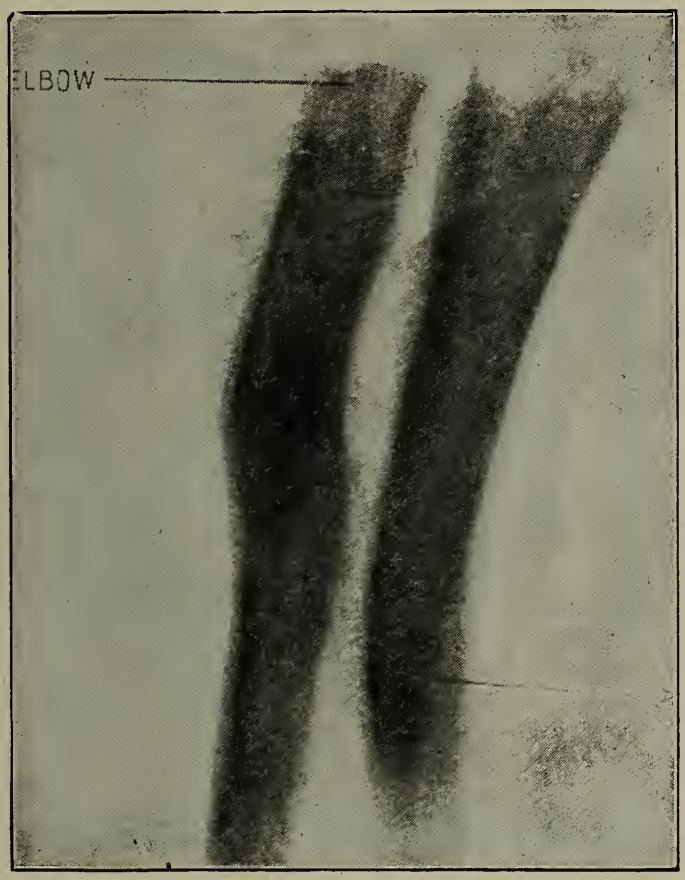

Fig. 2

overcome the contracture by massage and manipulation of the hand and fingers. After the ulna had united, the muscles of the forearm were thoroughly massaged each day. The boy's mother worked very faithfully with his hand and forearm, and the improvement during that time was no doubt largely due to her

efforts. Sensation returned to the third and fourth fingers, and the general condition of the hand became much improved, but the boy could not extend the fingers.

On August 17, 1903, at the patient's home in Vandalia, a longitudinal incision was made in the center of the anterior surface of the forearm, two inches

Fig. 3

long, beginning at the wrist. The tendons of the flexor profundus digitorum were lengthened by the ordinary stair-step method, and the ends were united with catgut. This was not sufficient, so the tendons of the flexor sublimis digitorum were also lengthened. Then all the fingers could be completely ex-

tended without resistance. The tendons of the thumb were left alone as its condition had improved very much under the massage. Union occurred by first intention, and in ten days the boy could move his fingers. The improvement from then on was rapid and satisfactory.

A history of the case was published at that time.[1]

I have two reasons for bringing this patient before you to-day. First, I want to show you the ultimate results, sixteen years afterwards, of one tendon-lengthening operation for Volkmann's contracture of

Fig. 4

the forearm. (Fig. 4.) Secondly, a recent article[2] says:

"In view of the mechanical shortening of the sclerosed muscles, artificial lengthening of the flexor tendons at the wrist has been tried. The disadvantages of this operation are the extensive dissection which is required and the prolonged after-treatment of the wound."

"A simpler operation is one which shortens the bones of the forearm by excising an inch, or more, of

1. Interstate Medical Journal, August, 1909.
2. British Medical Journal, 1918, ii, 151.

both radius and ulna, so as to allow of the fingers being placed in a position of extension and even slightly hyperextension. The patient then has a shorter forearm but a more useful hand. The drawback to this procedure is the tendency to the formation of still more scar tissue by operating on an already sclerosed limb."

Fig. 5

The lengthening of the tendons in this case was done at the patient's home, and I did not consider it an extensive dissection. There was no prolonged after-treatment, and, I am sure, the procedure was much simpler than a resection of the bones of the forearm would have been. The final result in this case shows no deformity, while a resection of the bones of the forearm would have left a shortened forearm.

This patient was received into the service without question during the late war, and served his required time in the army.

Incidentally, an *x*-ray picture (Fig. 5) of the forearm taken a few months ago settles a question that was often asked fifteen or twenty years ago. Was the aluminum-bronze wire finally absorbed by the tissues? A good many contended that it was. This picture shows the two loops of aluminum-bronze wire, which I put in more than sixteen years ago, still intact and unchanged in any way. They became completely enclosed in bone as the patient grew to manhood. A little piece can be seen lying in the soft tissues that evidently fell there when the twisted ends were cut off with scissors at the time of the operation, showing that the soft tissues produce no more impression on an aluminum-bronze wire than bone.

This patient was seven years old when he received his injury, which was in the period of from one to fourteen years when Volkmann's contracture usually occurs. It has always seemed to me that there must be other factors besides a tight bandage or we would surely see such cases more frequently. In this case I believe that the transfixing of the muscles by the fragment of the ulna, and the hematoma, with probable impairment of the blood current and blood supply, had as much to do with the ensuing contraction as the splints and bandages.

You will note that manipulation was used before the malunion of the ulna was corrected. The tendons were not lengthened until two months afterwards, and during that time manipulation was used. I think it important that manipulation and massage be used until the contracting process has ceased. I had not heard of the Robert Jones method at that time.

Dr. Arthur E. Hertzler (Kansas City, Mo.): Within a year I have seen cases of myositis produced by a miss shot with salvarsan and with alcohol. You can get a localized myositis with a blood-clot without any doubt, but I think there is where the difficulty comes. If you have a localized myositis from one of these localized causes there is some use in lengthening the tendons. If you have a universal myositis, where the whole muscle is involved, tendon lengthening does not do any good. I did not know that once and lengthened the tendons in a case where I should have displayed more sense.

The prognosis of these cases will depend upon the extent of the fibrosing myositis. That must be kept in mind before an operation is undertaken.

In the case of Dr. Collins we very clearly had a localizing myositis in the region of the fracture, and it was due to the fracture trauma, and not to the tight bandage, which would have produced universal fibrosing myositis.

Dr. Leonard Freeman (Denver, Colo.): This is such an interesting and important subject that it should be considered carefully.

The suggestion Dr. Collins makes that there may be something else besides tight bandaging which causes this myositis is important to all of us, and should be generally known. However, most cases, undoubtedly, are due to tight bandaging. From the tight bandaging the muscle cells are deprived of their vitality by direct pressure and also by the deprivation of blood to the part. There are two things which happen. It is not only that the muscles themselves are injured, but finally the nerves become injured also, not at first, but later on, and I should like to call attention particularly to this nerve involvement.

Injury to the muscle causes it to become fibrous. Fibrous tissue contracts, and the contraction pulls up the fingers and we get the well known claw-hand. But the fibrous contraction does something else. In the course of time it compromises the nerves, usually at points which can be determined beforehand with some accuracy. This nerve implication causes certain things to occur in the hand; not only tingling and loss of sensation, which Dr. Collins spoke of, but also alterations in the skin. The anesthetic hand may appear

"glazed" and possibly have blisters on it, and may become purplish whenever it is exposed to cold. I have seen individuals with such severe lesions of the hand from nerve pressure that they could hardly insert their hands into their pockets, in fact, one of them demanded an amputation if relief was not to be obtained otherwise. In mild cases, massage, lengthening of tendons, forcible extension of the fingers, the Jones treatment, etc., should be carried out, and they probably will be sufficient. In the bad cases, where the nerves are very much implicated, we should also try these things, but if the nerves do not respond and the hand does not get better within a reasonable time, we should give the nerves themselves some sort of consideration. If the trouble were due to a cicatrix pressing upon the nerve and causing disturbance of its function, every one would immediately think of freeing the nerve. With the spinal cord, whenever the nerve tissue is pressed upon, we first think of relieving the pressure. So I contend we should give consideration in these bad cases to the relief of pressure upon the nerves, which can be done by dissecting down upon them, taking them out of their position in the cicatrized muscles, and putting them under the skin or surrounding them with fat, or perhaps putting them in some better position where they won't be pressed upon. When you cut down upon these nerves it is astonishing to see the manifestations of direct pressure: Perhaps the nerves are bulbous, or even pressed out of existence until they are mere strings of tissue. It is too late to do much good for the extreme cases. If we liberate the nerves it should be done early. I operated on a number of cases in this way some years ago. In some of them I failed absolutely, because I operated too late. In two cases my results were reasonably good, in that the operations relieved them of their worst pains and trophic disturbances in the hand.

Dr. E. M. Sanders (Nashville, Tenn.): I would like to lay some stress on the so-called abortive treatment of this condition. If we are fortunate to see a reasonable number of these children before the condition becomes well marked and definitely established, the question will always arise: What can we do to prevent or remedy this most unfortunate complication? As brought out by Murphy and as proven by the experimental work of Bardenhauer, a good deal can be done for these unfortunate children. First, of course, the splint should be removed. We have made it a rule for a long time in our work to tell the mother, the father, or

the attending nurse, if the child cries with pain, and will not rest and will not sleep, to take the splints off and put the arm on the pillow. In such cases as Dr. Collins has described there may be a hematoma or blood-clot, or a lot of effusion in the fascial bands that hold the muscles, consequently it must be true that not only external but internal pressure can produce this condition. This is an unfortunate condition to have in connection with legal complications that some of us have had and others probably will have. I believe that two or three things can be done to prevent the condition from being so severe without giving up. Of course, no one knows how rapidly myositis is established. I think Murphy claims it is established in forty-eight hours, may be twenty-four hours, while others claim in a longer or shorter time, but regardless of the time we see these cases, I think we should not only give active motion, have the child to co-operate with us, and give active and passive motion to the child, but we should go further and anesthetize these patients and through a series of splits in the skin we can reach in with the knife and make a lot of drainage sacs and let out the effusion and blood.

We had one case in which the patient was shot in the arm, where the condition described seemed to be developing. We used prophylaxis or the abortive treatment in this case and were able to reach the most deep-seated muscles that were involved. We got some contracture, but we did not get any contraction of the fingers. We should pay particular attention to the so-called abortive treatment of this condition.

Dr. D. S. Fairchild, Sr. (Clinton, Iowa): I have had a good deal to do with the misfortunes of doctors in the past ten or twelve years, and one of these misfortunes is from Volkmann's paralysis. These are exceedingly difficult cases to defend when they are subject of suits for malpractice, and I think what Dr. Freeman has said is very much to the point here, namely, to show that many cases are due to other conditions than to tight bandaging. We looked up the matter to find out the percentage of cases of Volkmann's paralysis occurring from tight bandages and from other causes, and we found 80 per cent. of the cases were due to tight bandaging, and 20 per cent. due to other causes, so these are facts that should be borne in mind when cases of this kind come up.

OPERATIVE TECHNIC IN SPINA BIFIDA

JOSEPH RILUS EASTMAN, M. D.

INDIANAPOLIS, INDIANA

In few operative procedures is the mortality, both immediate and secondary, as high as that in spina bifida. The immediate death rate from shock, meningitis, etc., is approximately 33⅓ per cent, while the secondary mortality, from hydrocephalus, convulsions, etc., is equally great, resulting in an ultimate loss of from 60 to 70 per cent[1] of the patients. According to Hildebrand[2] only about 39 per cent make complete recoveries. Judicious selection of cases for operation, followed by rational, conservative technic would surely do much, not only to reduce this discouraging mortality, but also to establish the surgery of spina bifida on a sound basis.

This very obvious point has been quite clearly set forth in the majority of writings on the subject. Thus, Beckman and Adson[3] emphatically advise against operations associated with marked hydrocephalus or paralysis of the lower extremeties unless, in the first instance, the hydrocephalus is either allowed to become stationary or is relieved, for example, by puncture of the corpus callosum; and in the second instance, unless it is understood by all concerned that operation will have no remedial effect on the paralysis. Thorburn[4] and Tubby[5] of England agree with these authors and enumerate frequent instances in which operations for spina bifida associated with hydrocephalus markedly aggravated the hydrocephalic condition.

Excluding, therefore, all cases associated with an increasing hydrocephalus as at least temporarily inop-

erable, we are reduced to (1) operations on simple meningoceles in which the prognosis, if precautions hereinafter mentioned are observed, should be good,

Fig. 1.—Suturing lower curved border of rubber dam protective to the skin of child's back: first step in making watertight barrier against contamination of wound from excreta.

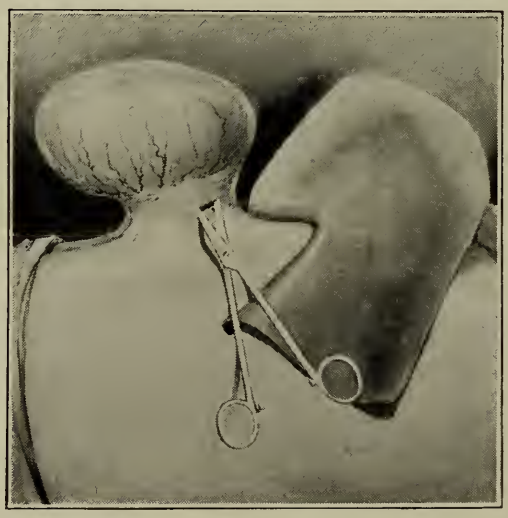

Fig. 2.—Circular incision begun in the collar of true skin, which is present in most meningoceles. This circular incision to free the sac neck is conveniently and safely done by scissors-spreading dissection.

perhaps below 5 per cent, and (2) operations on meningomyeloceles and syringomyeloceles, which are performed with little hope of remedying the paralysis and

with the purpose only of removing a deforming tumor and preventing subsequent ulceration and rupture.

In the latter cases, despite the disappointing results in regard to paralysis, operations may be said to have a quasi justification, since few children thus afflicted ever



Fig. 3.—Circular skin and fat incision complete, and neck of sac free.



Fig. 4.—Rubber-covered light intestine clamp applied to neck of sac to prevent escape of cerebrospinal fluid and entrance of infection.

reach maturity if not operated on; moreover, an unsightly tumor is removed. In the meningoceles there is no contra-indication to operation so far as the local

condition is concerned, and no apparent reason why low mortality and good operative results cannot be secured in any of the three varieties of this group, as described in the excellent classification of Binnie[6]:

A. A defect of the posterior osseous wall of the spinal canal is present. The skin, spinal membranes and cord are intact. There is a hernia of the dura through the osseous defect. Fluid in greater or less quantity is present in the dilated subdural space.

B. The conditions are the same as in A, except that the arachnoid is involved in the hernia, and the collection of fluid is in the subarachnoid space.

C. A defect exists in the dura as well as in the bone. Through these defects there protrudes a hernia sac consisting of the arachnoid. The skin, pia and cord are intact.

OPERATIVE TECHNIC

By transillumination, as used in hydrocele, one can determine with a fair degree of accuracy whether the sac contains nerves or cord, or both. At times, however, this may be misleading because of thickening and irregularities of the sac wall. In such cases application of a weak faradic current to various points on the sac may be of some diagnostic aid. Most frequently, however, the diagnosis of meningomyelocele depends directly on clinical evidence, such as clubfoot, partial or complete paraplegia, or defective sphincter control, some of which are nearly always present in a greater or less degree if a nerve is involved in the sac.

It is usually advised to place the child in the ventral Trendelenburg position or in the hanging position of Babcock in order to prevent or reduce to a minimum the escape of cerebrospinal fluid following incision of the sac. This step, of course, is of considerable importance, but I prefer in its place the expedient of applying a light rubber-covered clamp to the neck of the sac, as is hereinafter described and advocated. With this step in view, the child is placed in the ventral recum-

bent position with the operator and his assistant seated on opposite sides of the operating table. In this, as in other delicate and minute surgical operations, the sitting posture of the operator has advantages which are obvious and important.



Fig. 5.—Opening sac at thin and unusually transparent vertex of tumor.

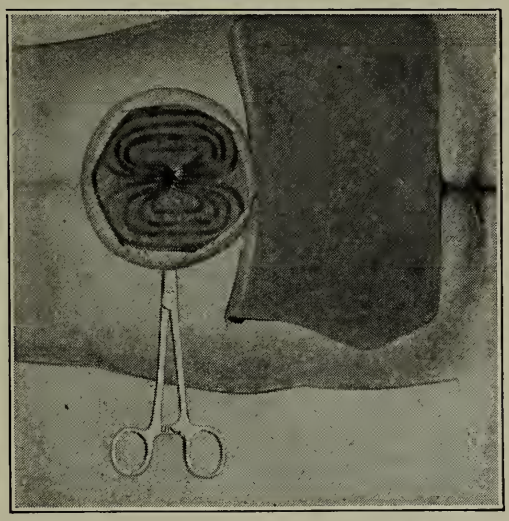

Fig. 6.—If cord elements, as shown diagrammatically here, are present in the sac, they can be freed while the clamp offers protection against infection and escape of fluid, although the chance of benefit to paralysis resulting from operation in myelocele is practically nil.

The first step of the operation consists in the taking of every precaution against the contamination of the

wound. The importance of this cannot be overestimated, because the one imminent post-operative danger in spina bifida is meningitis from wound infection. Contamination is made especially dangerous because often the site of the wound not only lies near the anal region, but because it also lies in the direct groove along which the infant's urine and feces are most likely to extend. Tubby,[5] in discusing contra-indications to operation in spina bifida, emphasizes that "lumbosacral tumors must be approached with caution because of the difficulty of avoiding fecal and urinary contamination." With this in mind, I place a piece of rubber dam over the tumor, and suture its lower border with fine chromic catgut to the skin of the child's back. The suture material, if quite fine, will allow of from eight to ten incursions and excursions of the needle to each inch of skin traversed. By reinforcing with collodion, this suture line may be made water-tight. The rubber dam is then turned downward, and the second procedure is begun.

This step consists in dividing the circular collar of true skin which usually is present about the base of the tumor. The tumor may, of course, in the first variety of meningocele, have a covering of true skin; but in those cases in which the tumor has no external covering except a very thin skin epithelium, there is nearly always a collar-like base of thick skin through which the true sac extrudes. By the employment of the scissors-spreading method of dissection, the circular incision through the skin at the base of the tumor may be made with little danger of the escape of fluid. The neck of the sac is then exposed as is the neck of the sac of the umbilical hernia in the Mayo operation, and is freed of all fat and connective tissue. The sac is then grasped between the rubber-covered jaws of a pair of light, delicate intestinal forceps.

The use of these clamps may be considered as of the highest importance in the surgery of spina bifida. It has been the practice, as mentioned above, to place the child either in the ventral Trendelenburg posture



Fig. 7.—Tying a stout transfixing ligature about the base of the sac, as in other forms of hernia.

Fig. 8.—Closing the skin wound with a running suture of chromic catgut reinforced with collodion.

or in the hanging position of Babcock in an effort to minimize cerebrospinal fluid leakage. The clamps, however, preclude such leakage with much greater cer-

tainty than does position, and in addition they are a valuable agent in excluding infection from the spinal cord. It may be contended that clamps will traumatize whatever nerves may be present in the sac. In respect of this point it should be noted, first, that whatever nerves are present in the sac will probably never functionate even if replaced, and, secondly, that the brief application of such delicate clamps will no more cause permanent nerve injury than will gastro-enterostomy clamps injure the stomach, or obstetric forceps injure the fetal head.

The advantages presented by any method which assures against loss of cerebrospinal fluid should not be overlooked. Thorburn[4] calls attention to this fact, saying, "It is in connection with this portion of the operation that its principal dangers—shock from profuse flow of cerebrospinal fluid or interference with nervous structures and meningitis—arise, and great caution should therefore be used to avoid a sudden escape of contents." Further he advises that "the upper end of the sac should be compressed with gauze to prevent a gush of fluid from the spinal cord." In addition to the advantages of the clamp method as just presented, the application of a rubber-covered light clamp greatly facilitates the replacing of the nerve elements in meningomyelocele.

With the neck clamped, the sac is opened by snipping it through the thinnest part, which is usually at the vertex of the tumor. Binnie[6] advises against opening the sac at this point since in meningomyelocele one is most likely to encounter cord and nerve structures in the median line. This is clearly a proper precaution unless one has been able to establish the diagnosis of meningocele beyond any doubt. If, however, the sac is opened at any point by a very small incision which is enlarged by scissors-spreading dissection, the cord and nerves may be saved from trauma. If, on opening the

sac, it is found to be free from nerve elements, a stout ligature is applied under the clamp jaws, the sac is cut away, and the clamp is removed.



Fig. 9.—Gauze square covering the wound; the edges strapped with adhesive plaster painted with collodion.

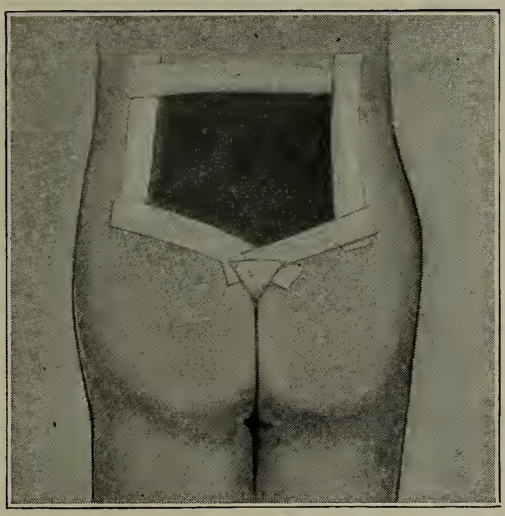

Fig. 10.—Rubber dam drawn up over the wound and secured at the edges with adhesive plaster straps coated with collodion.

The ligation of the sac, just mentioned, is performed as in inguinal hernia. Several writers, notably Bayer[7] and more recently Beckman and Adson, have called

attention to the analogy between spina bifida and inguinal hernia. I am of the same impression and believe in addition, that the operative treatment, when possible, should be similar.

If the opened sac is found to contain cord or nerve tissue, these structures, in some instances, may be removed by blunt dissection, while the light clamp is still in place to prevent the escape of fluid and the entrance of infection. If necessary, the bony defect of the vertebral column may be enlarged to admit of such replacement. This removal of bone can be accomplished while the clamp is still applied. I have encountered cases in which the spinal canal was not large enough to receive the cord and nerve elements completely, and others in which it was impossible to separate the thick ribbons of cord tissue from the sac. It is, of course, well understood, as mentioned before, that operation in such cases promises little or nothing so far as relief of paralysis is concerned.

After the neck of the sac is tied and the clamp removed, no attempt is made to close the bony defect by an osteoplastic operation. The danger of this step probably offsets the few and doubtful advantages it may provide. I have known of no recurrences of this form of hernia which might be traced to the omission of this step. I have found no record of such an accident, and I believe it must be rare. The muscles are drawn together over the stump of the sac, and the skin wound closed with a continuous suture of fine chromic catgut, either transversely or longitudinally, depending on which is the more easily accomplished. Hemostasis should be complete.

Procedures directed against wound-contamination, which were begun by stitching of the rubber dam to the child's back, are now completed. Collodion is applied over the wound line. Over this a strip of gauze

is placed, and its edges glued to the skin with adhesive plaster straps. This gauze and adhesive plaster are then painted with the collodion solution, after which the rubber-dam protective is drawn up and laid flat on the back, and its three remaining margins are glued to the skin, as was the underlying gauze, by adhesive-plaster straps. Next a small triangular piece of adhesive plaster is so applied that a sharp point passes downward between the buttocks, with the base of its triangle overlying the straps of adhesive plaster securing the lower border of the rubber dam. The adhesive plaster is then covered with collodion so that the zone of operation is sealed against infection by excreta.

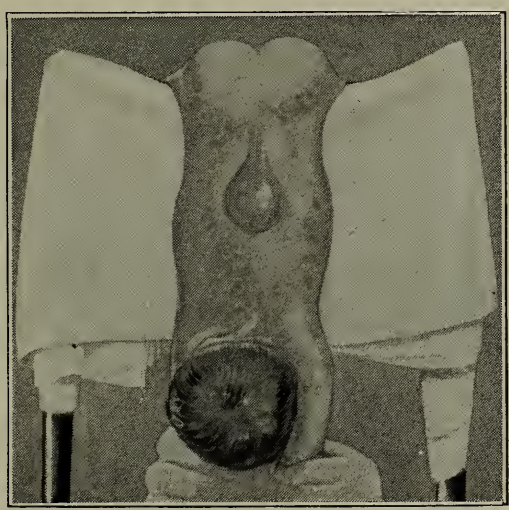

Fig. 11.—Inverted position used by Babcock to prevent the sudden escape of cerebrospinal fluid.

In certain rare forms of spina bifida, as in spina bifida occulta, the suggestions offered in this paper are, of course, without value. However, in one rare form, the anterior meningocele, a successful operation for which is reported by S. Roux,[8] the use of the clamp might remove many inconveniences. In the several forms of meningomyelocele, it is submitted that the application of the light clamp will facilitate and render more safe the additional steps required in the attempt

to deal in a radical way with this condition. With the simple meningoceles it is believed that the careful application of the technic herein embodied will make the operative mortality of this form quite as low as that in the analogous condition of inguinal hernia.

CONCLUSIONS

1. Spina bifida associated with increasing hydrocephalus is inoperable.

2. Operation should be performed in case of spina bifida associated with paralysis only for the purpose of preventing subsequent ulceration and rupture.

3. A rubber dam sutured at one margin to the skin below the tumor, adhesive plaster, and plentiful collodion should be used to prevent fecal and urinary contamination.

4. A light, rubber-covered clamp applied to the neck of the tumor is the safest method of preventing the loss of cerebrospinal fluid and also of excluding infection from the cord.

5. The sac can usually be tied off as in inguinal hernia.

REFERENCES

1. Albee, F. H.: Orthopedic and Reconstruction Surgery, 1919.

2. Hildebrand: Verhandl. d. deutsch. Gesellsch. f. Chir., 1893, p. 69.

3. Beckman, E. H., and Adson, A. W.: Collected Papers, Mayo Clinic, Philadelphia; W. B. Saunders Company, 1917.

4. Thorburn, W.: Oxford Surgery, iii.

5. Tubby, A. H.: Deformities.

6. Binnie, J. F.: Operative Surgery, Philadelphia; P. Blakiston's Son & Co., p. 716.

7. Bayer, C.: Ztschr. f. Heilk., Berlin, xviii: 405, 1897.

8. Roux, S.; Rev. med. de la Suisse Rom. xxxviii:47 (Jan.) 1918.

A MIXTURE OF ETHYL CHLORIDE, CHLOROFORM AND ETHER FOR GENERAL ANESTHESIA—AN EXPERIENCE IN WAR SURGERY

E. P. Quain, M. D.

BISMARCK, NORTH DAKOTA

The use of ethyl chloride as a general anesthetic is given but four scant pages in a recent volume written by Flagg on "The Art of Anesthesia." He describes briefly the technic for giving ethyl chloride as a sole agent for the induction and maintenance of general anesthesia, but it is evident that the main object of his description is to discourage its use because of its dangerous properties. He barely mentions certain "admirable properties as an adjuvant to chloroform and ether."

Having had no experience with ethyl chloride alone for general anesthesia, the writer can not discuss that feature. However, it was his fortune to be stationed at an Evacuation Hospital, No. 114, in the Argonne during the last month of the war and to have occasion to employ at this hospital, for general anesthesia, ethyl chloride in combination with chloroform and ether in a considerable number of cases.

The observations that were made in the use of this mixture, in the type of surgery which confronted the medical officer at the time, were very favorable. *It was uniformly declared to be the most suitable anesthetic for all minor injuries, as well as for wounds of medium severity. It was adopted at this hospital as the anesthetic of choice for practically all operations which could be completed within fifteen to twenty minutes. The speed of the operating team was therefore,*

in many instances, the criterion as to whether the choice should be the ethyl chloride mixture or simply ether.

DRAWBACKS OF OTHER ANESTHETICS IN WAR SURGERY

Nitrous oxide anesthesia was not practical for at least three reasons. Nitrous oxide gas was not readily

Fig. 1—Mask, Pieces of Flannel, and Graduated One-ounce Bottle.

obtainable; the apparatuses were usually out of repair; and a sufficient number of skilled anesthetists were not available.

The usefulness of the ethyl chloride mixture in war surgery was demonstrated by French surgeons in 1916. The use of this form of anesthetic was by no means universal in the French Army, but a certain number of their leading surgeons had become familiar with

the method and employed it throughout the last year of the war. It was introduced into a few American hospitals near the end of the war. So far as the writer has been able to ascertain, it was given a more extensive trial at our Evacuation Hospital than at any other American hospital. It was adopted for the cases already indicated at the request of Commanding Officer Lt.-Col. J. C. McCoy, who had acquired the technic from the French.

Although ether was used by the majority of the American surgical teams near the front, it was evident to all that it had several serious drawbacks, namely:

1. The time necessary to put the patient to sleep was often a total waste so far as the rest of the operating team was concerned. A quicker anesthetic would have enabled many surgeons to handle at least twice as many cases as they did in a given time. This was exceedingly important in view of the necessity of early prophylactic excision of the wounds before infection could become established in the tissues.

2. Many wounded came to the operation soon after eating. Ether anesthesia would usually not be effective in such cases until the stomach had been evacuated by repeated emesis with its attendant danger of aspiration.

3. Many wounded were suffering from colds, tonsillitis, pharyngitis, laryngitis, and bronchitis. It seemed doubly unfortunate to be obliged to administer ether to all such patients, especially as "the flu" infection was present at the time.

4. After a deep ether anesthesia, even of short duration, the patient required to be left in the hospital bed for a sufficient length of time to overcome the effect of the anesthetic. This was of importance to the incoming wounded, who sometimes had to remain on

the litters until those already operated on could be evacuated from the hospital.

VARIOUS E-C-E MIXTURES AND METHOD OF ADMINISTRATION

It was in respect to these objections that ethyl chloride, in combination with certain amounts of chloroform and ether, was found to have decided advantages over ether alone.

Different French surgeons employed slightly different proportions of ethyl chloride, chloroform, and ether. The mixture used by the writer was that recommended by M. Savariaud. It consists of ethyl chloride, 5 c.c.; choloroform, 1 c.c.; and ether, 24 c.c., making a total of 30 c.c. for each anesthesia. It was given by the closed method of administration in a rubberized bag. M. Savariaud devised a mask for this purpose, and Pellot and other surgeons made improvements on it to suit their fancies. We were unable to obtain any of these masks and were, therefore, obliged to improvise them out of materials at hand.

Our method of preparation and administration of the anesthetic was as follows:

A piece of very thin but strong rubberized linen is trimmed into an oblong or circular shape, 55 c.m. long and 65 c.m. wide. This is hemmed or faced around the margin so as to permit the introduction of a puckering string by means of which the oblong material can be drawn into a bag to fit over the face. A hole is cut in the center of the cloth about 2 c.m. square. Two oblong pieces of cotton flannel are prepared, each large enough to cover the patient's face. The mixture is then prepared in an ordinary one-ounce medicine bottle. A strip of adhesive plaster is fastened to the bottle, and on it is marked the 5 c.c., 6 c.c., and 30 c.c. levels. Ethyl chloride is put into the bottle from a

tube up to the 5 c.c. mark; 1 c.c. chloroform is added; lastly ether is poured in up to the 30 c.c. mark, and the liquid is thoroughly mixed.

METHOD OF ADMINISTRATION

1. One of the two pieces of cotton flannel is laid dry over the patient's face, and the other piece is placed in a cup or small pus basin.

2. The whole contents of the bottle is poured into the cup over the piece of flannel, which absorbs practically all the 30 c.c. mixture.

3. The piece of flannel is then rapidly picked up before evaporation takes place and spread out smoothly over the other piece on the patient's face. The patient must be told to hold his breath before the saturated cloth is approximated to the face and until the mask is properly adjusted.

4. The mask is placed over the face and the puckering string drawn tightly and tied so that the margin of the mask is held firmly around the face, under the chin, in front of the ears, and over the tip of the head. It is desirable that the mask be applied air-tight to the face, though practically this may be impossible, especially over the hairy part of the head.

As soon as the mask is applied the patient is directed to take short breaths. This will cause him to lose consciousness quickly from the ethyl chloride vapor as being the most volatile of the drugs used. If he gives evidence of struggling with his respiration when he fills his lungs more completely a few moments later, he will, as a rule, have forgotten it when the operation is over. The jaw muscles will occasionally become firmly set and may interfere somewhat with respiration at the beginning of the anesthesia and until the patient is fully asleep. To overcome this interference some anesthetists adopted the method of placing a

Fig. 2—The Mask Applied to the Patient.

cork, securely fastened by a string, between the patient's teeth before the mask is applied.

Unconsciousness comes very rapidly. After six to ten deep inspirations the incision can be made. The closed mask causes a continuous re-breathing and the respiratory center shows a distinct stimulation throughout the time of anesthesia. The inflow of air through the small opening in the center of the mask may be regulated by the anesthetist's fingers.

The anesthesia from the dose given lasted from twelve to twenty minutes in the average wounded doughboy. In the experience of the writer, if a certain surgical procedure could not be completed during this sleep, ether was added through the opening in the mask until the operation was finished. The French surgeons referred to did not hesitate to give a second dose of the same mixture when required. After the removal of the mask, the patient would wake up in a few moments. In cases where the location and severity of the wound did not form a contra-indication, the patient would walk out of the operating-room after five or ten minutes' rest on the table or on a chair.

REACTIONS OF PATIENTS

The anesthesia was highly satisfactory in the kind of work in which we were engaged. The fact that the patient was ready for incision within one minute after the application of the anesthetic, made it possible for the surgeon to work practically without intermission. After the completion of one operation, the anesthetist stepped to the next table where another patient was already waiting to be anesthetized. By the time the surgeon and his assistant had changed gloves, the anesthetist had prepared the mixture and was ready to apply the mask.

The patient would not always be completely relaxed. There would be, in some cases, slight involuntary muscular movements or quivering throughout the operation, but not enough to interfere seriously with the work. These spasmodic movements when present would be as marked in other parts of the body as in the part operated on, which tended to show that they were not due to painful impressions from the site of the trauma, but rather to the stimulating influence of the anesthetic. In some patients a short period of excitement was present after the first inspiration, and with others there would be a few minutes' exhilaration after the mask was removed.

There was practically no stimulation of mucus-formation in the throat, a very desirable condition in those suffering from laryngal or bronchial infection, and the proportion of these was very high. Nausea was evident in only a few and emesis took place while the patient was waking up in the few cases where it was present at all. Most patients who had walked to the operating table could and did walk away from it after a ten or fifteen minutes' operation.

RESULTS

We had no death from the anesthetic, no syncope, no alarming cyanosis, and no serious difficulty with respiration. Being in an evacuation hospital, it was, of course, not possible to observe the patients more than a few hours after operation, but from such information as could be obtained the after-results were satisfactory.

There were 400 patients operated on in all under this anesthesia, the majority of the operations being performed by the writer. The nature of the operations ranged from small excisions of superficial wounds to the removal of extensive lacerations, includ-

ing amputations of arms and legs. Intracranial, intra-thoracic, and intra-abdominal injuries were not treated under this form of anesthesia. Wounds on the face would, of course, exclude the use of this method.

There can be no reason why this ethyl chloride mixture should not be used in emergency surgery in civil practice when conditions and necessities correspond, more or less, to those of the wounded soldiers. The lessons learned from acute surgery which are of practical importance for civil practice are not many when we consider the great amount of surgery done at or near the front. The use of ethyl chloride as indicated above, is, in the opinion of the writer, one of these lessons.

DISCUSSION

Dr. E. D. Clark (Indianapolis, Ind.): We used a method of anesthesia much like the one described by Dr. Quain, in Base Hospital No. 32. I am not sure as to the proportion of ethyl-chloride, ether, or chloroform used, but the mixture was similar to the formula of Dr. Quain. The apparatus used was a rubber bathing-cap, to which was attached a broad rubber band that clamped snugly over the forehead and around the face and chin. About two ounces of the mixture was poured on gauze which had been placed in the cap. The apparatus was then quickly placed over the face. We had almost immediate anesthesia with little or no struggling. The anesthesia would last from five to fifteen minutes and was quite sufficient for secondary closures of wounds. We did many hundreds of these operations with the greatest satisfaction. We used it in many of our fracture cases, and all painful dressings were done with it. We rarely had nausea or other unpleasant results. We had no fatalities nor anything that approached it.

I heartily endorse this anesthetic for short surgical operations and for painful dressings.

Dr. E. M. Sala (Rock Island, Ill.): I had a rather interesting experience with ethyl-chloride, which I think is worth repeating because, it seems to me, it is a very useful anesthetic.

When I was on duty at Army Hospital No. 21, I was preparing to open an ischiorectal abscess under local ethyl-chloride anesthesia; I was not paying much attention to the anesthetist, I was getting ready to do the surgical work, and I noticed he placed the cone on the patient's nose and began to use an ordinary ether mask, such as we use for the drop method of ether. He did not close it up at all, and said he had given the anesthetic that way for some time for short work. I have been using that method ever since I came out of the army and consider it very fine. I do not believe it is necessary for us to add chloroform and ether. My results have been very good. I had a number of ethyl-chloride bulbs which were supposed to be enough for one anesthesia. You break one of these bulbs and it goes on the mask. I had some of these in my office before I went into the army. I broke three or four of these on the mask, and it did not have any effect, but the explosion seemed to scare the patient. After that I began using the ethyl-chloride bottle just the same as you would ether, and squirted it on the mask as if one was going to do a freezing operation, and the results have been very fine.

Dr. William T. Coughlin (St. Louis, Mo.): I have taken considerable interest in anesthetics for short operations. In 1911 I called attention to the ether rouge(?) which I use occasionally yet. I have used it successfully in over 2,000 cases, and I felt pretty well satisfied with it; then in 1915 I began to use pure ethyl-chloride, sprayed on. The technic of its administration is very easy. We wet a towel and fold it as one folds a towel around a patient's mouth when he puts on an ether mask. We lay not more than eight thicknesses of ordinary gauze over the patient's nose. The patient is instructed to keep his mouth closed, and then he is instructed to raise his hands, and we spray the ethyl-chloride onto the gauze square until the hand drops, and then the gauze is taken away entirely from the patient's mouth as the operation is begun. For short operations it has worked well. I have used it both in civil and in military practice. It became a fad for short operations at Hospital No. 1, in Paris, where I was stationed. We used it frequently for opening abscesses. I do not think I have ever used it for setting fractures, and the reason is one can never tell in advance how a patient's nervous system will react to it. A clonic spasm comes on rather more frequently than it does in using ether in the ordinary way. but not more frequently than clonic spasm is seen in using the ether rouge.

I am not quite sure I got the proper proportions from the doctor's paper of the chloroform, ethyl-chloride, and ether mixture. We started to use this mixture at Hospital No. 1. We had a very intelligent and ambitious woman who was the chief anesthetist on the upper floor, and she was anxious to find out all she could about the different anesthetics, and every once in a while some one came down who had been with the British and said they were using a mixture of chloroform, ether, and ethyl-chloride with satisfactory results. The proportions were about 1 and 20 and 4, or something like that. I think there were 26 parts altogether, 20 of ether 1 of chloroform, and perhaps 5 of ethyl-chloride. We were getting along very well with this mixture and had used it in approximately 100 cases when someone came in from the north who had seen some trouble happen from the use of the mixture, and I could not persuade our anesthetist to use it any more. She quit.

I have seen vomiting following its use in three cases, but only in cases, I believe, where the patient was brought to the operating-table with a full stomach. All three patients quickly got over it and were soon ready to take food again.

I have never allowed an assistant to give ethyl-chloride, and I do not even yet. We have used it in the clinics since 1915. We are using it at the City Hospital for short anesthesias, and so far we have no cause to regret its use. It is more pleasant to take than ether alone, and a patient does not struggle nearly so much as he does when his head is put in a closed mask while giving the ether rouge. The patient goes to sleep quickly, and very seldom is there any vomiting.

I would not give any of these anesthetics to a patient with high blood-pressure, nor would I give these anesthetics to a patient that I thought belonged to the class known as status lymphaticus.

Dr. Emil G. Beck (Chicago, Ill.): Was death due to this anesthetic in the case which was reported to the nurse?

Dr. Coughlan: There had been a sudden death on the table, and for that reason we quit its use.

Dr. Quain (closing): Patients have died during operations from many causes outside of the harmful effect of the anesthetic. This was especially true in war surgery. It would hardly be fair to lay the death on the table mentioned by Dr. Coughlan up against ethyl-chloride unless we know all the circumstances in connection with that particular case.

It is important that only *pure* ethyl-chloride be used for general anesthesia. Only the product placed on the market by reliable pharmaceutical houses and marked "for general anesthesia" should be employed. Ethyl-chloride in metal containers should be avoided because ethyl-chloride undergoes a chemical change with practically all metals. Glass containers are safe in this respect.

The ideal way to give this mixture is to give the patient, first a few inhalations of ethyl-chloride on a mask, and then at the moment when unconsciousness is coming on to change quickly to the mixture described.

Its use in the reduction of fractures of the large bones will probably not meet with uniform success; but there are many fractures of smaller bones, including those of the forearm, in which you will find this anesthesia all that can be desired.

The inhaler I passed around is, of course, only a makeshift, but at that it was found very practical and useful. For office or hospital use the Stark inhaler or its equivalent will be a more convenient and satisfactory apparatus.

The narcotic effect of somnoform is due chiefly to the ethyl-chloride it contains (60% by volume). As you know, dentists are using ethyl-chloride, mostly in the form of somnoform, very extensively and in spite of the apparent recklessness with which they give it, you have rarely, if ever, heard of a death from its use. As surgeons, I believe, we have overlooked the general anesthetic properties and the fairly extensive field of usefulness of this drug.

RHINOPHYMA

M. G. Seelig, M.D., F.A.C.S.

ST. LOUIS, MISSOURI

Rhinophyma is an essential disease of the nose, of more than ordinary interest. The gross characteristics of the disease and the resultant disfigurement are, in the first instance, striking. From the purely clinical side, the uncertainty and possible multiplicity of the etiological factors adds interest. From the pathological side there is presented the interesting problem of deciding whether to classify the disease as an inflammatory hypertrophy or as a frank neoplasm, and finally, from the historical point of view, the disease stimulates unusual and fascinating interest, owing to the part played by the old masters of classical painting and satire in picturing the disease on canvas and in prints.

From the clinical side, rhinophyma might be described fairly accurately if one merely set down the various descriptive terms which have been used in naming the disease: whiskey nose, pound nose, nodular nose, growing nose, copper nose, elephantiasis of the nose, hyper--trophy of the nose, lymphangioma, acne hyperplastica, fibroma molluscum and cysto-adenofibroma. In the earliest stage of the disease the nose is a dark copper-red, and there are dark red spots about it, particularly on the cheeks and at the glabella. Gradually there appear on the nose lentil-size to pea-size discrete or confluent nodules. As these nodules coalesce and the soft parts hypertrophy, the whole organ becomes deformed by the tumor-like nodules. The deforming growths occur usually at the tip and on both alæ, and may be discrete and lobulated, or they may fuse, form-



Fig. 1.



Fig. 2.



Fig. 3.

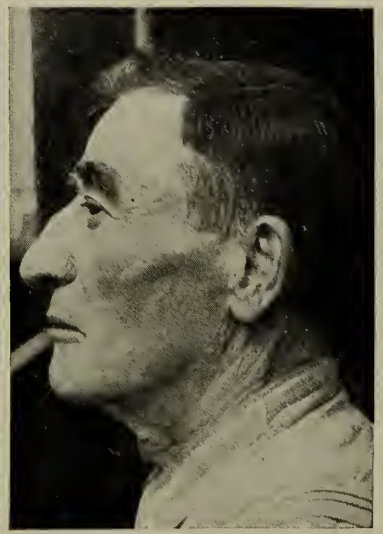

Fig. 4.

Fig. 1. Rhinophyma before operation.
Fig. 2. Profile, same patient.

Fig. 3. Same patient after operation.
Fig. 4. Profile, same patient after operation.

ing one large knob. Sometimes they are pedunculated. Von Bruns reports a case in which the growth reached to the chin, and had to be held aside when the patient partook of food or drink. As a rule there are only three irregularly rounded lobulated growths situated at tip and alæ, but sometimes there are many small lobes separated by deep furrows. The nodules are usually soft and are coursed by dilated veins, and studded with comedones and acne pustules. Owing to the activity of the sebaceous glands, the surface of the nose presents an oily varnished appearance, and seems to be pitted by the wide open mouths of these glands. Pressure on the nodules causes macaroni-like plugs of sebum to worm out from the sebaceous glands.

The disease occurs usually in the fifth and sixth decades, that is, the deformity is complete at these periods, the process having taken five to twenty years to develop fully.

There probably is no relationship between the disease and alcoholism. An analysis of the cases shows that there is an infinitesimally small number, compared with the number of alcoholics; and that many cases of rhinophyma occur in non-drinkers.

The commonly accepted opinion is, that rhinophyma, pathologically speaking, represents the terminal stage of acne rosacea that has passed through acne hypertrophica. In many instances the disease seems to rest on a congenital basis. Lassar believed that there was a predisposition to rhinophyma in wide-pored individuals. The essential pathological process is an hyperplasia of the connective tissue of the soft parts of the nose, accompanied by a dilation of the blood vessels and hypertrophy or cystic degeneration of the sebaceous glands. The skin follicles show, in places, distinct evidences of suppuration. The openings of follicles and of the ducts of the sebaceous glands are wid-

Fig. 5.

Fig. 6.



Fig. 7.

Fig. 5. Unknown subject, painted by Holbein the younger (1497-1553). Hangs in the Parado of Madrid. (From Hollaender.)

Fig. 6. Portrait of supposed grandfather and grand-child by Ghirlandajo (1449-1494). Hangs in the Louvre. (From Hollaender.)

Fig. 7. Unknown sitter by a Holland master, in Museum at Stockholm. (From Hollaender.)

ened, so that they resemble deeply-pitted pores, often giving to the nose the appearance of a sponge. No one has ever satisfactorily demonstrated the cause of the disease. Kaposi sought to prove that the connective-tissue growth, blood-vessel dilation, and sebaceous-gland degeneration were all secondary to an angio-neurosis; but there is no marked consensus of opinion concerning this theory. Trendelenburg considered the disease as a new growth and grouped it under the head of fibroma molluscum; Lassar considered it a cysto-adenofibroma.

I am indebted to Dr. Martin Engman for the privilege of quoting from the advance sheets of his forthcoming book on "Diseases of the Skin." Dr. Engman from an intensive study of rhinophyma, draws the following conclusions regarding the pathology of the disease. "Rhinophyma is a familial disease representing some type of hereditary transmission. It occurs usually in the seborrheic type of individual. (The seborrheic type of Sabouraud may be described as an individual with yellowish-tinted, muddy, thick skin, the yellowish tint being most pronounced around seborrheic areas, with a tendency to acne vulgaris in youth and acne rosacea in middle life.) The future rhinophyma subject shows a tendency toward flushing of the face, on entering a warm room, after meals, or under excitement. This flushing leads, in time, to a chronic congestion, with secondary chronic infection of the skin of the nose and sometimes of the cheeks. This in turn leads to a chronic productive inflammation, with vascular dilation, connective-tissue formation, and dilation of the sebaceous glands into cyst-formations. There is a marked thickening of the cutis vera, which throws the skin into folds and furrows. The end-result is the multiple formation of knobs or tumor-like masses."

Fig. 8.

Fig. 9.

Fig. 10.

Fig. 8. Print of Gerhard Janssen, an old glass etcher of the middle 17th century. (From Hollaender.)
Fig. 9. A caricature from the 17th century. One of the so-called Kings of Noses. (From Hollaender.)
Fig. 10. A caricature of a physician, published about 1700 in Augsburg. (See text for translation of legend.) (From Hollaender.)

The treatment of the disease is exclusively operative. The occasional recommendation to practice wedge-shaped excisions, should be ignored. The most satisfactory operative procedure consists in shaving off the redundant tissue until the nose is brought back to what one assumes was its original form. In this shaving process, two things should be borne carefully in mind: (1) Do not shave too deeply, and (2) preserve a thin rim of epithelium around the nares. If the shaving is carried too deeply, we remove all sebaceous-gland rests and leave no niduses of epithelium from which, as brood centers, epithelization may spread. This delays healing, and, even if the nose be grafted, the resultant skin has a harsh, white, dry appearance, so striking as always to command attention and cause comment. Furthermore deep shaving may injure the nasal cartilages and set up a stubborn perichondritis. If a thin ring of intact skin is not left around the nares, serious disfigurement may result from the contractions incident to cicatrization. Hemorrhage, which is usually very free, is checked with comparative ease by simple gauze pressure, and the patient is sent to bed with a large, well-vaselined gauze pad over his nose. The next day this pad is removed, and the denuded area is strapped with imbricated strips of sterile zinc oxide adhesive plaster. This plaster dressing is changed daily. Under this simple dressing, my patient, shown in Figures 1 to 4, was completely healed in ten days. It is not necessary to skin-graft these patients. Indeed von Bruns points out that grafting often leads to the development of retention cysts underneath the grafts, with subsequent breaking through and ulceration.

The rôle that rhinophyma plays in medical history and in classical medical art and caricature is not totally without interest even to a group of practical surgeons. Dr. Eugen Hollaender in his two volumes

devoted to "Medicine in Classical Art," and "Caricature and Satire in Medicine" furnishes some striking copies of pictures that feature rhinophyma.

Hans Holbein, 1497-1553 (known as Holbein the younger), famous in medical art as the painter of the *Dance of Death,* painted the portrait of an unknown subject. (Fig. 5.) The portrait, which hangs in the Prado at Madrid, shows an old man with a typical rhinophyma, and the characteristic red, congested color scheme which goes with this disease. Hollaender states that the coloring seems to have been toned down by the artist, in order to minimize the existence of the disease as much as possible.

Domenico Ghirlandajo, 1449-1494, the famous Florentine artist, has a picture in the Louvre illustrating rhinophyma even more typically. (Fig. 6.) Hollaender's speculations on this particular picture are interesting rather than convincing. He queries as to whether the small tumor on the right brow of the old gentleman may not be intended as a metastasis, thus hinting at the possible belief that rhinophyma was at that time considered to be malignant. Then, further, he speculates as to whether the beautiful child's head was intended to soften, by contrast, the jarring asymmetry of the bulbous nose of the old gentleman or whether the perfect featured little granddaughter was used to disprove the familial nature of the disease.

Hollaender presents these two pictures (Figs. 5 and 6) and the picture by an unknown Holland master (in the museum at Stockholm, Fig. 7) to illustrate the fact that they are pure portraiture, artistically executed without a semblance of caricature. These portraits may stimulate a sense of sympathy, but they make no appeal whatsoever to the risible in our make-up.

By contrast, Figure 8 leads away from art, into the field of caricature. This old rhinophyma subject,

Gerhard Janssen by name, was a master glass etcher, born in Holland and trained in his art at Dresden, 1650-54. The print itself is not a caricature, but the descriptive phrases engraved about it[1] furnish a caricaturish setting; such phrases, for example, as the

Fig. 11. Chief Wa-Ha-Gun-Ta (American name is Capt. John Smith) of the Chippewas. Still living, and an active hunter in Glacier Park, at an approximate age of 127 years. Rhinophyma is fairly common in American Indians.

[1]The legend about the frame is as follows:

A misshapen nose indeed, but a man of talent and wisdom. Art, work, and industry bring praise and reward.

The legend underneath the picture is:

Herr Gerhard Janssen, former court glass painter, and also experienced in the Damascan art of glass etching. Born in Utrecht, Holland, 1636, July 21; studied at Vreden in Westphalia, from 1650 to 1654. Removed to Vienna in 1662 where he died in 1725, June 3, at the age of eighty-eight years, ten months and eight days. God rest his soul. This print drawn and etched July 25, 1725, by U. D. Metzger, learned in his art, from Speyer, in the Palatinate but at this time residing in Maria Hof, fifteen minutes from Vienna.

legend just above the head *Nasutus sed acutus* (large nosed but wise) and the sentence in the frame, *"Es ist wahr ein unfoermliche Nase, aber sinnreicher Verstand* (a misshappen nose, 'tis true, but talented and wise).

The next two prints are frank caricatures. Figure 9 is from an old 17th century pamphlet and is a Simon-pure bit of what Hollaender calls naive lack of humor of this period. This king of The Large Nosed stands surrounded by all sorts of impossible things, people, animals, a large horn, a mercury's staff, a shepherd's staff, ships, etc., and points proudly to his rhinophymistic organ.

Figure 10 is an even grosser caricature, and represents the tendency at this particular time (late 1600) to use the doctor as a scape-goat and harlequin in jokes and on the stage. This large-nosed doctor, with what might be construed as a rhinophyma knob at the proximal and middle third of his proboscis, proclaims:

"For healthy people, I am a doctor, God help the Sick.

My large head-gear embraces profound and numerous thoughts.

My costume connotes the art that I possess.

What may be concealed in the urine, my long nose detects."

And finally, Figure 11 is not without interest from an ethnological point of view. Rhinophyma is fairly common in the American Indian. This is a portrait of Wa-Ha-Gun-Ta, chief of the Chippewas (photographed by Mr. William Burton of St. Louis, who kindly loaned me this copy). There are authentic records to show that the chief is about 127 years old, and as far as the memory of man runs he has had a typical rhinophyma.

Dr. Emil G. Beck (Chicago, Ill.): I think the pictures shown by Dr. Seelig speak for themselves, and the method he has described and carried out in the treatment of these cases is a very efficient one.

I have had the opportunity to see the work done by my younger brother (Dr. Joseph C. Beck), who has had a number of these cases for treatment, and he has also used this method of shaving. I do not know whether he used adhesive plaster afterwards or not, but I have seen some of the results he has published, and it is remarkable how pleased these patients are. The man who has a nose like those that have been shown is very unhappy, and if such a result as Dr. Seelig has shown here can be obtained, there ought not to be many men going around with rhinophyma.

THE OPERATIVE TREATMENT OF VESICO-VAGINAL FISTULÆ

E. S. Judd, M. D., F. A. C. S.

ROCHESTER, MINNESOTA

Fistulæ between the bladder and the vagina are the result of difficult parturition, or some operative procedure, most often the extirpation of the uterus for cancer. In the early days most of the cases of fistula that were under observation were the result of trauma at the time of childbirth. It was in the treatment of such cases that Sims developed the first accurate operative technic for their repair. In later years, however, several factors have arisen to change conditions materially. In the first place, better obstetric management has greatly reduced the number of fistulæ which occur as the result of difficult labor, but there has been a great general wave for the radical extirpation of cancer both by operative procedure and by cautery and large doses of radium. While the ultimate results of these operations and treatment warrant the procedure, they very greatly increase the number of cases of vesicovaginal fistula. Sampson, in 1904, reported 19 cases following 158 hysterectomies for carcinoma of the cervix, while a review of the cases in which we have operated since 1908 shows that 61 per cent resulted from some operative procedure for the removal of tumors of the uterus, and only 39 per cent followed childbirth. These percentages undoubtedly would be different in a strictly obstetric and gynecologic clinic, but they indicate the cause of the fistulæ generally seen.

The occasional satisfactory result of the treatment of a carcinoma of the cervix which is extensive and

involves the vaginal mucosa, undoubtedly warrants the continuance of treatment in such cases. The apparent complete disappearance of a large cauliflower cancer of the cervix after a few treatments with radium is most striking, but these treatments should not be undertaken without considering the fact that a fistula from the bladder may result from the use of radium alone, as well as from operation or cautery. If the malignancy is eradicated so that the fistula may be repaired satisfactorily the operation is certainly justified, but, if the patient is left without control of the urine and with malignancy persisting in the edges of the fistula or evident in other places, the treatment cannot be justified. For this reason the extent of involvement must be studied carefully to make sure that the patient has some chance of relief before the additional risk is taken. Radium has been a great help in the treatment of cancer of the cervix, and ordinarily it can be used without the danger of injury to the bladder, although there are five cases in our series in which the fistulæ followed the use of radium alone.

The scar resulting from the cautery or radium renders the technic of the operation much more difficult than in the cases which follow childbirth. The scar from the use of the cautery is thick and firm, and it is very troublesome to free the tissues so that the flaps may be approximated and sutured. The flaps tear readily so that care must be taken in forcing the needle through them. The scar resulting from the trauma of parturition is much smaller and the tissues are much more pliable and easier to suture.

The apparent ease with which vesicovaginal fistulæ may be closed is deceiving sometimes, and, unless definite principles are followed, the results will not be uniformly satisfactory. Too many times, I believe, an attempt is made to close the opening before dissecting the bladder wall well away from the vaginal

wall. In some instances it may be possible to close the opening in this manner, but I agree with recent writers on the subject who emphasize the fact that the underlying principle of the technic of the operation

TABLE I.—Type of Urinary Fistulæ Operated on from January, 1908, to September, 1919.

Vesicovaginal	67
Vesico-ureterovaginal	6
Vesico-uretero-uterine	1
Vesico-uterovaginal	5
Vesico-urethrovaginal	3
Total	82
Age of youngest patient	19 years
Age of oldest patient	64 years

TABLE II.—Causes of Fistulæ

Childbirth	32	(39 per cent)
Operation	50	(61 per cent)
Hysterectomy	31	(13 in our clinic)
Percy cautery (not hysterectomy)	4	(2 in our clinic)
Excision of cervical stump	3	(0 in our clinic)
Percy cautery and radium for recurring cancer (previous hysterectomy)	3	(2 in our clinic)
Amputation of cervix	2	(0 in our clinic)
Litholapaxy through urethra	2	(0 in our clinic)
Puncture drainage of bladder for cystitis	3	(0 in our clinic)
Abscess drained through vagina	2	(0 in our clinic)
Total	50	17
Shortest time between occurrence and repair	3 weeks	
Longest time between occurrence and repair	24 years	

is the separation of the wall of the bladder from the wall of the vagina. The condition which keeps the fistula from healing of its own accord is the fact that the mucous membrane of the bladder and vaginal wall

have healed together, thus forming a continuous mucous membrane surface from the bladder to the vagina. The first essential in the treatment consists in destroying the communication, and the best manner of accomplishing this is completely to dissect the bladder away from the vagina as is done in the operation for the relief of cystocele. If the mucous membrane of the fistulous tract is not freed so that it can be turned into the bladder on the one side and into the vagina on the other, the communication will almost certainly reform. A review of our cases shows that often several operations have been necessary before the fistula closed permanently. Sixty-eight per cent of our patients had been operated on from one to seven times before coming to the Clinic. In most instances these operations had apparently been done well; in others, I believe, the operator had been deceived into performing an operation by its apparent simplicity. Undoubtedly, a certain percentage of these patients require more than one operation, and, I believe, we are justified in repeatedly attempting to try to close the fistula if the sphincter muscle has not been destroyed. If the urethra and the sphincter muscle are destroyed, there is nothing to be gained in operating to close the fistula, as the urine will continue to escape. At times the urethra may be destroyed and the sphincter be intact; in these cases the operation should be performed, as the absence of the urethra will not cause any great inconvenience. In other cases the sphincter may be divided or torn by trauma, and there is every likelihood that the sphincter will functionate if it is repaired; therefore operation to close the fistula and repair the sphincter should be done. It seems to me that the operability of these cases depends on whether or not there is a sphincter muscle. Even though it is severed, any number of attempts should be made to repair it before the only other feasible procedure is advised, that is,

some plan of diverting the urine to the rectum, thereby leaving it under the control of the rectal sphincter. This may be done if the sphincter of the bladder is completely destroyed. Probably Keen's plan is the best one to adopt in these unfortunate cases, that is, to make a large communication between the vagina and the rectum just above the anal sphincter, and then close the vaginal outlet. In Keen's case the woman defecated and urinated for more than thirty-five years and menstruated for eleven years by rectum. Peterson collected forty-one cases in which this operation was performed with comparative success. In one case only the patient died of a kidney infection, and that was some months after the operation. The infection was not believed to be due to the entrance of organisms from the colon to the bladder.

The basis of this review is the 78 cases in which operation was done in our Clinic from January, 1908, to September, 1919.[1] In 54 of these cases it was possible to close the fistula at one operation; in 16 two operations were performed, and in 1 six operations failed completely to close the fistula. The fistulous opening in these cases varied from the size of a small pin-point to complete eversion and prolapse of the bladder. Complete prolapse of the bladder into the vagina occurred in 2 cases, one following childbirth in which several operations had formerly been done, and one following combined cautery and radium treatment for cancer of the cervix. In the first case the fistula was repaired successfully, but in the second case the repair was not complete; the entire anterior part of the rectum had been destroyed by the use of the cautery, and it was impossible to keep the field of operation clean.

In 75 cases the fistulous opening was single; in the other 3 cases there was more than one opening. The multiple fistulæ did not offer any more difficulties than

the single. A large incision in the vaginal wall included all the openings and converted the operation into a single closure after the openings into the bladder had been separately closed.

TABLE III.—Operations Elsewhere

Repair attempted before coming to clinic in..... 44 cases
13 patients had had 1 operation.
15 patients had had 2 operations.
6 patients had had 3 operations.
4 patients had had 4 operations.
3 patients had had 5 operations.
2 patients had had 6 operations.
1 patient had had 7 operations.
No previous operation for repair of the fistulæ.... 38 cases

TABLE IV

Patients operated on in the clinic..... 78
54 patients had 1 operation.
16 patients had 2 operations.
4 patients had 3 operations.
1 patient had 4 operations.
2 patients had 5 operations.
1 patient had 6 operations.
Inoperable recurring carcinoma of the bladder ruled out, plastic operation in..... 4 cases
The fistulæ varied from a very small opening to complete eversion and prolapse of the bladder.

TABLE V.—Extent of Involvement

Bladder sphincter ..... 10 cases
Bladder sphincter completely destroyed..... 3 cases
Ureter ..... 6 cases
Single fistulæ ..... 79 cases
Multiple fistulæ ..... 3 cases

TABLE VI.—Type of Operation

Plastic closure: Layer suture; dissection of fistulous tract and closure; inversion of edges by tension through meatus ..... 69 cases
Suprapubic operation ..... 5 cases
Transplantation of the ureter..... 3 cases
Ureter ligated ..... 1 case

The bladder sphincter was involved in 10 cases, but it was destroyed in only 3; it was repaired quite satisfactorily in the 7 cases.

One of the ureters was involved with the vesical fistula in 6 cases. I believe that it is very important

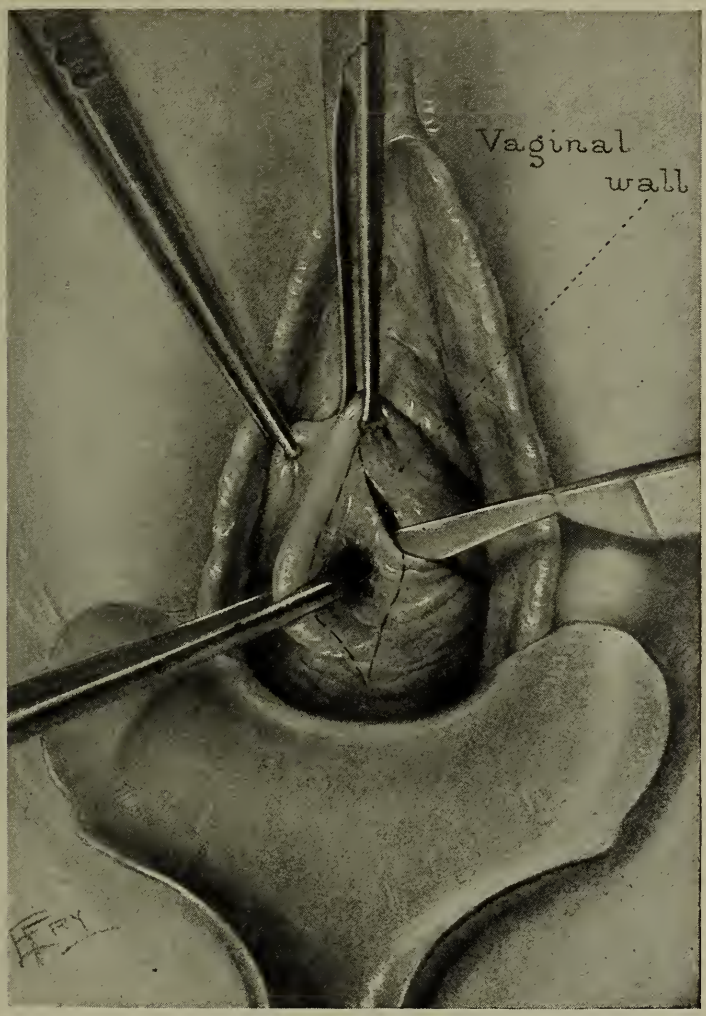

Fig. 1. Dotted line indicating area around fistula to be incised.

to determine the relationship of the ureters whenever it is possible. In a few instances the opening of the ureter was found close to the edge of the fistula, and it was possible to turn it into the bladder, or at least avoid injuring it. In several cases in which the ureter

was involved the suprapubic operation was performed; the ureter was transplanted if it appeared to be in good condition, and the opening of the vesical fistula closed. In one of these cases the ureter was thickened and evidently had been completely occluded for a long time so that it seemed advisable to ligate it.

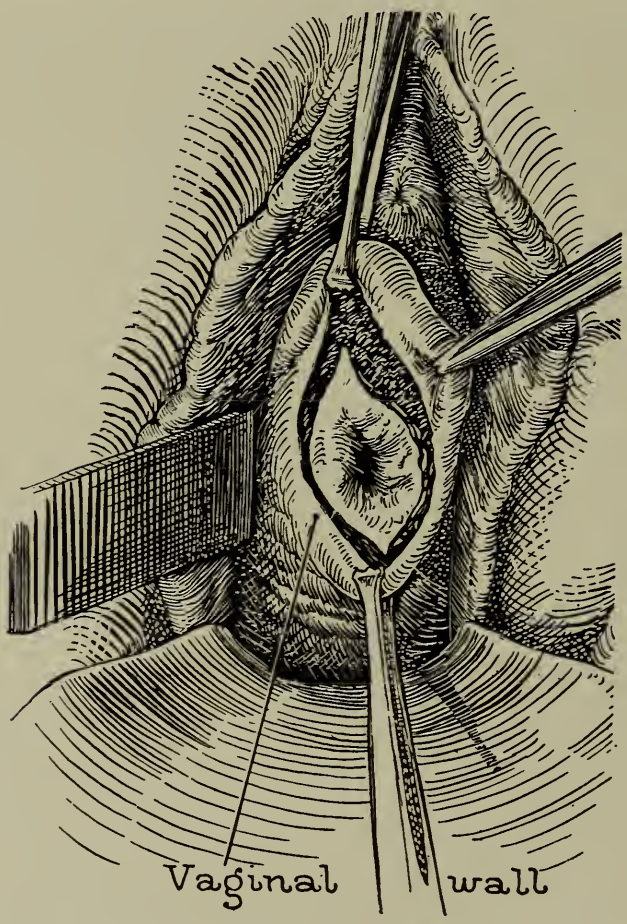

Fig. 2. Incision completed and vaginal wall retracted.

In all cases in which the suprapubic operation was selected, it was selected for some special reason; it was not employed generally in vesicovaginal cases. The patients on whom the suprapubic operation was performed have all done well, and their convalescence was more favorable than might have been expected. While the suprapubic operation offers a good chance for cure, it also offers a greater opportunity for infec-

tion, and should not, therefore, be chosen unless especially indicated. Our suprapubic operations were performed extraperitoneally.

Trendelenburg is credited with having performed the first suprapubic operation for vesicovaginal fistula in 1890, and, according to Ward, twenty-seven such

Fig. 3. Dissection of the wall of the vagina from the wall of the bladder.

operations were reported within the next fourteen years. Fewer operations have been reported during the past fifteen years, probably on account of the added risk of infection.

Legueu has recently advocated the transperitoneal vesical route for operation in cases of vesicovaginal fistula. One of his twelve patients operated on by this method died. He claims, for this method, wide exposure and every security for healing since in making closure the bladder incision is covered by peri-

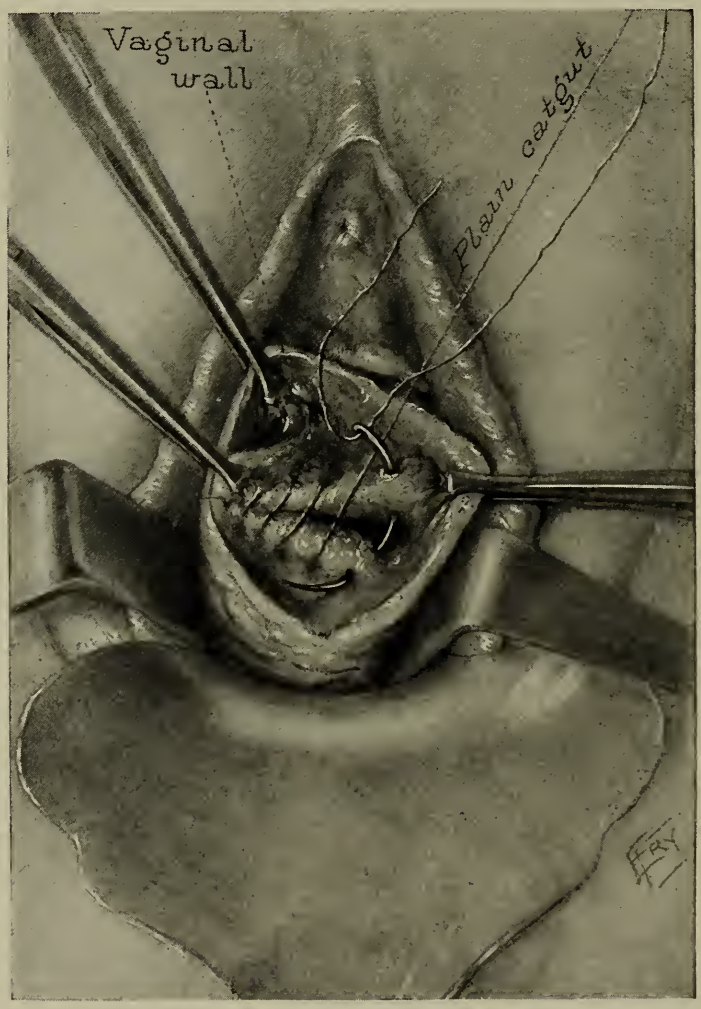

Fig. 4. Suturing the wall of the bladder.

toneum. Such suprapubic operations undoubtedly should be carried out in some of the very bad cases, especially if the ureter and bladder are traumatized. In certain instances the fistulous tract becomes attached to the pubic bone and is thus held in a most

inaccessible position, making closure difficult by the vaginal route. In some of these cases the suprapubic operation can be used to advantage.

In most instances cases of vesicovaginal fistula can be dealt with satisfactorily by making plastic closure of the fistulous openings through a vaginal incision. If the opening is small the technic described by C. H. Mayo may be followed, that is, inverting the fistula into the bladder. The inverted fistula is held in the bladder by tension on the purse-string suture, which is pulled out through the urethra.

Dr. Crenshaw, of our staff, has closed a number of small vesicovaginal fistulæ by the use of the high-frequency current. If the fistula is small it is well worth while to try this method before attempting an operation.

Before an operation is undertaken, an effort must be made to get the tissues in the best possible condition for healing. This frequently requires several weeks since often the mucous membrane of the vagina, the labia, and even the skin of the thighs are excoriated and infected, and contain deposits of salts. A cystoscopic examination should always be made in order to determine the position of the ureters, the presence or absence of a sphincter muscle, and whether or not the bladder is completely severed from the urethra. One of the greatest difficulties encountered is trauma to the vesical neck. The vaginal operation certainly should be chosen in all cases of injury near the neck of the bladder, the part difficult to expose by suprapubic incision, so that in such injuries this incision would be distinctly contra-indicated. If the opening in the bladder is high in the vaginal fornix and especially if there is much scar tissue, as there is apt to be following cautery or total hysterectomy, it will be difficult to obtain sufficient exposure by vaginal incision, and in some instances it may seem best to

perform the suprapubic operation. The fistula can usually be made accessible, however, so that the operation may be done through the vagina. Very often the perineum is badly torn, and incision into it for exposure is not necessary, but, if the incision is necessary, it should be made unhesitatingly, and the openings closed at the completion of the operation. One of the

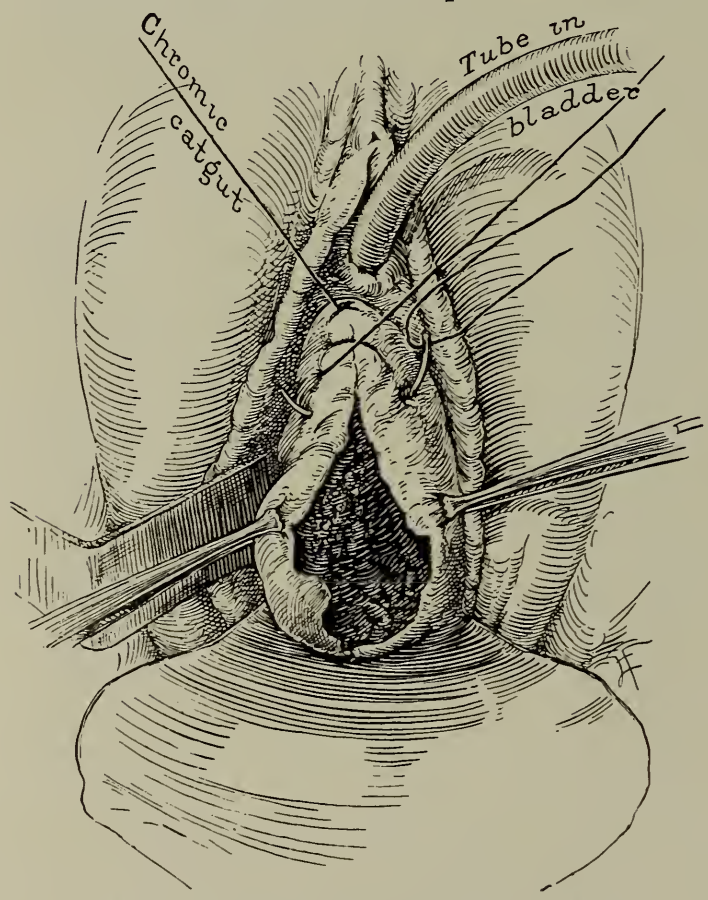

Fig. 5. Suturing the wall of the vagina.

chief steps in this procedure is a long incision in the vaginal wall down to the bladder. Usually the incision is begun immediately below the sphincter muscle and extended to and through the fistulous opening, after which the bladder is separated from the vagina for a considerable distance. (Fig. 1.) I have found it easier to begin this dissection as near the cervix as possible and to bring it forward toward the urethra.

Unless this step is thoroughly carried out, the chance for a cure is not good. If the cervix has not been removed, downward traction should be exerted upon it as this helps materially in the exposure. (Fig. 2.) If the cervix has been removed and the fistula is high in the vagina, it may be best to open the peritoneum

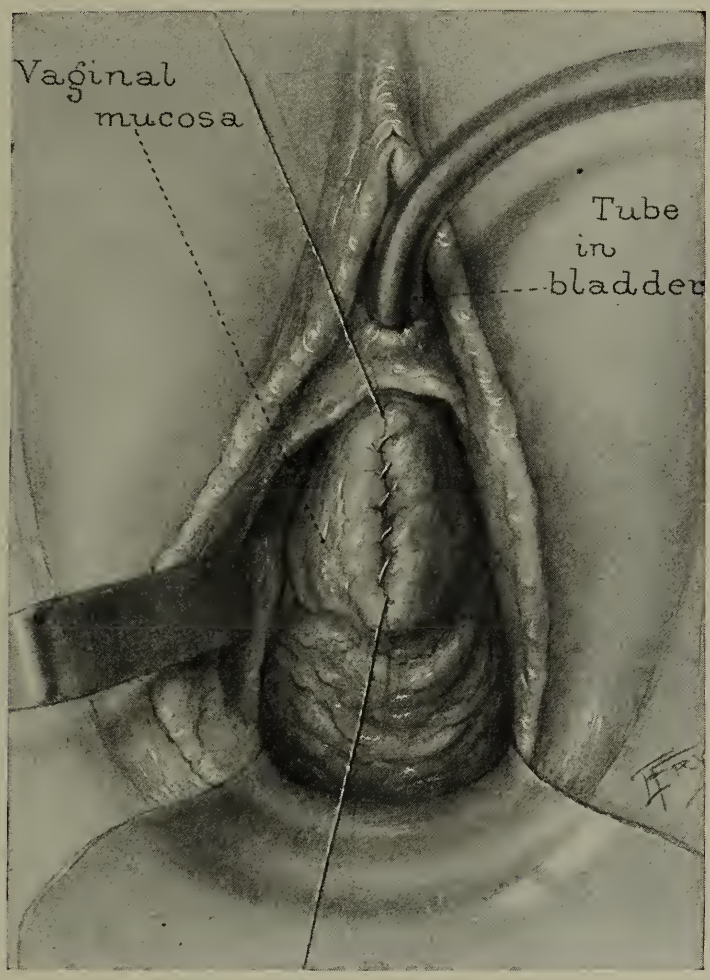

Fig. 6. Closure of the wall of the vagina.

widely in order freely to mobilize the bladder and bring the fistula into view. Several years ago Kelly suggested opening the peritoneum and I have followed this method a number of times to great advantage. It must be remembered that loops of intestine are usually caught in this scar and are apt to be injured. This

accident happened in one of my operations, but I was able to repair the opening in the intestine without much trouble. Ordinarily, I do not believe that it is necessary to open the peritoneum, but in almost inaccessible cases it is helpful. Slight infection may follow, although it was not a complication in my cases. In one case in which I did not open the peritoneum the patient developed a fecal fistula through the vagina, and I was obliged to repair it by abdominal procedure.

A small curved hemostat passed through the urethra and into the vagina through the fistula has helped us most to bring the fistulous tract downward into the dissection. The dissection of the bladder should be carried on until the wall is loose and free and until the edges can be easily approximated. (Fig. 3.) In the cases of extensive injury this is sometimes impossible, and it then seems best to close the bladder opening as completely as possible without using tension on the sutures; complete closure can be made later. If too much dissection and tension is employed the circulation to the flaps will be reduced, and sloughing of the tissues will occur. Fortunately, many of the tissues may be separated without harm. It is better to perform two or three operations than to carry the procedure too far at one time. The opening in the bladder should be closed with catgut and the edges of the mucous membrane inverted. (Fig. 4.) The vaginal incision should be closed with chromic catgut and all dead space between the bladder and vagina obliterated. (Figs. 5 and 6.) In case the sphincter has been repaired or the urethra sutured back to the bladder it is best to use fine silk sutures in addition to the catgut, being cautious not to penetrate the mucous membrane with the silk.

A retention catheter is left in the bladder for from eight to ten days, and great care must be taken to

make sure that it drains properly. Patients should be kept quiet for from twelve days to two weeks.

There was no mortality in this series of cases, and the ultimate results were very satisfactory in a large percentage. We have recently received information concerning 56 of the 78 patients. Four state that they have derived no benefit from the operation; 6 are considerably improved, although there is still slight incontinence of urine. All the other patients are completely relieved, and the bladder function is normal.

In conclusion I wish to emphasize points as follows:

1. Vesicovaginal fistulæ are now more common following operations than following childbirth.

2. All vesicovaginal fistulæ should be considered operable as long as the sphincter muscle of the bladder is intact or can be repaired. If the sphincter has been completely destroyed it will be necessary to consider some other procedure.

3. Suprapubic extraperitoneal operations seem to be indicated if the cystoscopic examination reveals injury to a ureter as well as to the bladder, or it may be indicated if the fistulous tract is adherent to the pubic bone.

4. The plastic vaginal operation consists in completely separating the bladder from the vagina, and closing the two separately and obliterating all dead space.

5. A large percentage of complete and permanent cures follow such operations.

BIBLIOGRAPHY

1. Crenshaw, J. L.: Personal communication.

2. Keen, W. W.: A case in which for over thirty-five years a woman defecated and urinated and for eleven years menstruated by the rectum. Med. Rec., 1919, xcvi, 352.

3. Kelly, H. A.: The treatment of vesicovaginal and rectovaginal fistulæ high up in the vagina. Bull. Johns Hopkins Hosp., 1902, xiii, 73-74.

4. Legueu, F.: De la voie transpéritonéo-vesicale pour la cure de certaines fistules vesico-vaginales. Bull. et mém. Soc. de chir., 1919, xlv, 170-175.

5. Mayo, C. H.: Repair of small vesicovaginal fistulæ. Ann. Surg., 1916, lxiii, 106-107.

6. Peterson, R.: Substitution of the anal for the vesical sphincter in certain cases of inoperable vesicovaginal fistulæ. Surg., Gynec. & Obst., 1917, xxv, 391-402.

7. Sampson, J. A.: Vesicovaginal fistulæ following hysterectomy for carcinoma cervicis uteri, with special reference to their origin and closure. Bull. Johns Hopkins Hosp., 1904, xv, 285-292.

8. Sims, J. M.: On the treatment of vesicovaginal fistula. Am. J. M. Sc., 1852, xxiii, n. s., 59-82.

9. Trendelenburg, F.: Ueber Blasencheidenfisteloperationen und ueber Beckenhochlagerung bei Operationen in der Bauchhoehle. Samml. klin. Vortr., 1890, No. 355.

10. Ward, G. G.: The operative treatment of inaccessible vesicovaginal fistulæ. Surg., Gynec. & Obst., 1917, xxv, 126-133.

11. I am greatly indebted to Dr. R. G. Andres for his careful study of our case records and the resulting data.

DISCUSSION

Dr. Joseph Rilus Eastman (Indianapolis, Ind.): I have had fairly good success in dealing with vesicovaginal fistulæ as compared with the not especially brilliant success I have had in other departments of surgery, and I ascribe it perhaps to the use of an efficient retention-catheter. I have made a slight modification of the retention-catheter. The Skene's catheter has a large olive bulb end, which projects into the bladder, and has small openings, which close promptly, as a rule. When the catheter is placed in the bladder, if the little openings are filled up with incrustations, and the catheter must be removed and cleaned and re-inserted, it causes a great deal of annoyance and may make for failure of the operation. So I have a Skene catheter made in this way (illustrating by diagram on the black-board), using four posts of wire like this (indicating), which leaves the lumen of the catheter perfectly free, so that we have ample drainage of the bladder at all times. It is perfectly clear, of course, that one must divert the urine so that it will not have any tendency to go through the fistulous opening if we hope to achieve success.

The use of silver wire in closing vesicovaginal fistulæ is worthy of our careful attention. It may be a violation of a surgical principle to use silver wire in movable tissues, but I think it is rather to be regarded as a contravention of a surgical dogma. The early history of gynecology in this country has, as one of its most interesting features, the story of the work done by J. Marion Sims in negresses in the

South in the closure of their vesicovaginal fistulæ which, as you know, were very numerous. That experience of Sims is well known to you, so that it is perhaps trite for me to mention it, but it is important. Silver wire is not only aseptic, but it is antiseptic. You can prove that by cutting bits of silver wire and dropping them upon a culture medium in a Petri dish, and inoculating the medium with the bacillus coli, the staphylococcus or the gonococcus, and the cultures will not grow quite up to the wire. The silver wire inhibits, to some extent, the growth of the bacteria upon the culture medium.

We are operating in an infected area. Many of these vesicovaginal fistulæ are associated with ulceration of the bladder mucosa, which harbors infection. There is infection always in the vagina, and, if we can employ suture material that is not only aseptic but antiseptic, I think we have an advantage there which we should not ignore.

I wish to speak of another point, namely, one cannot very easily separate the mucous membrane of the vagina from that of the bladder and deal with each separately, but one can demonstrate easily the fascia which lies between the bladder mucosa and that of the vagina, and one should pay strict attention to that and close that important layer of fascia as well as close the layers of mucous membrane of the bladder and the vagina.

Dr. A. W. Abbott (Minneapolis, Minn.): I want to thank Dr. Judd for his excellent paper.

There are those rather rare cases of fistula that are accompanied by bladder spasm. One case will illustrate: A woman had been already operated on by me unsuccessfully. I tried it again; she left me, and sought relief from others until she had five or six operations. She went to one of our most eminent surgeons in the Northwest, who declined to operate on her because, as she said, her bladder was "too contracted."

This woman had an exceedingly irritable bladder. She would not retain a catheter, pulling it out as soon as she came out of the anesthestia. When she finally returned to me I told her that if she would practice the retention of the catheter, leaving it in as long as she could bear it, then removing it, repeating the introduction and removal until she could wear a catheter continuously for two weeks, I would operate on her. She did so, and the operation was successful.

Of course, the principles laid down by Dr. Judd of proper approximation of the tissues to each other is absolutely correct. This with avoidance of tension and providing against pressure from within the bladder are the three important requisites to success. The particular technic is not of so much importance.

Dr. Thomas S. Cullen (Baltimore, Md.): I think Dr. Judd struck the keynote when he advised the free mobilization of the bladder preparatory to the closing of a vesicovaginal fistula. This is partly accomplished by separating the vaginal mucosa from the bladder wall over a considerable area and in cases where a hysterectomy has previously been done by opening up the peritoneal cavity from below. The latter procedure greatly increases the bladder mobility.

Vesicovaginal fistulæ do occasionally occur after complete hysterectomy for carcinoma of the cervix. This is undoubtedly in part due to the necessarily extensive dissection and to the partial cutting off of the bladder blood-supply. We have, fortunately, been able to reduce vesicovaginal fistulæ following the cancer operation to the minimum by adopting a very simple procedure. The bladder peritoneum is snugly sutured to the cut edge of the anterior vaginal wall. Accordingly when the bladder distends it is the peritoneally covered portion that unfolds and there is little or no pressure on the base of the bladder where the fistulæ are so prone to develop. Before this procedure was adopted the pelvic drain that was carried through into the vagina, lay in contact with the under and raw surface of the bladder, and with the gradual distension of the bladder the already thinned-out base of the bladder frequently gave way over a small area.

Fortunately, we now see very few large vesical fistulæ. Where the fistula has resulted from child-birth and where the greater part of the base of the bladder has sloughed out, great care must of course be exercised to avoid tying one or both ureters. I remember on one occasion, when in Europe, seeing a patient that had been operated on for fistula a dozen times. This fistula developed after a hysterectomy for myoma. The operator was very partial to vaginal hysterectomy in such cases; and to his dismay he found that the myoma was calcified, and he literally had to saw it in two before it was possible to remove it from the vagina. All subsequent attempts to close the resultant vesicovaginal fistulæ were to no avail. Two days after the final operation

I saw the autopsy, and the operator had securely tied both ureters. I must say that the operation was a most difficult and unsatisfactory one from the start to finish.

Where the floor of the bladder is gone it seems advisable to dissect back the vaginal mucosa as far as possible, thus increasing the bladder mobility. The fistula should then be gotten at from above, extraperitoneally, if possible. Sometimes one ureteral opening will be found opening in the side of the fistula, and at first sight it would seem impossible to close the fistula without first transplanting the ureter. This is, however, unnecessary. When we remember that the ureter runs obliquely outward in the bladder wall more than half an inch, it is only necessary to slit the ureter for half an inch and the opening is then well removed from the necessary suture line and the fistulous opening can be readily closed.

In elderly patients where a hysterectomy for carcinoma of the cervix has been done and where a small vesicovaginal fistula has developed, this fistula is often at the top of the vagina and most inaccessible, particularly if the vagina is very small.

George Ward's operation answers admirably in such cases. A deep incision is made through the right or left vaginal wall or on both sides if necessary, and the deep vagina becomes very shallow then. A median incision then starts just posterior to the external urethral orifice and is continued back to or beyond the fistula, and a transverse incision at the end of this opens up Douglas' cul-de-sac. With a male sound in the bladder the small fistula can now be engaged on the end of the sound and brought almost to the outside. It is then closed, and the bladder flaps brought together again. This operation affords great comfort to the operator. It spells success where with any other methods failure would in the majority of the cases follow.

Dr. E. P. Quain (Bismarck, N. D.): I have been very much interested in Dr. Judd's paper. Recently I saw a patient, a girl aged 14, with a vesicovaginal fistula where the etiology was a trauma. She had fallen from a hayrack when the team suddenly ran away, and had been dragged a short distance by holding on to some part of the hayrack. She had no special pain immediately after the accident, but felt very dizzy for a few hours. Frequency of urination was noticed from the time of the accident, and after three or four days she found that she had a constant

dribbling of the urine. She was treated for incontinence and cystitis by various medical men without improvement, during the three years following. However, a cystoscopic examination revealed a very small vesicovaginal fistula, which had been overlooked, chiefly because the hymen had precluded proper examination of the vagina. The bladder was overfilled at the time of the accident, and the sudden jar of the fall undoubtedly caused a tear in the vesical wall, which later, through infection and burrowing, reached the vagina. The fistula was very small, and was readily cured by operation.

At the time when Dr. Mayo's article on the technic of closing vesicovaginal fistulæ first appeared, I had occasion to follow his suggestion in a few cases, and with great satisfaction. Then I encountered a patient who had already been operated on four times for this condition and in whom the diameter of the fistula was over one-half inch. After preparation of the vesical mucous membrane cuff in this case it was evident that one through-and-through suture, to pull out toward the urethra, would leave a large raw stump, gaping within the bladder on each side of the suture. I therefore passed the suture through the mucous membrane margin several times and in such a way that the entire raw surface of the cuff, inverted into the bladder, came in close contact. This was made possible by threading the sutures through a catheter, which was put in through the urethra and pushed tightly up against the sutured mucous membrane stump. The catheter served a twofold purpose, first, to cause pressure against the suture line in the bladder, and, secondly, to keep the bladder empty and collapsed.

I have used this method in several other cases and found it to be a very satisfactory addition to this technic.

Dr. Judd (closing): I think Dr. Eastman brought out two or three very good points in the discussion. In the paper I described the technic and emphasized the importance of being very careful about it, especially about the catheter. Unless the catheter is watched carefully it is apt to be compressed, the bladder to become distended, and the whole operation defeated before one knows it. We make it a business of having one nurse or a house officer keep track of these catheters and see that they are draining. Somebody sees them every hour, so that the catheter can be changed if need be.

We have not used silver wire in the closure of these fistulæ. We are getting away from the use of catgut altogether, and in the last year we have used silk and linen and silkworm gut; and I see no reason why we should not continue this practice. We have had some difficulty when we have used catgut alone, just as Dr. Eastman has had.

Repeated operations are justified if the sphincter muscle is intact.

Regarding the case related by Dr. Cullen, where the vagina had closed down: We have also used a large perineal incision, which Dr. Ward, of New York City, described, and we have used two lateral incisions. I am not sure in that particular type of case, where there is much scar tissue in the vagina and where the opening in the bladder is attached up under the pubic bone, whether it is not more satisfactory to do a suprapubic operation.

MEDICAL EDUCATION IN GREECE*

Carl E. Black, A.M., M.D., F.A.C.S.

JACKSONVILLE, ILLINOIS

After a year spent in Greece in close contact with the best and most influential elements of Greek society it is plain that Americans have many erroneous ideas of modern Greece. Education is universal in Greece, and their system of compulsory primary education is the oldest in the world, while their system of secondary schools, for both men and women, will compare favorably with that of other countries. Their language has prevented a better understanding of other nations and is one of the things which has prevented our exact knowledge of them. This will be improved in the near future by a wide adoption of the study of English, which is now in process of development. Time and attention formerly bestowed upon German is now rapidly being transferred to English.

The Greeks have good minds and, on the average, make intelligent doctors. They are good students, although a little too much inclined to the abstract in study, as shown by their "invincible and irresistible love of the spiritual and intellectual," but this is being rapidly overcome by the laboratories and clinical facilities of various kinds required by modern methods in the teaching and practice of medicine.

Many of the deficiencies of their system of medical education and of their teaching and organization in

*This address was illustrated by one hundred and twenty-five stereopticon slides, and was given at the banquet of the Association.

general, are due to their intense independence and individuality of character, but much of their success is due to their devotion to their country and to their traditions of Hellenism.

The American physician is hardly prepared for the extent to which they have developed their facilities for medical education. The University of Athens is a real University, and the Medical School is built on modern principles of medical education. The resulting profession speaks well for the progress which Greece has made. This is doubly surprising when one remembers how recently they threw off the Turkish yoke and gained their independence.

In studying modern Greece one must keep constantly in mind the fact that they are hampered and retarded by an amount of tradition which exists in few other countries. They have a double problem which we in the west escape, namely, they must resist traditions and habits of long standing while they build up the new and better methods. They have the further disadvantage of being away from the influence of Western thought and ideals. In spite of these conditions Greece has made remarkable strides in developing the Medical Department in her University, which stands alone in the East and Near East as the place where modern medicine is taught.

In Greece the medical profession is divided into three distinct groups. The first and largest group consists of those physicians who received their medical education wholly in Greece. Many excellent practitioners and some high-grade men are found in this class, but, as might be expected, the majority are mediocre. This is true in every country. The second class, made up principally of the internists and pathologists, are those who, after graduating from their

own University, did one or more years of postgraduate work in France. There are a few surgeons in this group. France has had more influence on Greek medicine than any other country. The third group consists of those who did their postgraduate work in Germany or Austria, and for the most part these are surgeons. It was interesting to learn that few who specialized in pathology had studied in Germany.

As far as the East and the Near East are concerned, British and American medicine might never have existed. On rather close interrogation of a number of well-informed Greek physicians, the Mayos, the Cabots, and J. B. Murphy of America are the only ones they could name as being representative, and they knew little of the accomplishments of these. It was a surprise to find that they knew comparatively little of British medicine and British representative men.

Several visits to the National Library to study the relation of America and Great Britain to Greek education and literature showed only a few English authors and almost none from America. The same conditions were found in the section devoted to the Medical Library. There is a large Medical Library connected with the National Library, which adjoins the University, but there is practically nothing of value there which represents British or American medicine. We pride ourselves upon the progress we have made. We believe that we have done some unusually important and creditable things in medicine, both in the United States and Great Britain, and yet there is little in this part of the world to represent that accomplishment or its influence.

The University is under the control of the State and has the Departments of theology, the arts and sciences, medicine, engineering, dentistry, and a num-

ber of others. There have been medical schools in Greece since ancient times, but the present school as a department of the University is of comparatively recent development. Considerable time was spent in visiting the Medical School, and a number of pictures of its buildings were secured. There are twelve main buildings, which house the principal part of the Medical School and a number of smaller and less important ones.

It should be borne in mind that, at the time of my visits to the various lectures, clinics, and laboratories of the school, they were seen at a great disadvantage. During two years of the war the school had been closed. Some of its best teachers had been dismissed on account of their pro-royalist sympathies, and it was in the process of re-organization.

The University building proper is mainly devoted to the offices of the various schools, but also has a number of lecture rooms, some of which are used by the medical school for general lectures. A catalogue gives the various courses in sufficient detail. Women are admitted on the same terms as men, and a considerable number are in attendance. The medical course covers five years of two terms each.

The University building is situated in the center of Athens on a broad avenue called University Street, and only a block away is the main laboratory building occupying a whole block and providing for the departments of physiology, anatomy, pathological anatomy, pharmacology, neurology, special pathology, etc. In the dissecting-rooms of the anatomical laboratory the first- and second-year students are earnestly and industriously at work at practical dissection under the direction of the head of the department and several assistants. Bacteriology and general pathology are taken care of in still another building; and just out-

side the city on the Sacred Way are laboratories where vaccines and serums are manufactured. These laboratories are also used to a limited extent for teaching purposes. As far as buildings and equipment (making due allowances for the shortage of supplies because of the war) are concerned, the laboratory department of the University is well taken care of and would compare favorably with some of the A-grade schools of America.

Nothwithstanding the Greeks' traditional love of argument and of abstract study there has been due appreciation of the developments in medicine along more practical lines; and a considerable proportion of teaching is clinical and a number of hospitals and clinical buildings are provided. Near the University is "Hope" Hospital of the City Hospital. This hospital was erected and is supported by the city, but the patients are under the care of the staff of the Medical School and are used for teaching purposes. Very good clinical facilities are provided in this hospital. General medical and general surgical clinics are held here. I had the privilege of attending some of these clinics and found them practical in character. Students are taken to the bedside by the professor and taught to examine the patients and make a diagnosis. There are also lecture rooms, with blackboards and charts, stereopticon, and other facilities for teaching, where lectures, both didactic and clinical, are given to the whole class and demonstrations held, but bedside ward teaching is a usual method. As an illustration of the method of instruction, on one clinical day when I attended, the subject was "pleurisy," and all the patients in the ward where the clinic was held had pleurisy or empyemas in various stages, so that almost all stages could be illustrated and examined by the students who were assigned by group to several patients.

The Aeretion Hospital, which is some blocks from the center of the city, provides for the clinical teaching of general surgery and gynecology. A number of clinics at this hospital were visited. The general operating clinics are held in two amphitheatres, and there are bedside clinics in the wards. The students are required to examine patients and to make dressings and minor operations. In adjoining grounds is the Aiginition Hospital, which is devoted to neurology and mental diseases. These two hospitals are comparatively new and beautifully located with considerable ground surrounding them. They are not far from the business section of Athens and are easily reached by street-car.

There is a special building for the treatment of diseases of children. A much larger, more complete and better appointed children's hospital, consisting of four or five buildings, one of which contained an operating theatre, was in the course of construction at the outbreak of the war, and will be completed no doubt as soon as building conditions will permit.

Ophthalmology, otology, and laryngology have a good building, well appointed and devoted to their special needs. These special hospital buildings are commodious, and the method of instruction seems practical and efficient.

The polyclinic is located in the old section of the city and is accessible to the poorer population. Here there are several of the departments of medicine and surgery which furnish facilities for practical instruction. While it is principally for out-patients, there are thirty or forty beds for selected cases. The Dental School is in this building. This is a new department of the University, which has only been in operation for three years and can hardly be said to be organized as yet, but there are prospects that in the near future

the Dental Department will take its proper place among the schools of the University.

Anyone studying the clinical and teaching facilities of the Medical School will be especially interested in the Syngros Hospital for venereal and skin diseases. This hospital was built, equipped, and endowed by a wealthy Greek, Andrew Syngros, and is in every way a model institution of its kind. In fact it would be difficult to find a more perfect institution for the treatment and the teaching of these diseases. The active interest and enthusiasm of the directing physician, Dr. Photinos, keeps it abreast of the times, and he has developed the latest methods of giving instruction. An interesting feature of the management is that the female patients are practically prisoners in this hospital behind locked doors. The clinic here practically occupies an afternoon. One of the clinics attended by me was devoted to chancroid. First, the students were in the laboratory where a number of microscopes were ready with sections, in order that the microscopical pathology could be studied. Beside each microscope was a description of the tissue exhibited and also an open book describing some features of the disease as relating to the specimen. Frequently there were pictures illustrating further this special point. In this way a variety of sections and a variety of descriptions were exhibited which each student examined under direction of an assistant. In connection with this hospital there is a splendid collection of wax models in colors illustrating all the principal venereal and skin lesions, and these are used in teaching. On the other side of the same room was a line of male patients, each exhibiting his lesion, which had been previously cleansed, and an opportunity was given each student to examine these. In another room were ten or more female patients on high examining-tables so that the students could easily and quickly examine

the lesions. The faces of these patients were covered so that there was no possibility of recognition. The students then went to the amphitheater, where two hours were devoted to the clinical teaching by the professor or one of his assistants, but even here the students were brought down a few at a time and given patients to examine, and were required to explain to the professor and to the class their findings.

A few blocks away on the lower slope of Mount Lycabetos is the Evangelissmos Hospital. This is a semiprivate hospital, but it is also used for teaching purposes. A number of clinical lectures are given here by the staff although the University has no voice in the management of the hospital. It is a beautiful and well-appointed hospital, and its operating-rooms are ideal. There are a number of large wards where the patients are used for teaching purposes.

On the Sacred Way near Daphne is a hospital for infectious diseases, and classes of students are taken here for instruction. The location of this hospital is excellent, but the appointments are not so complete or satisfactory as in some of the other institutions.

A fair criticism of the Medical School would be that, on account of their traditions, their long existence under Turkish rule, and their far removal from the influence of Western civilization, their teaching is too largely theoretical and argumentative. While far-seeing individuals of influence and ability, like Andrew Syngros, for example, have provided the Medical School with laboratories and hospitals for a most complete and practical medical school, the average professor could improve his course by the introduction of more practical methods. However, the large group of buildings devoted to the interests of medical education attest the fact that a very practical and strong effort has been made and is still in progress in Greece

to overcome this tendency and to make the Medical School a practical working school for the education of doctors thoroughly qualified to care for the sick. While the department has defects and deficiencies, certainly this well-organized faculty, well-developed program, and group of buildings and hospitals devoted to medical education would be a credit to any city or country. After visiting a large number of their clinics and of their laboratory demonstrations and watching their practical work, the American observer is easily convinced that the great need is an infusion of British and American methods and ideals. In many ways the Greek method of thought is more American than it is French or German, and, if America were in the same proximity to Greece, no doubt, her influence would be much greater than that of either of these two countries. They admire America and aspire to do things as we do them, and, if we are in earnest in our interest in the Near East, there is nothing which could be of greater value than for the medical profession of America and of Great Britain to take an active interest in seeing that Greece comes into a good working knowledge of our methods and ideals. They have the plant, they have the spirit, and with a little of our practical interest the Medical Department of the University of Athens could be developed into one of the most practical in the world. In helping to develop this Medical School we would not be simply helping Athens or even Greece alone, but we would be helping to provide the East and the Near East with better doctors, which would be a far more practical project than sending a few American missionaries—with due respect for the great and lasting good accomplished by our missionaries—to this part of the world. Keep in mind that the University of Athens provides medical education for a large number of countries—for a much wider territory than any of our medical schools.

CASE-REPORTS OF MERYCISM ASSOCIATED WITH APPENDICITIS

FRANK G. NIFONG, M. D.

COLUMBIA, MISSOURI

Case 1.—On March 14, 1913, Miss K. P. enters the hospital. She is 26 years old, unmarried, and a very attractive and intelligent young woman, who is doing some university work, but more society.

The family history is negative in its bearing on the present trouble. In her previous history there has been no illness of any consequence. Three years ago she had an attack of abdominal pain, which was diagnosed appendicitis. Since that time she has had no marked attack, but is often conscious of pain and soreness in the cecal region. Long before the initial attack of appendicitis she has had a trouble with her stomach, in that shortly after eating and up to an hour afterwards she would have regurgitation of food. This would take place without warning and without nausea. The food was not sour or bitter. She would chew some and re-swallow it, at times would spit it out, if convenient. This trouble was often quite annoying when attending society functions. The trouble has become much more annoying during the last few months, as practically every meal is followed by regurgitation.

The physical examination shows a beautifully complexioned and physically well-developed young woman—a picture of good health. She has a slight excess of adipose tissue. Her heart, lungs, and kidneys are normal. Examination of the abdomen reveals some pain on pressure and muscular rigidity over the cecum. She is somewhat constipated. She has an occasional slight rise of temperature.

Operation: The incision for entrance is around the right rectus muscle. The gall-bladder, stomach, and pelvic organs, also the small intestines, found normal. The appendix was tucked well up and imbedded under the cecum and had a complete meso-appendix, which was very much thickened. The base of the appendix was bound in closely with fibrous-like tissue and seemed to invert somewhat into the cecum. The ileum, ascending to the ileocecal opening, was bent

sharply at a right angle. This terminal part of the ileum had a membranous covering, which was similar and continuous with the pericolic membrane covering the cecum and ascending colon as high as the hepatic flexure. The pericolic membrane was removed, greatly freeing the cecum and ileum and making them much more mobile. The appendix between the dense layers of the meso-appendix was amputated and inverted, as usual.

Diagnosis (post-operative): Chronic appendicitis, membranous pericolitis, and a kink of the ileum.

Post-operative report: Her recovery was uneventful. The constipation was relieved. She had no further soreness and pain. Most gratifying was the disappearance of the food-regurgitation. Regurgitation happened only a few times and on rare occasions after operation. She was married about three years ago and is now in perfect health with no tendency to ruminate.

Case 2.—On October 24, 1914, Miss A. L. V. becomes our patient. She is a young woman, aged 20, whose vocation is doing society, and whose avocation is attending the university.

Her family history shows some tuberculosis on her maternal side. She has an uncle who is a merycoid.

In her previous history she has had typhoid fever and scarlet fever in childhood. She suffers much from constipation, and at one time she had "locked bowels." For several years she has had eructations of her food shortly after eating and sometimes for an hour afterwards. The food returns suddenly without warning and without nausea, and it is not unpleasant, being neither sour nor bitter. It is annoying when it occurs in company, for it will sometimes suddenly fill her mouth, and she has to swallow several times to return it to the stomach. When not in company she often spits it out. At times she has had attacks of acute indigestion, with pain and nausea and, perhaps, vomiting of soured food, and this was an entirely different thing from the frequent regurgitations. She not infrequently had abdominal epigastric pain, but she never had to go to bed for it.

The present trouble began October 24 in the early morning with severe epigastric pain. Later the pain became more diffuse and lower in the abdomen. She had a slight rise in temperature. We see her later in the day and find a sub-

normal temperature, muscle rigidity of the abdomen, and marked tenderness over the appendix.

Operation was done on October 25, removing an inflamed appendix from under the cecum covered with membrane. The cecum and ascending colon also were covered with pericolic membrane. The cecum was mobilized by severing the cecoparietal membranous attachment. The membrane was stripped from the ascending colon.

Post-operative: The recovery was uneventful except she suffered much pain. There was no post-operative vomiting or rise in temperature. She was out in the usual time. She has been under observation until the last two years. The constipated habit was very much improved, the bowels being almost normal. Only on a few occasions has she had food eructations, which were shortly after the operation. Later the trouble ceased entirely.

Case 3.—Miss M. L. F. is a young woman school teacher, aged 26, who comes July 12, 1919, for examination.

Her parents are dead, but she has no history of hereditary tendencies.

In her previous history we note that she had pneumonia and a continued fever in her childhood. All her functioning has been normal with no history of any marked digestive trouble.

The present trouble was first noticed about two years ago, when she began to have eructations of food shortly after eating. There was never nausea or pain, and the food was never sour or bitter. It was not particularly unpleasant, but was annoying. It happened more frequently after eating very heartily. She usually spat the food out when unobserved; otherwise she had to chew and swallow again. Since the beginning she has had intervals of only a few days when she did not ruminate. She has never been constipated. This condition has been better and worse during the two years, and more recently it has become much more annoying and a constant happening after every meal. She has been expectorating the food, and has lost sixteen pounds in weight. She has had no other symptoms except a little soreness in the right inguinal region and never any acute pain. All her functions seem normal.

The physical examination of the chest is negative. She is still well nourished. She has been rather fleshy. The abdo-

men is normal except only a slight tenderness over the cecum from pressure.

Operation July 12, 1919, with a right rectus incision. The stomach, gall-bladder, and small intestines are normal. The ovaries enlarged with small cysts. A fibrous nodule was removed from the ovary and one from the fundus uteri for examination. The appendix was completely covered over with a thick fibrous organized material, and had to be dissected out. It was curled on itself, long, and of small diameter. The cecum was also covered at the end with this same thick material much heavier than the ordinary pericolic membrane. This material was all removed and the appendix amputated. A pocket or pouch was left from which this thick mass and appendix were removed which was covered over by sliding and suturing the adjacent serous membranes.

This patient did well and left the hospital in ten days. Three weeks later I had to open the rectus sheath and let out some sanguinopurulent exudate. She has returned to her school teaching, and only on one occasion has she had her food regurgitate.

The recital of these three cases of appendicitis will be pardoned, I hope, because they present an accompanying trouble so peculiar and infrequent. Rumination in man has been observed for a long time, notwithstanding it is so unusual. Many interesting conjectures may be made as to its cause. Our atavistic tendencies may occasionally take us back to our prehistoric ancestors, who ate grass and chewed the cud, a long, long time before old Nebuchadnezzar was turned on pasture. Quite a number of cases of merycism are recorded, but we fancy these are the first on record which seem to be affiliated in some way with a damaged appendix or a Jackson's membrane. It may be an injustice to try further to indite the appendix, which has already so many counts against it. Possibly a true bill may be found against Jackson's membrane. We must admit that these cases show a peculiar coincidence. It is at least suggestive that the pathology had something to do with the merycism since all three cases were relieved of the trouble.

Case 3 could not have been diagnosed appendicitis or pericolitis on the symptoms and signs presenting, but she was operated on for the merycism because of the experience with the other two cases.

We should hardly be justified in concluding from so limited an experience that appendectomy is the proper treatment for merycism. We think it is a matter of interest to record these rather strange and unusual conditions, and to note the similarity in these cases, which may be only a coincidence.

These patients were all females, while it is stated that most merycoids have been males. The appendicitis was of the chronic type. There were no very acute attacks, and Case 3 had never had an acute attack. Constipation was not a marked symptom except in Case 2, notwithstanding the pericolic condition, and all of the patients enjoyed very good health. The regurgitation of food was really the most annoying and prominent symptom in all of them. Note also the similarity in the pathology. All of them had a pericolic membrane and a fibrous bound-down appendix.

We are, indeed, "fearfully and wonderfully made," and the most complex and wonderful part of our anatomy is our great sympathetic nervous system. Why pain and reflex disturbances distant from the pathologic point? Well, we will put it on the sympathetic system. It is most convenient. Perhaps our appendix vermiformis was a prehistoric grass-pouch and we were herbivora. We believe it was not a stomach according to our comparative anatomists, for it was too far down the line. But, no doubt, it was, and is now, most sympathetically associated with our stomachs and the front end of our alimentary tract. Just why should we have our initial epigastic pain in acute appendicitis unless our great sympathetic sends the message up to the stomach, and it throws a pyloric

spasm and pushes our stomach against the parietal walls, wherein are our sensory nerves. Right after that the message is sent all down the line and we have a general parietal pushing and general diffuse pain results, finally landing at the pathologic seat of trouble right over the appendix.

It is only through the association of the appendix and the stomach through the sympathetic nervous system that we can conjecture why the removal of the appendix and the freeing of the cecum could cause the disappearance of the merycism.

DISCUSSION

Dr. A. L. Blesh (Oklahoma City, Okla.): I was very much interested in what I heard of this paper, because it bears out some observations of my own, extending over several years, relative to digestive disturbances, due particularly to the appendix, sometimes to the gall-bladder and quite frequently to the female pelvic organs. In fact, I have come to believe that indigestion, so called, may be divided into two classes,—those cases which are intrinsic to the stomach itself, due probably to an ulcer, cancer, and so forth, and sometimes to syphilis, rarely however; and those cases that are extrinsic to the stomach, that is, reflex, which constitute by far the larger class of chronic stomach disturbances.

In this class of cases would fall the cases cited by the author of the paper in which there was the manifestation of rumination. The stomach syndrome, as we have had it from the master surgeon, Moynihan, and others, is of no special significance any longer as regards the stomach itself; that is to say, the dictum that Moynihan gave out several years ago, that hyperacidity means ulcer of the stomach, can be answered only by saying that it is not true, and that periodicity has but little to do with it because this syndrome I have found in several thousand cases of appendectomy, as often and oftener than I have found it with the stomach itself as the seat of disease. Therefore, the laboratory is not a criterion; it is only a guide. The *x*-ray is of far more importance, both in its negative phase and in its positive phase, but one or two *x*-ray pictures tell us nothing. We

must have enough pictures for comparison because one perfect stomach contour of an *x*-ray picture will negative fifty irregular contours or defective fillings.

Dr. R. C. Coffey (Portland, Oregon): It is my opinion that the disease which Dr. Nifong has described is simply a reverse peristalsis, and it may be due to a great many causes. Anything that disturbs the small intestine will produce it. It has been said by some one that the "stomach talks for the small intestine and the first part of the large intestine." No matter where the trouble is, if you have a kink in the bowel that causes partial obstruction there is a tendency to reverse peristalsis. If you have appendicitis there is spasm above the appendix to protect it from the normal action of the bowel; therefore we have a tendency to reverse peristalsis. Undoubtedly, that is the reason for the pain described as occurring all over the abdomen in the region of the small intestine. Spasm of the intestine produces a peristaltic wave away from the diseased area, so that while I think there are cases in which the appendix to which the essayist referred will account for some of these cases of rumination, it is equally true that anything that will seriously disturb the small intestines will probably do exactly the same thing.

Dr. B. B. Davis (Omaha, Neb.): Those who have discussed the paper of Dr. Nifong have done so from a scientific standpoint. I look upon this subject with a sort of alarm because we have had a peculiar feeling in regard to people from Missouri. We have the expression, "I am from Missouri," and that will probably be modified to read, "I chew my cud." (Laughter.) It looks to me that this is Missouri propaganda.

I believe Dr. Jabez N. Jackson is the man who invented the pericolic membrane and utilizes it to advantage, and the fact of the existence of this membrane has given a great many men a whole lot of business. (Laughter.) This does not seem to be a malady that develops outside of the State of Missouri, but the condition is largely confined to this one particular state. Nevertheless, it is an interesting proposition, and perhaps Dr. Coffey's explanation is entirely correct, but at the same time it does throw suspicion on Missourians. (Laughter.)

Dr. Nifong (closing): In the first place, I stated in my paper that I did not know anything about the condition.

I do not plead guilty to the indictment that this is a Missouri propaganda. (Laughter.) We have not had enough cases to make much out of it. Perhaps it might be a good thing if all of us were to chew our cuds, then we would get all of the nutrition out of our food that is possible. One observer has suggested that this was a prehistoric condition. Certain herbivora would eat their grass almost on the run and then make for a place of safety and chew it. We Missourians have to hurry so these days to make a living that maybe it will become universal again to chew the cud. We eat a little and do not have time to digest our food properly. We swallow food whole and hustle on trying to make a living, and if we could get to several places where we could rest a little, chew our cud, and re-swallow it, it would be a good thing.

We do not call the condition I have described indigestion. It occurs when the stomach is pretty full or overfilled. These patients regurgitate their food, chew it, or spit it out, or swallow it again, and they describe it sometimes as a pleasurable sensation. They do not seek relief from it. These people will negative the indictment about this being a Missourian propaganda. These cases were evidently true stomach regurgitations. There is nothing particularly interesting about them except their uniformity in pathology and symptomatology, and in aping animals it is a rather strange coincidence, but they were all distinctly relieved of this trouble by operation.

DIAPHRAGMATIC HERNIA

THEODORE F. RIGGS, M. D.

PIERRE, SOUTH DAKOTA

Protrusion of a portion of the abdominal viscera through an opening in the diaphragm, while by no means unknown, is perhaps more frequent than we realize. According to Giffin,[1] about 650 cases of diaphragmatic hernia had been reported in the literature up to 1912; and eighteen articles on this subject, from the point of view of the radiologist or surgeon, have appeared during the past two years. Since many of the diagnoses have been made only in the autopsy room and, as a number of patients have been operated upon with the hernia unrecognized and unrelieved, it is probable, as Soresi[2] so clearly points out, that many a person is in discomfort to-day because of the failure to recognize the true condition present.

According to the authorities the great majority of diaphragmatic herniæ occur at the left of the midline. The case herein reported we believe to have been a true traumatic hernia on the right of the midline.

The patient, a woman, aged 34, weight, 170 pounds, height, 66 inches, was admitted to St. Mary's Hospital December 1, 1918. Complaint: vomiting ten to sixty minutes after nearly every meal. Family and personal history, unimportant except that the patient has been strong and active, doing hard physical house and farm work. Present trouble began about two and one-half years ago and has been gradually increasing. The patient ascribes the beginning of her trouble to carrying a wash-tub nearly full of water. She carried this about fifty feet with the side of the tub resting against her abdomen. While carrying the tub she noticed a sharp rather sickening pain in the upper abdomen or in the angle of the ribs, which pain almost wholly ceased when she emptied the tub and was relieved of the weight. She, however, did no more work that day because of persisting nausea with a few

unsuccessful attempts at vomiting. The next day she was seemingly as well as ever and for a time continued to do her usual work, but without attempting to repeat the tub-carrying incident. Recurring attacks of mild nausea and eructation at various intervals were noted during the first year, gradually increasing in frequency, and during the past year and a half the nausea and belching have been followed more and more by vomiting, until during the past six months the nausea has almost ceased and the vomiting has been noted to occur within ten to sixty minutes after nearly every meal. The vomitus consists of the food ingested, but rarely, if ever, has the patient vomited all of the food taken. There has been no appreciable loss of weight or strength. There has never been any severe pain since that at the onset. No blood has been in the vomitus nor, so far as known, in the stools. Liquids were perhaps less likely to be vomited than more solid food. The bowels have always been somewhat sluggish, and the patient thinks that during the past year this sluggishness has increased. Menstrual history is negative; the possibility of a pregnancy or of a pelvic tumor or inflammation was carefully considered and eliminated.

Examination showed a rather pale, well-developed, well-muscled, rather fleshy young woman. Temperature repeatedly normal. Hemoglobin, 70 per cent.; leucocytes, 7,600; blood-pressure—systolic, 134; diastolic, 80-85; urine, normal—the test meal an hour after eating showed a free hydrochloric acid of 26 and a total acidity of 49. A second specimen taken thirty minutes later gave hydrochloric acid 23 and a total of 31. Digestion was poor, and there was considerable mucus. In the chest the lungs were clear, and there was no restriction in respiratory movement. The heart-sounds were normal, but the area of cardiac dullness and the apex beat were noted to be about one-finger breadth higher than normal. Although the chest was separately examined by two of us there was no area of tympany found. The abdomen was fleshy, full, and soft, with no tender area except on deep pressure beneath the costal border in the gall-bladder region. The stomach outline was high, but not unusually so, and there was no unusual dilatation or discomfort on filling the stomach with air. The capacity of the stomach was about 750 c.c., as noted on lavage.

Following a barium meal the *x*-ray showed a high stomach, but, very unfortunately, the margin of the first plate came too low to include the pylorus. The second picture taken an

hour later shows the barium passing upward and to the patient's right through a constricted area proximal to the pylorus. The patient vomited approximately half of the meal, and the succeeding bowel-pictures were not satisfactory. That

Before operation.

After operation.

we did not fully appreciate the second picture is shown by the fact that our choice in the a. o. diagnosis was a secondary gastric upset due to adhesions resulting from an old ulcer.

Looking backward it is easily seen that we should have made a correct diagnosis.

Operation was done on December 11, 1918, under ether anesthesia. Incision over upper right rectus. Gall-bladder and appendix, normal. The peculiar fact was noted that no omentum and no transverse colon could be seen on first examination. A portion of the greater curvature of the stomach was visible, but its margin was almost parallel to the incision. On following the colon from near the hepatic flexure what should have been the transverse colon was found to pass upward and to the left of the gall-bladder where it was parallel to, and slightly behind, the greater curvature of the stomach. The right and left lobes of the liver were widely separated along their lower margin just at the left of the point of juncture of the falciform ligament. The transverse colon and the stomach were found to pass upward in this separation of the liver and to pass through an opening in the dome of the diaphragm slightly to the right of the midline. Considerable difficulty was met in withdrawing these organs from the opening in the diaphragm, but when accomplished it was found that the contents of the hernia consisted of the pyloric portion of the stomach, the greater portion of the transverse colon, and almost the entire omentum.

Following the removal of these organs from the diaphragmatic opening, the patient at once ceased to breathe, but respirations were resumed when pressure was made closing the abdominal incision. The incision was then extended upward along the costal border to the midline, and the hand was easily passed through the opening in the diaphragm. As nearly as could be told the cavity occupied the posterior part of the mesial portion of the right half of the chest. The heart could be felt pulsating at the patient's left, and the lung tissue resistance could be felt anteriorly to the outer side and above the hand. Posteriorly the ribs and bodies of the vertebræ could be easily felt through a thin layer of soft spongy tissues. There was a definite sac, but whether composed of two layers, the peritoneum and pleura, it is impossible to state. The opening in the diaphragm had its long axis anteroposteriorly, and there was a distinct continuation of the diaphragm for at least two inches anteriorly and one and one-half inches posteriorly beyond the ends of the hernial opening, which easily admitted the examining hand and was fully three inches long.

To close the hiatus four double sutures of No. 3 plain catgut were passed through the two pillars or margins of the opening, leaving the ends long, until all sutures had been placed, when they were tied. To insure a more permanent closure a portion of the omentum was lifted up and sutured over the opening. To pass the sutures in the diaphragm it was necessary to elevate the costal border, whereupon respiration would cease. It was, therefore, necessary to pass one stitch and close the abdominal incision by pressure until respiration was reëstablished before attempting a subsequent suture. In the passage of one of the sutures the needle evidently punctured the pericardium or possibly touched the heart, as there resulted a sudden violent tachycardia. Needless to say, that needle was promptly withdrawn. Final closure of the diaphragmatic opening was apparently sound, for the abdominal incision could be held open without affecting the respirations. One small roll rubber drain was placed in the upper end of the incision with its tip carried down nearly to the line of suture in the diaphragm, and the abdominal incision was then closed.

Convalescence was uneventful except that during the second week the temperature ranged between 99° and 101°, probably due to a collection of fluid in the hernia cavity as was evidenced by relative dullness in this region. Whatever the cause, it gradually quieted down, and the dullness disappeared. The displacement of the heart upward, as noted before operation was entirely corrected and was doubtless due to the pressure of the displaced abdominal viscera. The patient was discharged from the hospital on January 5, 1919, but was again seen on February 26, when a barium picture showed the stomach in normal position. There has been complete relief from the symptoms.

That the hernia was of traumatic origin we believe the history shows. That the opening was to the right of the midline we are certain. That the condition was not an elevation or relaxation of the diaphragm is proved by the definite limits of the opening. That the rupture was not through one of the normal openings in the diaphragm was shown by its position and the fact that no tissues passed through the ring other than those named.

Of the presence of a hernial sac or membrane we are sure, although we cannot be certain it was not a

false sac developed by the long standing hernia. However, because the hernia evidently did not reach its maximum size at onset, because there were no adhesions of the viscera in the sac, and because the pillars of the split in the diaphragm were so evidently covered with peritoneum, we feel justified in believing the hernia to have been a true one, namely, contained in a sac formed by the diaphragmatic peritoneum and the diaphragmatic pleura.

If it be true, as seems likely, that the profession is not making as high a percentage of correct diagnoses in diaphragmatic hernia as in other more frequent abdominal conditions, the failure is probably due to lack of a sufficiently definite symptomatology. DeCourcy[3] has formulated a few symptoms which point to non-traumatic cases of diaphragmatic hernia. Soresi[2] discusses fully the difficulties of outlining the symptoms characteristic of small diaphragmatic hernias which he says are never diagnosed, and he urges careful routine examination of the diaphragm. A comparison of the cases reported by Beckman,[4] Giffin,[1] DeCourcy,[3] and others brings out clearly the variations in, and the multiplicity of, the symptoms.

This is to be expected when one considers the many combinations possible, depending upon the location of the hilus and the viscera involved. It is reasonable to expect the traumatic hernia to be more easily diagnosed than the non-traumatic form, but one must remember that the severity of the symptoms is not necessarily in keeping with the size of the hernia. The possibility of a diaphragmatic hernia should, perhaps, be more often considered.

1. Giffin, H. Z.: Annals of Surgery, 1912, vol. lv, p. 389, and personal communication.

2. Soresi, Angelo L.: Annals of Surgery, 1919, vol. lxix, p. 254.

3. DeCourcy, Joseph L.: Annals of Surgery. 1919, vol. lxx, p. 179.

4. Beckman, E. H.: Surg., Gynec. & Obst., 1909, vol. ix, p. 154.

Dr. A. L. Blesh (Oklahoma City, Okla.): I have one case of diaphragmatic hernia I wish to put on record; however, I was not so fortunate as the author of this paper in making my diagnosis even when the belly was opened. It occurred while I was Chief of the Surgical Service at Fort Sam Houston, and it might be of interest to say a few words about the relative frequency of this hernia as compared with other herniæ. In that service we operated upon about one thousand cases of different kinds of hernia, and there was but one case of diaphragmatic hernia. This patient was brought to the hospital giving a clinical symptomatology of acute obstruction of the bowel. Of course, in that condition we could not subject him to the time necessary to make *x*-ray studies. An immediate operation was imperative.

We know that most of the intestinal obstructions occur in the right half of the abdomen and that most diaphragmatic herniæ occur in the left dome of the diaphragm. Our incision was made over the right rectus and in the region of the appendix. The patient was practically in extremis. We had no time in which to search for the obstructing factor, so we did an enterostomy for immediate relief. The patient, however, died within twenty-four hours after operation, and the diaphragmatic hernia was discovered post mortem. This also was a traumatic hernia dating back some eight or ten years prior to the time of the patient's coming to operation, and we could trace to the exact trauma, from which time the symptomatology was very similar to that described by the author of the paper. I believe now that with my present view of it, having seen this case, I could make a diagnosis of diaphragmatic hernia, provided we got the patient before obstruction occurred and with the help of the *x*-ray.

In making a diagnosis of diaphragmatic hernia our hindsight is much better than our foresight; it is like the abdominal syndrome in pneumonia. During the epidemic in the army we had a great many of these cases, and we operated upon a few of them before we found out we were dealing with pneumonia, and directly our hindsight proved exceedingly good. We were able to make a diagnosis of these conditions on three symptoms, and I believe it will be the same with diaphragmatic hernia when we once begin looking for such cases. They are relatively rare. The author of the paper states that some 600 cases have been found in the literature,

and among the hundreds of thousands, perhaps millions, of abdominal operations that are done, only that many cases of diaphragmatic heria reported speaks for the relative rarity of this condition.

Dr. H. M. Richter (Chicago, Ill.): I should like to call attention to two points in the technic of handling diaphragmatic hernia, my observation being based upon several experiences I have had with suturing of the diaphragm. In one case I had occasion to return the liver through a right diaphragmatic rupture, and in another I had occasion to return the stomach, colon, and several feet of small bowel through the left diaphragm. I found it exceedingly difficult to pull the abdominal contents back through the diaphragmatic opening, a fact long known. If one pulls the viscera down they slide up again. It is a very different matter to drop the abdominal contents back by making an intercostal incision; they slide back into the abdomen as readily as through an abdominal incision. The diaphragm is very high. It cannot be reached readily, as the reporter stated, through the abdomen. It comes directly within reach through an intercostal incision through the fifth intercostal space. A free, long intercostal incision through the fifth intercostal space satisfactorily exposes any part of the diaphragm.

The second point I wish to speak of is with reference to the suture material. The finest suture material one can use is many times stronger than any pull that the tissues can put upon it is able to break. For instance, the finest catgut will sustain the tension in diaphragmatic hernia, or in any hernia in the inguinal region. If you place five or six or more sutures to the inch, it takes a tremendous pull to break them. The sutures are found to have a combined strength more than equal to that of the tissues.

In some experimental work that I reported years ago, I found that in suturing the bowel with human hair, these sutures sustained a hydrostatic tension of eight pounds to the square inch. In using size 2 catgut, the suture broke through at four pounds to the square inch. The finest material one can use with the finest needle will pass between the fibres of the material you are suturing, while a heavy suture will saw through the fibers and cause rupture.

Dr. William Jepson (Sioux City, Iowa): The remarks that have just been made by Dr. Richter to the effect that opening the pleural cavity through the intercostal space in

cases of diaphragmatic hernia, leads me to report a case wherein I did that when it would have been absolutely impossible to have reduced the diaphragmatic hernia. I am going to relate a case to you and leave the matter for you to determine for yourselves whether under similar conditions you would not or would have been able to reduce it. I must say the gentleman's remarks and directions are most excellent under ordinary conditions. In the first place, I am quite surprised, not having myself looked up the literature. I have myself seen in practice, and have operated upon three cases of diaphragmatic hernia, all of which were traumatic. They gave a traumatic history, one of them definitely so because of the fact the patient was operated on within twenty-four hours afterwards, and a rupture of the diaphragm on the left side was found. By the way, we should keep in mind diaphragmatic hernia, provided we may use the term *hernia* to apply to those cases where the diaphragm has ruptured, and a viscus has found its way out into an abnormal situation. That is a hernia. We should divide cases of hernia into the congenital and acquired. By the term *congenital* we mean cases in which there is an absence of muscular fibers, which we know is liable to occur at certain definite areas, as, for instance, where the lumbar part of the diaphragmatic muscle sticks up from the lumbar vertebræ, and two ligaments unite with the costal portion. It shows where the costal portion unites with the sternal portion, particularly at the ribs on both sides. Then, again, we have a disability in the muscle line with fasciculi coming from the two arcuate ligaments, leaving an opening and a congenital absence of muscle, with the result that we have a pleura on one side and the diaphragm on the other. In consequence, we have inadequate resistance, with the result that a hernia forms on account of the probability of continued negative intrathoracic pressure.

I wish to mention a case I had in mind which shows the difficulty in making a diagnosis, although I saw the patient only on the post-mortem table. It happened to be in my service at Camp Bowie, and the case was so unusual I was called out of bed at night in order to see the condition which was found. The man was 22 years of age, and had been admitted to the service persumably in a normal condition. He carried on his duties as a private in the infantry. He had had a severe attack of influenza, followed by pneumonia, and then it was discovered he had a peculiar condition in his left thoracic cavity. I do not know what diagnosis

was made. One man in my service was serving on the medical side for the time being, and the patient was under his care. He was a competent man. He aspirated the patient's chest and got some slightly yellowish fluid which he sent to the laboratory, but in the meantime the patient died, and this is the condition that was found: He had a left diaphragmatic hernia, which I presume was congenital, and had started to develop in early life, with the result that all of his intra-abdominal viscera were practically sucked up into his left pleural cavity; in other words, the small intestine, the jejunum, beginning at the duodeno-jejunal junction were pulled up under here (indicating), and the small intestine was in his left pleural cavity. The ascending and transverse colon were pulled up so that about this much (indicating) of the former was out of the opening in the pleural cavity. His transverse colon was also pulled up. The spleen was still in the abdominal cavity, and so was the pancreas, but the tail of the pancreas was bowed so that it was trying to get inside the pleural cavity. The only other thing the man had in his abdominal cavity was an immense stomach which seemed to fill everything,—his bladder, descending colon, and sigmoid flexure. Up in the upper part of his pleural cavity he had a small mass of lung about the size of that (indicating), which was consolidated. If any of you think you could have reduced that hernia by operation or otherwise, think it over, and when you come in contact with such a case in the future see what you can do with it.

Dr. R. C. Coffey (Portland, Oregon): In connection with the very interesting paper of Dr. Riggs I want to report one case.

A woman was shot in the left side of the chest, being severely wounded. A few days thereafter she developed empyema. A rib was resected and a gastric fistula developed, which went on for a few weeks or months, and then gradually closed. An *x*-ray examination showed that most of her stomach was above the diaphragm. The diaphragm had been cut with the bullet and the stomach was allowed to come up into the pleural cavity, and apparently had been bruised or wounded in such a way that the gastric fistula led into the chest, which finally healed of itself. The stomach is still up—at least two-thirds of it—in the chest. The opening is very large, and nothing was done for it, and she is in comparatively good health.

Dr. C. D. Lockwood (Pasadena, Calif.): I was taught a good point in reference to diaphragmatic hernia by a patient whom I saw in California. On Friday the man was perfectly well; on Saturday he began to develop an acute attack of appendicitis while en route to California and was very sick when he reached Pasadena. He had vomited a good deal. We operated on him immediately. He was taken from his residence to the hospital, and on opening the abdomen we found a typical acute appendicitis. We removed his appendix, and he was completely relieved of his pain, but he continued to vomit. We then suspected that he had intestinal obstruction due to appendicitis, as we so often get, and we re-opened his abdomen and found no evidence of obstruction. He died on the third day. At the post-mortem we found a recent diaphragmatic hernia, which had found its way into the pleural cavity through an old stab-wound he had received eleven years before, in some encounter, and the explanation to my mind was this: The man in using his diaphragm in vomiting had forced the intestine through the diaphragm, and it was not recognized. We got the specimen post-mortem.

Dr. Riggs (closing): I have geen greatly pleased with the discussion. If my paper has done nothing else it has put on record a number of cases of diaphragmatic hernia. As a medical student I remember one of our quiz men used to ask us about hernia, and he always made mention of diaphragmatic hernia, but then would drop the subject because he said it rarely or never occurred in practice, and was only mentioned in text-books. So I really had that sort of an idea. I was astonished when I looked up the literature to find the number of cases that had been reported. I went at this matter backward. I found a hernia which was undiagnosed before operation, and then I found there were approximately 700 cases of diaphragmatic hernia reported. Considering all the abdominal cases that have been operated on the relative number of cases of diaphragmatic hernia is not very great. When we remember that at the Mayo Clinic they have only had three or four cases of diaphragmatic hernia, I considered myself very lucky to find one and to be able to get away with it. So I read this paper with the idea of getting some other experience, and certainly I have been successful.

I want to thank Dr. Richter for his criticism of the suture material. He is perfectly correct. No. 1 catgut would have done just as well, or any very fine suture material.

The point made by him as to the intercostal incision relieving suction is well taken. There is no question but what it is of value. In this case with the patient having his hernia in a definite sac, it would have been more difficult. We could have operated through an intercostal incision, but we had made the abdominal incision through an erroneous diagnosis.

JAUNDICE AND ITS SURGICAL SIGNIFICANCE

C. H. Mayo, M. D., F. A. C. S.

ROCHESTER, MINNESOTA

Jaundice as a symptom of disease may present a very serious problem in tracing its cause. In approximately 50 per cent of the cases seen the absorption of bile is due to obstruction of the common duct by gall-stones; in 20 per cent of all cases it is due to absorption of bile in the liver or to infective or catarrhal jaundice without duct obstruction. Most of the latter cases occur in children and young persons, just enough occurring in middle age and later to make a differential diagnosis necessary, as attacks of pain sometimes accompany this infectious disease or the patients actually have gall-bladder disease.

It is not my intention to discuss the diagnosis of the various causes of jaundice, but to consider the treatment of obstructive jaundice in cases in which the patient is on the table, the abdomen is open, and jaundice is either present or the patient is having a free interval between recurring attacks. The surgeon must have in mind the fact that jaundice is an essential feature of several conditions, and that it is an indication of serious disease in the majority of cases. The idea that jaundice may be a symptom in fairly normal persons over long periods evidently came about from the observation of hemolytic acholuric jaundice caused by splenomegaly, a surgically curable disease, sometimes complicated with gall-bladder disease and stones. From 5 to 8 per cent of the cases of jaundice are due to serious infection of the gall-bladder, possibly gangrene, with or without stones; they are usually accompanied by a degree of pancreatitis with

marked swelling of the lymph-glands on the three ducts; all persons have one on each duct, but no one more than two. The liver is congested and dark; the ducts are slightly enlarged and contain much flocculent material, which is also found in the gall-bladder in which stones are usually present.

Jaundice from cancer presents a very serious problem, although it represents but 15 per cent of the cases seen; one-half of these are from cancer of the liver, the other half from cancer of the pancreas or the gall-bladder and ducts. Patients with cancer of the pancreas or in the ampulla of Vater may be relieved, often for many months, by short-circuiting the obstructed area. We have not had a permanent cure from transduodenal extirpation of tumor of the ampulla; and it must be admitted also that it is sometimes difficult positively to determine whether the hardening of the pancreas causing obstructive jaundice is of a malignant or of an inflammatory nature. Jaundice from cirrhosis, with ascites usually present, occurs in about 8 per cent of cases. The old classification made by Courvoisier still remains a true observation, in which in about 84 per cent of the cases of stone in the common duct the gall-bladder was shrunken or atrophied; while in 92 of 100 cases of obstruction due to lesions in the ampulla or pancreas or other conditions, the gall-bladder was dilated or enlarged; in the remaining 8 cases it was either normal or atrophic.

In cases of chronic jaundice with obstruction the distended gall-bladder and ducts are often filled with a clear mucoid fluid, indicating, I believe, that the power of the mucous gland to secrete the less absorbable mucus which fills the ducts is greater than the power of the liver to secrete bile, and forces the liver with its lower blood-pressure to absorb the bile. In cases of late operation at which the so-called white

bile is found, failure of the power of biliary excretion to appear within a day or two following the operative drainage is a most unfavorable symptom. Long-continued jaundice slows the coagulation time of blood; as a rule, if the coagulation time is under ten minutes, it is not of serious moment, but a ten to twenty-five minute period is not uncommon, and in some cases the blood will not coagulate in an hour. Patients in whom the blood leaves the vessels, as shown by numerous subcutaneous hemorrhages, should be medical cases until improvement occurs before surgery is indicated. Calcium has been given, with questionable relief, to reduce the delayed coagulation time of patients with chronic jaundice who are being prepared for operation. The best measure in cases with twelve minutes or more coagulation time is the transfusion of acceptable human blood. Patients whose coagulation time is greatly reduced are given one transfusion, and the blood is tested the next day. If improvement is marked operation is performed, but if improvement is slight transfusion is repeated just preceding the operation, and, if there is hemorrhage during the next few days, transfusion is again repeated with occasional benefit.

If the gall-bladder shows marked evidence of disease, especially in cases of stone in the common duct, a cholecystectomy is performed. After removal of the gall-bladder the cystic duct is split through into the common duct to permit of an exploration; here the pliable metal spoons and bulb-tipped probes and the Gussee fenestrated stone forceps of various sizes are useful. In the rare instances in which the gall-bladder has already been removed a more favorable location than the cystic duct area can be selected. In more severe infection with degrees of gangrene the gall-bladder should be removed unless the serious condition of the patient makes haste imperative; then it is

drained with or without drainage of the common duct, depending on whether or not bile flows from the gall-bladder.

In such cases the gall-bladder is split on each side with scissors from top to bottom, one-quarter of an inch from its attachment to the liver. The free flap is turned downward, exposing the obstructing stone in the cystic duct; the duct is clamped in forceps and divided. The mucous membrane remaining on the liver attachment readily peels off, leaving the outer layer of the gall-bladder for protection since, if this should be peeled off, serious hemorrhage, difficult to control, may result. Suturing such a liver adds to the infective condition, for the liver structure does not permit of drawing sutures sufficiently tight to check serious hemorrhage from its surface; this is one of the reasons why cholecystostomy has been made in some cases. A knowledge of the size of the various ducts is quite essential; in a healthy person the lumen of the cystic duct is about one-eighth of an inch and the lumen of the common duct about one-sixth of an inch. When it is only a little enlarged and with jaundice present infection is the essential factor. A gall-bladder which has been rendered functionless by nature, disease, or operation causes dilatation above the normal of the common and hepatic ducts. A serious and not uncommon cause of jaundice is the too radical extirpation of the gall-bladder and cystic duct and section of the common duct in cases in which jaundice was not a previous symptom, and in which the hepatic duct is mistakenly ligated for the cystic; primary jaundice and later a prolonged biliary fistula result, following which intermittent closure leads to intermittent jaundice. In such cases if the condition is not recognized immediately, and very early union effected by means of a Sullivan T-tube the common duct undergoes atrophy and cannot be utilized again.

The effort to secure delivery of bile from direct incision of the liver or by trocar, tapping a dilated duct, is a last resort from which relief is only temporary, and, if unsuccessful, life is possibly shortened by free hemorrhage.

Jaundice in which the head of the pancreas shows marked hardness, lobulation, and increase in size, requires most careful consideration. If the gall-bladder is distended the condition is due either to pancreatitis or to a malignant change, since the pancreas, as Opie has shown, surrounds the common duct in 32 per cent of persons sufficiently to make obstruction possible by pressure. Obstruction from swelling at the tip of the ampulla may cause a pancreatitis by forcing bile through the major duct of Wirsung back into the pancreas and out of the duct of Santorini. The pancreas, in its development, is evidently prepared for such emergencies since all the ducts of the organ open into the lumen of the larger ducts by passing along its wall for some distance. The closure of the ducts is caused by tension, which is nature's method of protecting all important ducts, such as the salivary and common ducts, and the ureters near their exits, as was shown by Coffey.

A careful examination of the pancreas in all cases of gall-bladder disease or surgical gastric disease indicates that the pancreas is secondarily involved by infection following gall-bladder disease more frequently than has been supposed. When secondary infection of the pancreas is a marked feature of gall-bladder disease, it may be advisable to provide drainage from the common duct, but usually the gall-bladder may be looked on as a primary focus, and should be removed. In most of the simple obstructions due to stones in the common duct, effective drainage is established after removal of the stones by means of the Robson tube passed into the opening of the common duct and up

into the hepatic duct. The tube is held by a fine catgut suture as it emerges through the common duct incision. The suture serves also to close the opening about the drain. In cases of obstruction associated with distention of the gall-bladder, short-circuiting is best done by attaching the gall-bladder, after it has

Fig. 1. (a) Sullivan tube for common duct drain; (b) buried tube (C. H. Mayo) for uniting hepatic duct to stomach or duodenum.

been emptied, to the duodenum. An opening one-half inch in diameter is made in the fundus of the gall-bladder, and the peritoneum is denuded for about one-quarter of an inch from the opening; it is then passed for one-quarter of an inch through an incision at a

conveniently near point, into the lumen of the duodenum. Such openings prove more permanent than the margin-to-margin union of the opening in the gall-bladder to the opening in the duodenum. In some cases with elongated cystic duct the gall-bladder is removed down to its pelvis, and this is passed through an opening in the duodenum which is then sutured around the cystic duct. (Fig. 1.)

Probably the most desperate and difficult cases of jaundice to deal with are those which follow extirpation of the gall-bladder and unintentional division of the common duct. The distended hepatic duct is searched for, usually among the adhesions of from two to four previous operations, or the temporary discharging fistula leading to the hepatic duct is followed. In cases in which the end of the hepatic duct is found opposite the duodenum or opposite the pyloric ring, the pylorus and duodenum are also mobilized and the union is made to the duodenum; this is the preferable method. Often the prepyloric region of the stomach is found adherent beside the opening of the duct. In such cases it is best to disturb the adhesions as little as possible and to anastomose the hepatic duct to the prepyloric portion of the stomach. To maintain this opening until nature contracts the tissues, developing firm union and a mucous-lined tube, it is only necessary to unite the end of the duct to the mucosa of the stomach or bowel. (Fig. 2.)

To facilitate this I have devised a drain which has proved most efficient. It is made by cutting off the bell end of an ordinary male catheter, slipping two small rings cut from the next larger-sized catheter over the smaller part of the tube, and gluing these rings with rubber cement. This little drain, varying in length from one and one-half to two and one-fourth inches, is passed, bell end upward, into the hepatic duct, which has been loosened for a short distance.

The catheter drain is sutured to the end of the hepatic duct and an opening is made into the bowel or stomach through which the lower end of the drain is passed, the lower ring catching in the wall of the bowel or stomach and the second ring just inside the end of the hepatic duct; the outer wall of the stomach or bowel

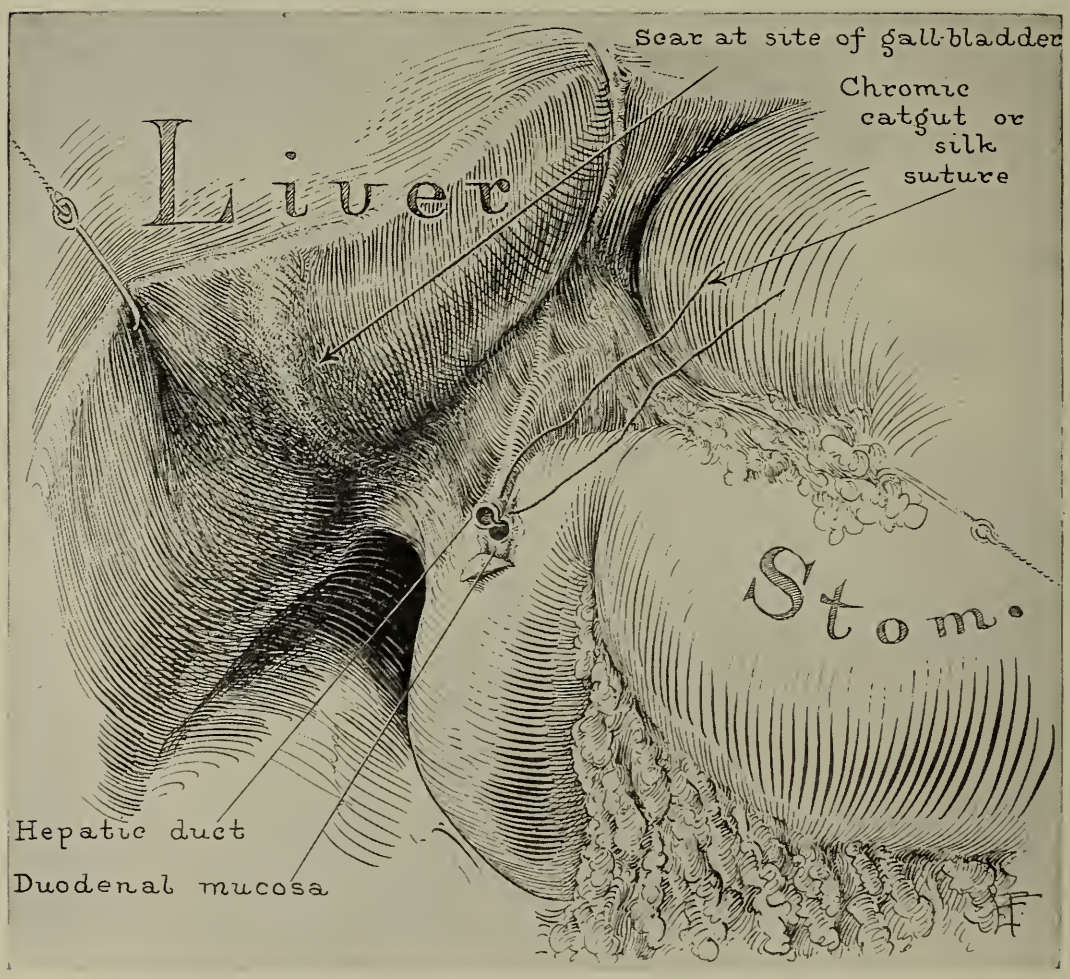

Fig. 2. Preparation for anastomosis of hepatic duct and duodenum.

is sutured around the end of the hepatic duct and protected by gastrohepatic or gastrocolic omentum adjusted around the anastomosis by sutures. The rings on the tube may hold it in place for as long as several months, or until the contraction has relaxed and the mucous membrane of the duct is united to the

lumen of the bowel or stomach. In cases in which this union to the stomach is made all the bile passes into the stomach, but this is of no serious consequence and does not give any distressing symptoms. (Fig. 3.)

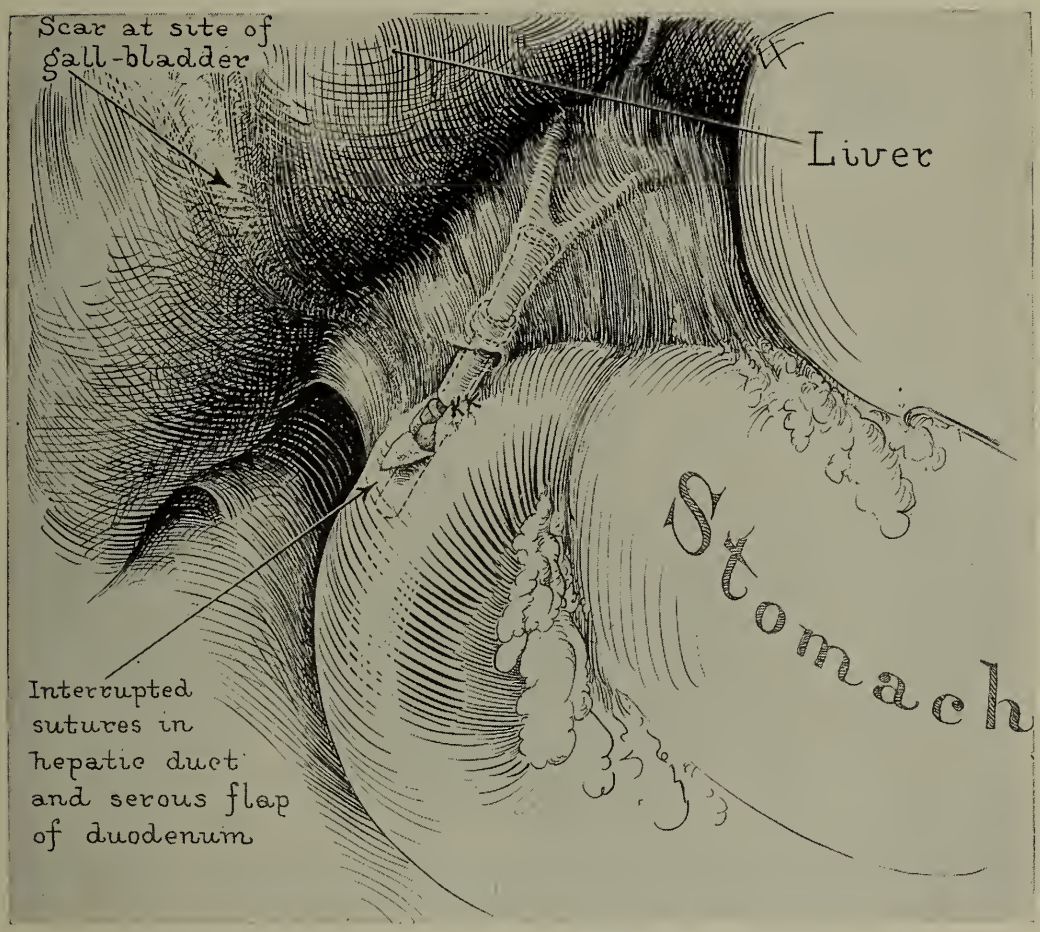

Fig. 3. Suturing partially completed; tube in place.

During the years 1916, 1917, and 1918, in 13 cases seen, it was necessary to unite the hepatic duct either to the duodenum or to the stomach. Two of the patients died. Jaundice is a late symptom of gall-stone in the majority of cases, the result of neglect to recognize the condition or to advise operation in the preventive period. The mortality following cholecystectomy in the treatment of cholecystitis with or with-

out stones is low, only 1.8 per cent in 2,460 operations performed during the period of three years. There were 337 cases in which cholecystectomy and choledochotomy were both done, with a mortality of 3.2 per cent. In a group of 36 cases of very serious obstruction and malignancy, cholecystostomy and choledochotomy were done with a mortality of 16.5 per cent. Choledochotomy alone was done in a somewhat similar group of 47 cases, with a mortality of 15 per cent. If all the choledochotomies are grouped together, however, the mortality in the 420 cases is but 5.7 per cent, too high a mortality for simple cases of stone and obstruction, and too low for the late and complicated cases, including the cancers. Stones were found in the common duct in 274 of the 420 cases.

DISCUSSION

Dr. A. W. Abbott (Minneapolis, Minn.): I should like to ask Dr. Mayo what the end-results are in those cases where he speaks of using these tubes in which a large part, or at least some, of the tract must be newly formed tissue, and whether the opening persists or not.

Dr. Thomas S. Cullen (Baltimore, Md.): I would like to ask Dr. Mayo to explain on the black-board how he puts these tubes in.

Dr. H. M. Richter (Chicago, Ill.): I should like to ask Dr. Mayo to bring out one point in closing the discussion, and that is as to the question of drainage of the biliary ducts through the common duct versus through a tube through the abdominal wall. The question is whether in those cases where he is satisfied that he has completely relieved the obstruction in the common duct, he is not willing to close the common duct as he would the intestine, for instance, by suturing it, close the abdomen without drainage, and rely on the common duct to be the drainage-tube of the biliary ducts. What I have in mind particularly is the matter of routine treatment of stones in the common duct, whether it is not well, after removing the stones, to close the common duct as one would close the intestine, and close the abdomen

as after suturing a loop of the intestine. I have closed the abdomen after doing cholecystectomies for a number of years except in those cases where the oozing from the liver surface seems unusually persistent. In fulminating infections I should be afraid to close without drainage. Recently I have closed the common duct, simply making certain there was no obstruction at the lower end, oftentimes opening the duodenum to observe the biliary orifice, and also closing the common duct by suturing and closing the abdomen without drainage. It seems to me that the logical thing to do in draining the biliary ducts for jaundice or otherwise, is to use the common duct as a drainage-tube.

While a larger proportion of the cases in which there is jaundice may be accompanied by the danger of hemorrhage, the preliminary treatment of these cases, as Dr. Mayo has suggested, by blood-transfusion would lessen the danger. A larger proportion of the jaundice cases would offer perhaps more contra-indications to closing the abdomen without drainage than would cases without jaundice.

Dr. E. M. Sala (Rock Island, Ill.): I would like to ask Dr. Mayo in what percentage of cases gall-stones are reformed after they are removed.

Dr. Charles E. Bowers (Wichita, Kan.): I would like to ask Dr. Mayo to give us the surgical indications for the removal of the gall-bladder.

Dr. B. B. Davis (Omaha, Neb.): I was very much interested in Dr. Mayo's paper, and one point that occurred to me was the method of introducing the tube. I hope Dr. Mayo, in his closing remarks, will go a little more fully into that.

I appreciate what Dr. Richter has said in regard to the advantages of closing these things up and closing the wound. It is the ideal thing to do. The next time I visit Chicago, I shall go around and see Dr. Richter do some of this work. Bile is a sort of uncanny fluid and will get where you least expect it. I have had many cases where I got no bile-drainage, yet after a day or two it has come through in very good volume, and I feel in cases of that kind, if I had closed the wound, I probably would have been in trouble. Until I see some definite reason for changing my plan, I shall certainly continue to leave a little drainage in all these cases.

I like the tube Dr. Mayo has shown us, and I feel as if every once in a while there will be a chance to use it.

I am especially interested in his giving us a little more detail in regard to his method of introducing it.

Dr. D. W. Basham (Wichita, Kan.): As so many questions have been put to Dr. Mayo, I would like to ask him to emphasize the importance of care in dealing with adhesions in this region. We have had some unfortunate experiences in being too radical in dealing with these patients.

Dr. H. M. Richter (Chicago, Ill.): Fearing the statement made by Dr. Davis may go without any further consideration, I wish to say that my idea of leakage of bile following closure of the duct, or ligation of the cystic duct in cholecystectomy is this: leakage of bile is insured by putting in drainage; it prevents primary union. If you wish to insure against bile-leaking, you must avoid putting in drainage.

Dr. R. C. Coffey (Portland, Ore.): I do not see any object in sewing up the duct. In the first place it is infected. Drainage is the one thing you want. If you have a stone you have got infection, and you will get better results if you establish drainage. I see no particular reason for closing the duct except to see how close you can get to danger.

Dr. Mayo (closing): If I do not answer all the questions that have been asked, I hope the members will speak up.

Doctor Richter reports closing the common duct without drainage after removal of stones. I have not gone this far, as I believe that drainage is safer for the patient, although in cholecystectomy cases of a simple type I often close the abdomen without drainage. We look on cholecystitis as the antecedent condition of all gall-stone conditions, and, after a very large experience in both cholecystostomy and cholecystectomy, I would recommend cholecystectomy in most cases of gall-stones and of cholecystitis without stones. We see no more reason why a diseased gall-bladder should be retained to give further trouble or imperfect cure than why a diseased tonsil, tooth, or appendix should be retained. I see many cases of recurrence of gall-stones in patients who have had drainage. Pancreatitis is only partially understood. It is most frequently secondary to an infected gall-bladder. Note should be made of the condition of the pancreas at all operations in the upper abdomen, since the pancreas has its own group of symptoms, which are often mistakenly attributed to the gall-bladder.

GASTRO-ENTEROSTOMY STILL THE TREATMENT FOR CHRONIC GASTRIC AND DUODENAL ULCER

Robert C. Coffey, M. D.

PORTLAND, OREGON

In discussing the advisability of a surgical procedure for a given pathological condition, we have to consider several points:

1. Immediate danger resulting from the operation itself.

2. Subsequent dangers, more or less intimately associated with the results of the operation.

3. Amount of final relief of morbidity.

4. Life expectancy of patient following the operation for a given condition.

The last topic has recently been discussed by Balfour in the November, 1919, *Annals of Surgery,* in connection with the study of gastroduodenal ulcer. This is going to open up one of the most interesting phases of the subject of our paper, but is one which can be discussed knowingly only after many more years have elapsed. However, Balfour's paper constitutes one of the most interesting contributions to this subject which have been presented.

In the study of this phase of the subject I shall confine myself very largely to my own work, and shall include in this study every case of chronic gastric or duodenal ulcer which has been operated on in my regular operating hospital. This report does not include approximately twelve operations done outside

of my regular operating hospital for the reason that I have had no opportunity to keep a record of these cases. Of these outside cases not reported here, one died as the result of faulty technic. I was holding a clinic in a distant city, demonstrating the "no-clamp" operation. The operating-room was strange, and all assistants and instruments were unfamiliar to me. In addition to this, I was talking and operating at the same time. The surgeon whose patient I was operating on spared me the painful news. After some months, I wrote him point blank, asking for the condition of the patient. He stated that the patient died from hemorrhage a few hours after the operation. Undoubtedly, in my effort at demonstrating, combined with strange surroundings, I overlooked a blood-vessel at the time of the operation.

In discussing statistics we must remember that they are only of relative value, no matter how accurate or how long the period covered or how extensive the individual's practice. Therefore, statistics which include less than five or ten years of a surgeon's practice, I would consider of very little value. Statistics which include a single year's work of a surgeon's professional lifetime are of almost no value taken alone. Statistics in which a surgeon reports a hundred consecutive cases of major operations performed without a death are worse than valueless, as a rule, because, in the first place, the motive for presenting such a series of statistics is not scientific, but egotistic. We would all like to report such statistics, but when we consider the seriousness of scientific facts dealing with human life, they must be thrown out of consideration entirely.

My first gastro-enterostomy for duodenal ulcer was performed on April 14, 1904; the last on September 22, 1919, but before I had performed a gastro-enterostomy for ulcer I had done several hundred experimental anastomoses on animals, and had also mas-

tered the through-and-through suture as taught by Connell, so that, technically, I was quite well prepared to do an anastomosis.

The total number of cases of gastroduodenal ulcer I have treated by operation from April 14, 1904, to October —, 1919, is 233. The deaths from operation were 10,—4.33 per cent.

In Balfour's paper, published in November, 1919, in *Annals of Surgery,* 2,431 cases are reported as having been operated on in the Mayo Clinic between 1906 and 1915. Of these, 545 were gastric ulcers with 4.5 per cent mortality, which amounts to about 24 deaths. One thousand six hundred and eighty-four were duodenal ulcers, with 2 per cent mortality, or about 34 deaths. When thrown together and averaged, the total mortality of the Mayo Clinic for nine years, from 1906 to 1915, including 2,431 cases of gastroduodenal ulcers, is 58 deaths, or a mortality of 2.38 per cent.

The Massachusetts General Hospital reports for the four years (1911, 1912, 1913, and 1914) show 164 cases of chronic gastric and duodenal ulcers treated by operation with 11 deaths, or 6.7 per cent.

Finney reports 200 cases treated in the thirteen years from 1902 to 1915, with 12 deaths, or 6 per cent.

Eiselsberg reports ten years' work, from 1904 to 1914. In this, he reports 460 cases of gastric and duodenal ulcers treated by operation. Of these, 38 died, or 8.3 per cent. It is further noted in his paper that there were 41 pylorectomies in which the death-rate was not stated. This, undoubtedly, would have still further raised his mortality percentage.

The above reliable statistics will show in a general way the mortality attending the surgical treatment of ulcer of the stomach and duodenum.

It is very important to study the cause of death in this series. In my 233 operations for gastric and duodenal ulcer, the first death was No. 20 of this series, December 6, 1907. The patient was an old man, more than sixty years of age. The operation lasted more than two hours, although only a simple gastro-enterostomy was performed. He never passed any urine after the operation was performed, and died in convulsions three days after the operation.

The second death was in case No. 43 of this series. He died October 28, 1910. The patient was a healthy man about fifty years of age, with an obstructing ulcer at the pylorus, making an ideal case for permanent cure. Thirty hours after the operation the patient, who had been perfectly normal up to that time, began to show an increasing pulse-rate without nausea and without passage of blood from the bowels. He gradually grew weaker, and died twenty-four hours from the time symptoms began. Post-mortem examination revealed the fact that the anastomosis was in perfect condition, so there was evidently no hemorrhage at this point. Careful search revealed a slit about one and one-half inches in length in the mucous membrane, located about an inch from the anastomosis; running across this slit was a large open blood-vessel. The slit had been made by the pressure of the clamps, and the large vessel had been devitalized and exposed thereby. The stomach being in good condition and the hyperacidity marked, the wall of the devitalized exposed vessel had apparently been digested at this stage, and the hemorrhage began. Incidentally, I think I may state that it is probable that most cases of hemorrhage coming on from twenty-four to sixty hours after a gastro-enterostomy are due to this cause. Hemorrhage coming from the line of union should appear much earlier than this. Therefore, although clamps are of great service in the technic of

an operation, it must not be forgotten that they offer a very definite danger.

Our third death occurred in case No. 63, December 12, 1912. This followed a Rodman pylorectomy and gastro-enterostomy performed at the same time. This patient died of pneumonia, but was otherwise a very healthy man.

In the early stages of stomach surgery, pneumonia was the great danger. The dictum of Mayo and others, recommending the upright position for these patients, greatly lessened this danger. In our experience, we have learned to use about three grains of camphor in oil every three hours for the first twenty-four hours after a stomach operation.

The fourth death occurred in case No. 71, May 29, 1913. This followed an Eiselsberg exclusion operation with posterior gastro-enterostomy. Patient died with persistent vomiting of bile and acute dilatation of the stomach. A postmortem was not held, but I am sure that death was due to too much tension at the point of anastomosis; it sharply angulated the intestine.

Our fifth death occurred in case No. 98, July 30, 1914, and followed an extensive sleeve resection for an ulcer along the lesser curvature. This patient died from shock within a few hours after the operation. It may have been hemorrhage.

Our sixth death was in case No. 108, January 6, 1915. The operation was an Eiselsberg exclusion, with posterior gastro-enterostomy. The patient died of regurgitation of bile and dilatation of the stomach, undoubtedly due to too much tension on the anastomosis by the stomach or a twisting of the intestine too far at the time of operation.

Our seventh death was in case No. 120 of this series, July 9, 1915. About one-third of the stomach

was removed, with the idea that it was probably malignant. The patient recovered from the operation as far as shock was concerned. On the second day he began to vomit bile and any food that was put into his stomach. This kept up until, on the eleventh day, a second operation was attempted, when it was found that the very short stub of stomach, passing through a rather short, fat mesentery, had made such a drag on the point of anastomosis as to funnel the mesentery and sharply angulate the intestine below the anastomosis.

The eighth death occurred in case No. 137, March 7, 1916. In this operation a Finney pyloroplasty, combined with a Balfour cautery operation for an ulcer on the lesser curvature, was performed. Patient practically passed no urine from the time of the operation to his death, two days later.

The ninth death occurred in case No. 182, October 18, 1917, as the result of hemorrhage, coming on six days after operation. Hemorrhage came on very suddenly, and was repeated two days later with the result of death. Unfortunately, I was so engaged at the time that I could not have a postmortem performed, but this patient had an acute cold at the time of the operation; had a severe cough from the time of the operation until the hemorrhage took place. There was, probably, a broken mucous membrane, due to clamp pressure.

Patient No. 180 died a month after leaving the hospital of empyema. This patient had a cold when he was operated upon, and had a severe cough all the time he was in the hospital, which was no doubt followed by empyema after he left the hospital, producing his death.

We had two other stomach patients, Nos. 183 and 184, in the same ward, who had very close calls as the

result of infective colds developing in this ward. Incidentally, we may state that operation on a patient with even a slight cold is a very serious matter and should never be done.

The tenth death followed an operation for duodenal ulcer, which had developed in a patient who had had incomplete rotation of the gastro-intestinal tract. The duodenum went directly downwards on the right side of the spinal column, externally to the ascending colon, and below the cecum, exactly in the same manner as noted in the arrangement of a dog's gastro-intestinal tract. The ulcer was large, quite acute, located well down the duodenum, near the bile-duct, thus making excision or a Finney pyloroplasty impracticable; the duodenum running directly downwards from the bile-duct was not very movable. There was no way by which the loop of intestine could be brought up for an ordinary type of posterior gastro-enterostomy except by a very long loop, which must necessarily originate down near the cecum. Therefore, an opening was made into the lesser peritoneal cavity back of and below the pyloric end of the stomach. This end of the stomach was drawn out through this opening for the duodenum, which had a very short mesentery. An anastomosis was made then between the stomach and the duodenum about two inches below the ulcer. A good deal of tension was left, but it was thought that it would work. The tension, however, seemed to be so great that it did not work, and on the fourth day after operation the abdomen was again opened, and a sharp kinking was noticed at the anastomosis, brought about by the pulling backwards of the stomach. Separating this and producing a better condition than the one before was quite an extensive ordeal and proved to be too much for the patient, who died a few hours after the second operation.

Another death occurred about this same date, but this case, obviously, has no connection with the operative mortality for duodenal ulcer, as will be shown by the following report. The patient came in having had apparently a total obstruction for several days, almost a total obstruction for a much longer time. The stomach contained large quantities of foul matter. The patient was brought in for the purpose of emptying and cleansing his stomach for a day or two before any operation was attempted. When the nurse first introduced the stomach-tube, the patient became strangled and began to cough violently. Soon he began to cough frothy blood, and went into quite rapid collapse, due to the hemorrhage and to the dyspnea. A little later, examination showed complete consolidation over the left pleural cavity; no breath-sounds on the left side. It was evident that the lung had been ruptured by the coughing. The patient remained in a doubtful condition for seven days. With a collapsed lung and no food whatever going through the pylorus, his condition became desperate. It was obviously necessary to get a quick opening from the stomach to the intestine; therefore under local anesthesia the abdomen was opened and a quick gastro-enterostomy performed, with hope of getting immediate relief. This case, of course, became an emergency operation, and could not properly be included in operative results for chronic gastro-duodenal ulcer. It is mentioned here, however, because the case was referred for operation as a chronic duodenal case, and this report makes the record straight.

The most important feature of the second point of our discussion, namely, *remote post-operative complication,* is the formation of secondary ulcers. We have had secondary or recurring ulcers in the following cases:

In Case No. 44 a recurring ulcer developed after excision of an ulcer located on the posterior wall, near the lesser curvature of the stomach. The lesser peritoneal cavity was opened and packed with gauze, stomach turned up and the ulcer excised from behind. The patient did fairly well for a few months, but soon began to develop her old symptoms. She came in for examination about three years later. The *x*-ray examination showed a definite hour-glass contraction. The ulcer has recurred and the patient is probably no better than if no operation had been done.

The next recurrence was in patient No. 69 of this series. The ulcer was excised and the patient made a good recovery, but later has returned.

The third case was in No. 72. An Eiselsberg exclusion and gastro-enterostomy were performed for duodenal ulcer July 22, 1913. The patient did fairly well for a few weeks, but returned on January 23, 1914, six months after the operation, and the ulcer had recurred. It was found in the stomach, distal to the anastomosis, and was about two inches in diameter. The ulcer was excised and the opening closed. A year later the patient came back in a very weakened condition. The ulcer had recurred in practically the same place. Operation was again attempted, which resulted in the death of the patient.

The fourth recurring ulcer was in case No. 83 of this series. The first operation was performed January 5, 1914. The patient was a doctor. He had a previous exploratory operation for supposed duodenal ulcer. The previous surgeon had found adhesions in the neighborhood of the duodenum, but had failed to locate an ulcer, and had closed without doing anything further. On January 5, 1914, we did an Eiselsberg exclusion with posterior gastroenterostomy. The patient was not as well after the

operation as he should have been. A few months later he returned with certain symptoms of a recurrence. We opened the abdomen and found an ulcer about two inches in diameter in the stomach distal to the anastomosis. The ulcer, however, involved the anastomosis in this case. The anastomosis was cut off, the ulcer removed, the stomach closed, and the intestine closed. Then a long loop anterior gastro-enterostomy was done. In a short time the patient began to have trouble again. We did not look upon further operation favorably, and he was not getting satisfactory relief, so he went to Rochester. On the way there his secondary ulcer apparently perforated. He was in a very serious condition. In talking to Dr. W. J. Mayo, he left the impression that a simple gastro-enterostomy had been done. Doctor Mayo opened his abdomen to relieve the acute perforation. The perforation had occurred well up in the left side. Anastomosis was cut off and the stomach and intestine closed. Twenty-four hours afterwards, the patient showed no evidence of bile or other secretions in the stomach, and was not doing well. Doctor Mayo wired me, asking what operation I had performed. I told him that I had done an Eiselsberg exclusion operation. He immediately took the patient to the operating-room, and under local anesthesia drew the severed and closed ends of the stomach and duodenum together, and made an anastomosis. The patient made a good recovery, but soon began to show symptoms again, so three months later he went back to Rochester, when it was found that another ulcer had formed where the last anastomosis had been made. This ulcer was removed, and a plastic operation was done. He did well for nearly three years after this, when suddenly he had a very severe hemorrhage, continuing for some days, which it seemed would result fatally. He gradually recovered from the hemorrhage, but was in a very desperate condition, and he had

a very extensive hernia from his numerous operations. The skin had become so thin that the intestines almost came through. Owing to the numerous scars, it was not thought wise to open immediately over the stomach, so an incision was made in the healthy skin diagonally across the lower margin of the ribs and ensiform cartilage, and the flap was thrown downward till the stomach could be reached. The neighborhood of the stomach was surprisingly free from adhesions. The finger, passed down towards the pylorus on the outside of the stomach, indicated a hard ring around the outlet. An anterior gastro-enterostomy seemed to be the only hope of accomplishing anything. A loop of the jejunum was brought up and sewed to the anterior surface of the stomach. The stomach was opened. A finger was passed downwards to the outlet, which was practically closed, and at this point another ulcer had developed. The anterior gastro-enterostomy was completed, and the patient has done very well ever since. His last operation was performed about five months ago. It is difficult to tell what the future has in store for this patient.

The fifth case of secondary ulcer was operated on December 23, 1915. No. 134 of this series. Ten months after this operation the patient returned, having had severe symptoms for several months and alarming symptoms for the previous few days. The abdomen was opened; a secondary jejunal ulcer had perforated. The anastomosis was cut off, but the patient died within forty-eight hours.

The sixth occurred in case No. 144 of this series. In an hour-glass stomach, based upon an extensive old ulcer of the lesser curvature, also a pyloric ulcer, with a large indurated mass around it, the middle of the stomach was resected, and end-to-end anastomosis made along with a gastro-enterostomy distal

to anastomosis. The patient did well for a couple of weeks, then began to show stomach symptoms. These were not very severe, so she got up and was around in very good condition. On the thirtieth day after operation, following a full breakfast, the patient developed an alarming hemorrhage from the stomach, and died within thirty minutes. I was called and immediately made a post-mortem examination, and found that a secondary ulcer, about two inches in diameter, had formed along the line of the circular anastomosis. Digestion apparently had corroded a large vessel, which was standing wide open in the wound. The induration around the pyloric ulcer had practically disappeared.

The seventh patient to develop secondary ulcer was No. 148 of this series. Operation was performed November 18, 1916. The ulcer was along the lesser curvature. The pylorus was wide open, and therefore the Balfour cautery was used. On April 20, 1917, the patient returned with the same symptoms. The ulcer had re-formed and was much worse than when it had been cauterized before. At this time it was excised and a posterior gastro-enterostomy performed.

The eighth case was in a patient who had been operated on for pyloric obstruction seven years before. He came back complaining of severe diarrhea. Immediately after eating any food his undigested food began to pass out through the rectum. After two weeks' observation the abdomen was opened; a large inflammatory mass was found, involving the transverse colon and jejunum distal to the anastomosis. On further investigation it was found that an opening existed between the jejunum and the colon, about five-eighths inch in diameter. A jejunal ulcer had formed distal to the anastomosis; adhesions to the transverse colon had taken place, and an opening between the two intestines had been automatically

established. The two intestines were severed, the openings closed, a large fold of omentum interposed between the two intestines, and the abdomen closed.

In addition to these cases, three of our cases have had severe hemorrhages several months or a year after operation. Whether the hemorrhages were due to new ulcers or to the bleeding of the old ulcers, we are not able to determine. These cases have been without pain and usually have had but one or two severe hemorrhages.

Case 9, No. 132 of this series, was operated on December 2, 1915, for hour-glass contraction based upon a large ulcer of the lesser curvature. Sleeve resection, return of ulcer and hour-glass stomach.

It will thus be seen that of the 233 cases operated on for ulcer, 9 have had definitely demonstrated secondary or recurring ulcers. Of these only two were following simple gastro-enterostomy. In all, 3.8 per cent of the ulcers have recurred either at the point of excision or a new place. There are probably others which have not given so much trouble.

Of the 8 sleeve resections, two, or 25 per cent, have had recurrence of the ulcer. Two have had recurrence of the ulcer in the line of suture. Of the 11 cases of excision of the ulcer, either with the knife or the Balfour cautery, without gastro-enterostomy, 3 have developed a recurrence of the ulcer. Out of 22 Eiselsberg exclusion operations, 2 have developed secondary ulcers, and these have recurred repeatedly after removal (9 per cent); while out of 165 simple gastro-enterostomies, only 2 have been known to develop secondary ulcers, about 1.2 per cent.

Of the 3 cases having severe hemorrhage at a remote period following operation, only one occurred in the 165 simple gastro-enterostomies—a little more than 0.5 per cent, while 2 of the 22 Eiselsberg operations,

or 9 per cent, in addition to the two definitely proved ulcers in this group, developed severe hemorrhage.

Now, what about the expectancy of life, as regards cancer, following ulcer treated by these various operations? Of the 233 cases thus operated on for ulcer of the stomach and duodenum, 4 have been known to have developed cancer.

The first case we can report as having died of cancer, No. 51 of this series, was operated on May 10, 1911, for what appeared to be a duodenal ulcer located at the pylorus. A posterior gastro-enterostomy was performed. The patient died of carcinoma of the stomach in 1915, four years after the operation.

The next patient, who was believed to have died of cancer, was in case No. 74, operated on August 4, 1913. An Eiselsberg exclusion operation was performed. The patient died two years later with stomach trouble and anemia; it was thought by the family physician to be cancer. However, this may also have been a secondary ulcer.

The third, No. 81 in the series, was operated on December 29, 1913, for what appeared to be an extensive indurated ulcer. A Rodman pylorectomy was performed. The patient died of cancer of the liver a little more than a year later.

The fourth patient to die of cancer, case No. 143 of this series, was operated on September 11, 1916, for an extensive saddle ulcer, four inches in one direction, and four and one-half inches in the other. The ulcer in no way resembled a cancer either from within or without. The middle of the stomach was removed by sleeve resection. The patient made a perfect recovery, developed ventral hernia, which was repaired six months later, at which time no evidence of recurrence could be detected, but the patient returned on the 7th of October, 1918, with a definite mass involv-

ing the liver, and all the evidences of cancer. He lived only a few months afterwards.

Thus, out of the entire 233 patients operated on for gastric and duodenal ulcer, only 4 are known to have developed carcinoma, and 2 of these occurred in cases in which the ulcer area was excised; the other, if it was cancer at all, followed the Eiselsberg exclusion, and only one patient, as far as we know, has developed carcinoma in the entire series of 165 simple gastro-enterostomies. However, I am frank to admit that we have not completed our follow-up system on these patients as we would like to, and other cases may show up later. The fact that we have been able to learn of only one patient in the gastro-enterostomy list who has developed cancer, while there have developed three in the other much smaller list, is at least suggestive.

It is fair to state that the large saddle ulcer, on closer, later microscopic examination, showed strong evidences of malignancy, so it had probably taken on malignancy when it was removed.

The case in which pylorectomy was performed was examined microscopically and pronounced non-malignant. While we have not completed a systematic follow-up of all these cases, as far as relief of the morbidity is concerned, all the indications are so far that the general health of the patients who have had a simple gastro-enterostomy is better on the average than of those who have any of the radical or combined operations.

In studying these cases from the four standpoints brought out in our opening sentences, we find the following:

From the standpoint of mortality, the simple gastro-enterostomy shows a total mortality of 4 in 165 cases, or 2.42 per cent. All other operations combined, in-

cluding 67 cases, show immediate mortality of 6, or about 9 per cent. In the 165 cases of simple gastro-enterostomies, only two secondary ulcers have been known to result, while seven out of 67 of the more direct and radical operations, or more than 10 per cent, have developed secondary ulcers. Of 165 simple posterior gastro-enterostomies, only one case has developed cancer, while two of the 67 cases of excision are known to have developed cancer, and a third probably developed cancer.

As to the relief of morbidity, all the evidence we have at hand indicates that the simple gastro-enterostomies have given better results from the standpoint of the recovery of the patients than have any radical operations.

In discussing the question of cancer in its relation to ulcer, of course, we must take into consideration the fact that three-fourths of all the ulcers are duodenal. These practically never develop in cancer, so that the cancers following ulcer are limited entirely to the 2 per cent found in the stomach.

Another thing to be considered in a spirit of fairness is, that the border-line cases are most likely to be removed by radical operation. But making full allowance for all these matters from my own experience, I am fully convinced that the proper treatment of most gastric and duodenal ulcers from which the suspicion of malignancy can be removed with a fair degree of certainty is as follows:

Do a gastro-enterostomy and await results, no matter where the ulcer is located. If trouble develops later, it is then time to open and do a radical excision. Excision, after a gastro-enterostomy has been performed, carried practically no mortality with it, no matter whether done with the Balfour cautery or by excision with a knife. The Balfour cautery operation seems much simpler, and can be done much quicker.

Concerning the *technic of gastro-enterostomy* we may briefly discuss the principles. I think it has generally been conceded that the best application of the jejunum to the stomach is a short loop with the application of the jejunum downwards and to the left, ending at the greater curvature of the stomach, as recommended by Dr. W. J. Mayo. The suture material is still debated. Dr. C. H. Mayo for a while thought the secondary ulcer was due in certain cases to these stitches. This, I believe, he concedes now is not always true. At least one of the cases reported in our series shows five recurrences, and in three of the subsequent operations I believe catgut was used exclusively. Personally, I am afraid to risk catgut entirely, although I believe it is used at the Mayo Clinic with satisfactory results. It is true that the external non-absorbable thread of a gastro-enterostomy is usually found hanging in the base of a secondary gastro-jejunal ulcer if the ulcer exists.

In early experimental work on animals, I observed that an interrupted suture around an anastomosis, if it had penetrated the mucous membrane, would cut its way out in a few days. If the interrupted suture did not penetrate the lumen of the bowel, and was used as a Lembert suture, these sutures would remain encysted in the peritoneum for many months without giving trouble. A continuous linen or silk thread used for the inside suture was usually found for a few weeks after the operation, but eventually was thrown off in the bowel. The continuous suture, which was intended for the peritoneal suture, frequently penetrated the lumen of the bowel or stomach. Such a suture remained in the wound for months and probably even years.

While I am not convinced that a large number of secondary ulcers are due to such sutures, I agree that a large continuous, non-absorbable suture can cer-

tainly do no good, and probably in many instances does harm. Therefore, I never use a continuous linen or silk thread in an anastomosis. An interrupted linen suture, if it penetrates the lumen, will free itself in a few days. If it does not penetrate it, it will remain encysted so that it can in no possible way do harm. In our work, then, we have adopted the principles of several operators.

We never give a stomach patient a cathartic the night before operation. We give a high flushing of soda (a teaspoonful to a half gallon of water), and another early in the morning. If obstruction is considerable, the patient is given warm water by the rectum every four hours during the night. The stomach is washed before the patient is brought to the operating-room. After the abdomen is opened in the median line, or slightly to the left, a stomach tube is passed into the stomach, and all gas and any fluid remaining are allowed to escape. The ulcer is examined. If it is a duodenal ulcer and is on the anterior surface, the omentum from above and below is drawn across the duodenum to take care of any possible fat perforations. The transverse colon is lifted, the peritoneal fold corresponding to the ligament of Treitz located, and the middle colic artery identified. This artery is usually found about the peritoneal fold mentioned. The transverse mesocolon should be opened in the large arterial loop to the left of the middle colic and to the left of the peritoneal fold. If the fold extends far down, it should be clipped. Usually, there is a very small vessel running diagonally across the space where the mesocolon is to be opened. This vessel sometimes bleeds enough to make the field bloody. With two forceps, one on either side of the incision to be made, the clear mesocolon is picked up and cut through, exposing the posterior wall of the stomach in the lesser curvature. By examining

the stomach above and below, the operator may get his bearings and pick up the stomach wall with two forceps, one on the posterior surface of the stomach, above its middle, toward the pyloric end; the other forceps should be placed toward the cardiac end of the stomach and near the greater curvature. The jejunum is directed toward the left, a short loop is picked up, and a fold of gauze is placed between the stomach and jejunum to catch any discharge of blood or contents. The jejunum is picked up about two inches from its origin. A linen suture is passed through the outer wall of the intestine and stomach near the mesentery border of the jejunum. This suture should pass beneath the holding forceps, and when tied should take its place. Another suture of the same kind picks up the jejunum near its mesenteric border about two inches caudad to the first suture. This suture is then passed through the outer coats of the stomach beneath the forceps near the omental attachment. The forceps is removed and these sutures are used for traction loops. Another similar suture is then made to divide the space between these two loops. These spaces are in turn divided in the same manner, and so on until the required number of sutures are placed. These sutures are intended to go only through the outer coats of the intestines. However, if they happen to penetrate the lumen, no harm is done. After the row is completed, two quilt sutures are placed near the ends corresponding to the traction loops. After these penetrating quilt sutures have been tied, the first loops are cut away, and the deep penetrating loops are used for traction. A full line of quilt sutures is then placed between these two loops. These deep loops are made to grasp any large vessel which may show.

The walls of the stomach and intestines are then cut down to the mucosa until it herniates. A tannin-

catgut suture is then begun at the proximal end of the wound, and is made to penetrate the mucosa and all thicknesses of the viscera. Large vessels along the stomach and intestines have all been caught with the forceps; a lock stitch passes down the whole length of the incision to serve the purpose of both strength and hematostasis.

At the distal end of the cut the stitch is securely locked, after which the stomach and intestinal cavities are opened. All bleeding vessels coming from the outside of the wound are caught. They may be either tied or held with forceps until they are caught in the continuous catgut suture. After turning the distal angle of the wound, the continuous suture is changed from a lock stitch to an in-and-out right-angle stitch, and continued to the point of beginning. This combination stitch was used by Dr. C. H. Mayo many years ago.

Having completed the circle, the middle row of deep-penetrating quilt sutures is placed, after which the row of interrupted peritoneal sutures completes the anastomosis.

One of the important steps of a gastro-enterostomy is properly suturing the mesentery borders and the stomach and intestines. It is very important that each stitch be carefully watched to see that the intestines are not twisted in any way. The mesocolon should first be sutured to the stomach by a few interrupted linen sutures. After this line is completed, a fold of the loose mesentery is drawn over the jejunum by a few interrupted sutures. The space between the jejunum and the mesentery is closed with interrupted linen.

DISCUSSION

Dr. Thomas S. Cullen (Baltimore, Md.): In one instance I had a rather uncomfortable experience with the clamp method. About five o'clock one afternoon I did a posterior

gastero-enterostomy for a duodenal ulcer. At eight o'clock the patient vomited some blood. We should have operated at once, but delayed, hoping the bleeding would cease. At midnight her condition had become precarious. I made an incision in the anterior stomach wall about an inch away from and parallel with the gastero-enterostomy. The stomach was full of blood. One blade of the clamp had cut through the gastric mucosa about 1 cm. from the gastero-enterostomy opening, and at this point a rather small blood vessel was spurting. One catgut satisfactorily controlled the bleeding, and the patient recovered.

I would like to ask Dr. Coffey in what percentage of cases he gets a vicious circle.

Dr. Joseph Rilus Eastman (Indianapolis, Ind.): I suppose I ought to apologize to the Association for presenting another gastro-enterostomy clamp. I think the jaws of this clamp are light enough so that it would be much safer to use in respect to the possibility of producing pressure by crushing than the Roosevelt clamp, which has done such yeoman service for surgeons operating in this field. I think this is about as simple a gastro-enterostomy clamp as can be made. It has no top or bottom, or left or right; one takes the handle in the left hand. The jaws are springy, they do not crush, and are long enough so that one does not bring the stomach and intestines near the hilt of the instrument where it must be stronger than out here (indicating). One never has to apply artery clamps to the distal end of the jaws, because with these little nuts one can approximate the tissues as firmly as one wishes, grading the pressure with the little clamps, and these blades or jaws are covered with rubber tubing precisely as the jaws of the Roosevelt clamp.

It has a number of advantages. It has a narrow metal bar. I suppose some of you have had the experience I have had, namely, that on the stomach side one gets a bit of traction as the tissues are skimpy, and if one has to pull them over the bar it makes a little difference. One would like to have one-eighth of an inch, and you get it if this bar is narrower, and it can be just as well narrowed like that (indicating), and it has plenty of strength. After that work is finished, these little wing nuts are so applied that it is very easy to pull them out in the suture line. It does not scratch anything; it does not injure the tissues in the slightest degree. The length of these jaws is an advantage. One has plenty

of room after bringing the end of the suture line back into these very strong jaws near the lock of the Roosevelt clamp. In order to get good approximation at the distal end, one must use considerable pressure here, and I can imagine one might produce an ulcer with the Roosevelt clamp, but it would be rather difficult to imagine how one, who is careful, could produce by crushing pressure an ulcer by using this light clamp.

Dr. C. E. Tennant (Denver, Colo.): The clamp Dr. Eastman has presented has, I think, many advantages. I have never had the opportunity of using it. I have taken quite an interest in the Roosevelt clamp, because I was the first to use it when my assistant (Dr. Roosevelt) presented it, and I still feel there are many advantages to the Roosevelt clamp. One thing we had to contend with in building this clamp was the difficulty in getting equal pressure on the clamp from hilt to tip, and I am convinced that any instrument which we may use in a gastro-enterostomy may be employed with sufficient force to produce pressure and following it a necrosis, but any of these clamps, either a light or a heavy one can be used with gentleness, and there will be no damage done to the tissues. One thing you will find in the use of the Roosevelt clamp is this, take a toothpick for instance, and assuming we have rubber tubing to cover the jaws, now making an approximation of the jaws, we find the pressure is quite equal from the hilt to the tip. Consequently there is no unequal pressure exerted anywhere along the course of the blade. This, I think, recommends the clamp which has proven so essential to the clamp method of doing a gastro-enterostomy. There are several features of this clamp which still hold good. One is that the weight is just sufficient to hold the tissues in good position without lateral play or displacement. The rigid portion is in the center. The criticism which Dr. Eastman made is a good one, consequently when we do a gastro-enterostomy we take pains to have sufficient tissue elevated so that we have met that objection. It is simply done. It is seldom necessary to raise the tissue up through the clamp after once placing it in position, especially with the use of good rubber tubing and care in the adjustment of it. I believe the clamp still has its advantage and has done a great service.

Dr. B. B. Davis (Omaha, Neb.): I feel we are indebted to Dr. Coffey for presenting a paper of this kind this morning, and I feel further the weight of the criticism of the clamp

quite forcibly, inasmuch as I lost a patient not long ago from hemorrhage which I believe was due to the same cause as attributed here, namely, to the crushing of the clamp. This clamp of Dr. Eastman's appeals to me, and there is an advantage in operating with a clamp. I did quite a number of my first gastro-enterostomies without clamps, and I think they are not absolutely essential. I think the technic laid down by Dr. Coffey is very good.

It seems to me the vital point before us today is not so much the mortality at the time of the operation, although we want to keep that down as low as possible, but the ultimate results, and I have felt for a long time that we are not getting the ideal ultimate results in these cases that we thought we were getting and hoped we were getting. A paper recently published by Thomas Brown, of Johns Hopkins, which many of you may have seen, from a medical standpoint deals with a large number of cases where the results from operations are not satisfactory. His paper appeals to me very strongly, and I think we have got to get down to more team work between the surgeon and the internist, if we are ever going to get anywhere in this kind of work.

I have had cases I am really ashamed to admit I ever operated on, where I have done gastro-enterostomies, and at the time the immediate results were beautiful. The patients came out in fine shape and during the first two or three months were in excellent condition, but finally they were having symptoms which were about as bad as before operation. In some of these cases there has been a recurrence of the ulcer; but in some way we have got to have after-treatment in these cases that is of sufficient merit to guard against putting the patient in the same condition that first produced the ulcer. I do not think there is any doubt that most of us have been more or less careless about this. We discharge our patient; we do not give him full instructions, and in many cases he goes home thinking he is well; he does not return to his physician, and the result is he goes to work and abuses the stomach just as badly as he did before the first pathology occurred. So, it seems to me, we must get down to a different basis in the conduct of these cases, and after operation is done, one important step must be taken in bringing the patient back to good health, and that important thing is the after-treatment he receives and the diet he has months and even years after operation.

Dr. W. D. Haines (Cincinnati, Ohio): In 1907 I had my first experience with hemorrhage following gastro-jejunostomy. I attributed the post-operative hemorrhage to faulty technic in doing the operation and went to the laboratory and did some more experimental work. There was seemingly no difficulty in getting good results in the laboratory, but in the hospital an occasional post-operative vomiting would be accompanied by varying amounts of hemorrhage, never in alarming quantities but sufficient to render the operator and attendants uncomfortable.

One day we were operating upon a patient whose stomach was considerably dilated at the time the abdomen was opened. In order to facilitate the placing of the through-and-through sutures the clamp on the stomach side of the anastomosis was removed to permit the gas to escape. As the gas separated the margins of the stoma, we discovered a strip of mucous membrane which had been partly detached from the muscularis by the crushing influence of the Kocher clamp.

The strip of membrane was an inch in length, completely detached at one end, and there was considerable oozing from the denuded muscular surface. As the margins of the denuded surface lay in the pressure lines of the clamp it was evident that the denuded surface of the stomach wall could not have been included in the grasp of the through-and-through suture with the clamp in situ, thus readily accounting for the post-operative hemorrhage which we had occasionally encountered. A lighter clamp (Pean) was substituted for the heavy Kocher, but it was too light and occasionally would slip, but we have not been troubled with post-operative hemorrhage since changing to lighter clamps.

We tried doing a few operations without clamps after the method of Deaver, but fear of contaminating the peritoneum caused us to look for a lighter clamp which would work without doing injury to the stomach or bowel wall. We have been using one of Mr. Lane's gastro-jejunostomy clamps for a number of years, and we find it a very satisfactory instrument.

Dr. Coffey is quite right, I think, in attributing hemorrhage in some of the patients to the presence of infection; again, one must remember the possibilities of rapid destruction of suture material (catgut), active ulcer, or cancer in seeking for an explanation of the source of hemorrhage following operation on the stomach.

Dr. Arnold Schwyzer (St. Paul, Minn.): We hear different views expressed as to whether we should use clamps or not, and whether we should use a continuous suture or not; and I am under the impression that we are talking about things that are not so very important.

I reported my stomach work from 1904 to 1917 before the Minnesota State Medical Association, and, while the material is not very large (about 140 cases), the one point I wished to bring out was the end-results found in following the cases up. The answers from patients were very surprising to me. After a year or two, it has often been stated that these patients frequently get bad again. That has not been true in our material. These patients that really get trouble, get it usually within the first year; and the conclusion was that if a patient goes one year after operation without recurrence of the trouble, he or she, as the case may be, mostly stays well. If a patient has a good result a year after operation, he is usually all right, and the percentage of complete cures, where the patient says "I feel very well," is much greater in the cases ten and twelve years after operation than it is a year after operation.

In doing gastro-enterostomy for stomach ulcer we have done something real for the patient, and, as I said in the beginning, we are here speaking of details which can be looked at from different points of view; we may use clamps and continuous suture or not. I use continuous sutures all the time, and I use three layers of continuous silk or linen, and in all these cases I have not had secondary ulcer formation. When I have it, I may change my ways.

Dr. George N. Kreider (Springfield, Ill.): Let me give you some concrete examples of operations. Dr. Haines is camping on the right ground. Yesterday I made some remarks about examining patients in regard to bone disease, and the next man said it goes without saying that we should examine a patient carefully before operating, but that does not always go in practice. Many people are operated on without having a thorough examination made.

I read a paper before this Association two years ago on gastroptosis, and since then this matter of examining patients carefully beforehand has been called to my mind more thoroughly. As a result of that paper I had a young woman from St. Elmo, brought to Springfield for trouble with her stomach. A diagnosis had been made in St. Louis by two

physicians, according to the statement of her brother, and some sixteen or twenty *x*-ray plates were made. She had been to Dayton, Ohio, and to Effingham and Mt. Vernon, Illinois. The condition of her stomach and transverse colon, as shown by the *x*-ray examination, was quite remarkable. The stomach was in the pelvis, and had no more apparent vitality than a rubber bag. When it came to a picture of the transverse colon, nearly all of the trabeculæ that naturally come in the transverse colon were absent. That showed a very serious lack of vitality of these two organs.

These gentlemen who had taken all these pictures had overlooked the real cause and source of the trouble, because when we looked into the patient's mouth we found every tooth diseased and we found her tonsils in a diseased condition, much to her doctor brother's surprise. I said to him here is where the pathology begins; whether it ends there or not I do not know. But it did end there. We had the teeth extracted and the tonsils removed, and in the course of eleven days she gained twelve pounds. When we brought her down to the laboratory for a scale test, the pathologist did not recognize her. That woman has not had any more trouble with her stomach. She had been having this trouble for eleven or twelve years.

Dr. C. E. Bowers (Wichita, Kan.): There are three things of importance in this class of work,—the suture material used, the size of the opening in the stomach, and the trauma inflicted during operation.

First, we use fine chromicized catgut for the inner row of sutures, and fine plain catgut for the outer row of sutures. Any non-absorbable suture remains long after it has served its purpose and becomes a foreign body, produces irritation, and may become infected and responsible for failure.

Second, we use two catgut guy-rods, instead of clamps, placed about two and one-half inches apart. Each guy-rod picks up stomach and intestine, and when traction is made with the guy-rods the surfaces of stomach and intestine neatly approximate, which greatly facilitates in the speedy application of the first, or outer, row of sutures.

Third, the opening in stomach and intestine should not be longer than one and one-fourth inches, as cases have been reported where the intestine forms herniæ into stomachs where large openings had been made.

Dr. Coffey (closing): I thank you all very much for the discussion. Dr. Cullen asked how often we have a vicious circle, and I will say, in answer to his question, we have had a vicious circle only in the cases in which we have reported too much tension from which the patient died. We have had no vicious circle following the cases that lived. A vicious circle is purely a question of mechanics of the operation at the time it is done. In the cases in which I had a vicious circle and the patients died, I know it was my own fault. Most of the deaths occurred from my own fault, either from hemorrhage or too much tension on the suture, or from twisting them. It is purely a question of twisting the anastomosis for one thing; and another thing is too large an opening. I have seen two cases of vicious circle due to too large an opening. This is a curious thing in which the spur comes up from the bottom and protrudes into the stomach, and the intragastric pressure closes the distal opening of the intestines like a valve. We have seen two cases of this kind in which we cut off two-thirds of the anastomosis and simply narrowed it, and the patient was relieved.

Dr. Eastman's clamp, I think, is undoubtedly an improvement over the others, but I do not see why we want to use a clamp. What is the use of it? We can do the operation just as quickly without it. We can control hemorrhage with hemostatic forceps, and consequently there is no use for a clamp.

I was much interested in the cases of serious hemorrhage reported by Dr. Cullen, Dr. Davis, and Dr. Haines, after gastro-enterostomy. I am sure that the hemorrhages which occur three or four days after operation are practically all due to the use of the clamp, because we had no hemorrhages coming on at that time in the cases in which we did not use the clamp.

Concerning the ultimate results of medical treatment which Dr. Davis mentioned: The point I attempted to bring out was, that this is not purely and strictly a surgical condition. We know that the cases of ulcer that are cured repeatedly by physicians develop a scar in the bottom of the ulcer. They are not cured; they are relieved temporarily, and I doubt whether they are cured by gastro-enterostomy. When you break into these you start an ulcer over again. By cutting them out and cutting carefully back of the ulcer that has formed an hour-glass stomach, you relieve the patients. What is a gastro-enterostomy? Gastro-enterostomy is medical

treatment. That is what it is done for. It is not surgical treatment except as a means to an end. Gastro-enterostomy is Dr. Sippy, a drug-store and a stomach tube put inside of the patient for constant and ever ready use.

Dr. Haines spoke of ballooning of the stomach. I left that out, but it is described in the text of the paper.

In the technic the first thing in doing a gastro-enterostomy, when the patient is on the table, is to have the anesthetizer use a stomach-tube and see that the stomach is collapsed. We uniformally use a stomach-tube in these cases.

Concerning the clamp or no clamp method, I think if you take one hundred young men and train them all in both the use of the clamp and without it, you would find practically all of them would do the operation without a clamp. There are doubtless many surgeons who can do the operation easier with a clamp than without it. I make a pelvic examination with my right hand, and I make an abdominal examination with my left hand. I cannot tell much about the abdomen with my right hand or by a vaginal examination made with my left hand. That is the way it goes. We can make an examination, but we do it better in one way than in another. While it may be simpler and easier to use clamps if you are accustomed to them, if you once acquire the technic of doing gastro-enterostomy without clamps, you will have no use for them thereafter. I would not use them if they gave me the same results.

I was much interested in what Dr. Schwyzer said about the suture material. Moynihan has had the same experience. He uses linen and claims to have no bad results from it.

As to the diagnosis: It is very essential to make it, if possible, before one starts to operate, and the *x*-ray comes to our aid as the final arbiter.

The question of removal of foci of infection is very important. If a patient comes from a long distance and wants something done, we usually do a gastro-enterostomy for ulcer, and take care of the other foci of infection as the patient is recovering, such as the removal of the tonsils, and so on, and we have good results in that way.

As to syphilitic ulcer: It can be ruled out as there is never achylia with simple ulcer, so far as we have been able to determine. Eusterman, of the Mayo Clinic, reported fourteen cases in which there was achylia, and two of those developed

carcinoma and died, and the rest of them showed a positive Wassermann. I have never seen such a thing as a stomach with normal acidity in which the ulcer was syphilitic. I have never seen a case in which the ulcer was normally acid in which there was syphilis. A syphilitic ulcer gives achylia, and one of the most beautiful specimens you ever saw we removed and found we had a syphilitic ulcer. The patient got well.

Dr. Haines: What suture do you use as the seromuscular?

Dr. Coffey: I use fine linen.

Dr. Haines: We are using catgut.

Dr. Coffey: I use linen because I think it is safer. Maybe it is not. The Mayos use catgut. I use two rows of interrupted linen and one of continuous catgut. Catgut inside.

INTESTINAL ANASTOMOSIS—NEWEST, QUICKEST, AND BEST [1]

B. M. Ricketts, M. D.

CINCINNATI, OHIO

The principle of intestinal anastomosis by invagination, cuff, and suture, is probably the simplest, quickest, safest, easiest, and freest from unpleasant complications of all methods, both suture and mechanical.

The nine illustrations presented are given to demonstrate the simplicity and feasibility of the method described, not only to those who are familiar with intestinal surgery, but to those who wish to become so.

Coäptation by suture of mucosa to musosa, muscularis to muscularis, and serosa to serosa, is ideal in theory, but seldom realized, extremely difficult, and not necessary, as is demonstrated in intussusception with spontaneous severance of the invaginated gut and when union has been accomplished with mechanical devices.

The author summarizes his conclusions as follows:

1. Nine hours is sufficient time for lymph-union.

2. The proximal end of the bowel should extend from one to one and one-half inches into the distal end in end-to-end anastomosis, though less in lateral anastomosis.

3. Invaginated ends and portions of gut will eventually atrophy without stenosis.

4. Fine round, curved, or straight needles carrying fine silk or linen thread are best.

5. Needles with cutting edges should be avoided.

---

1. Author's abstract of his paper.

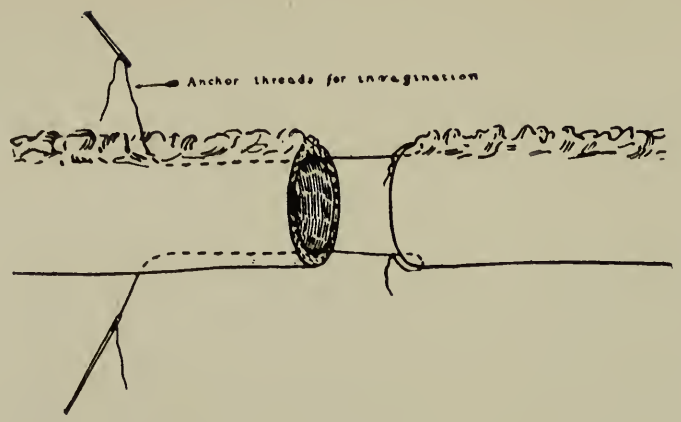

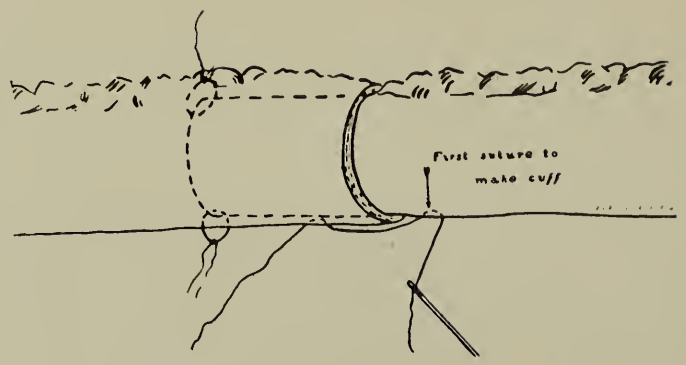

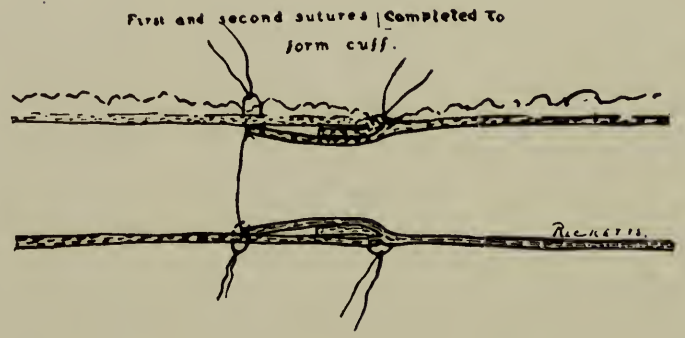

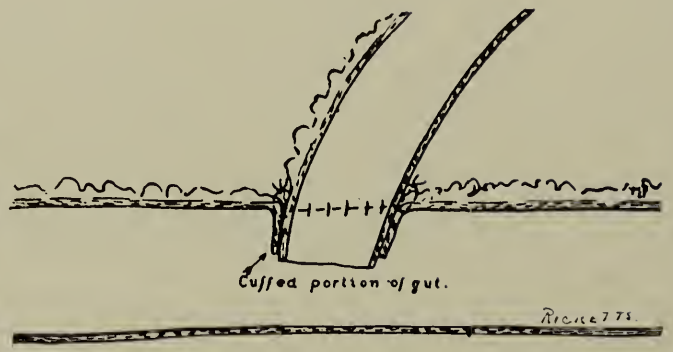

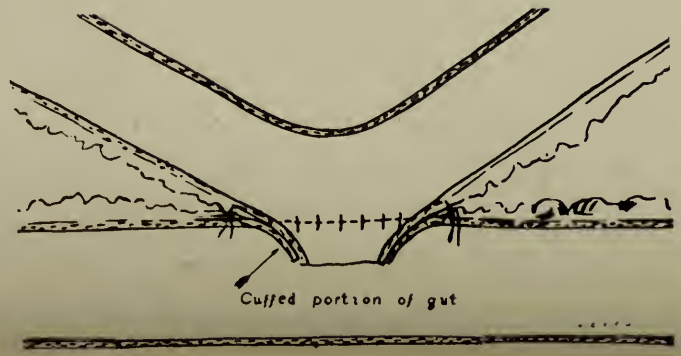

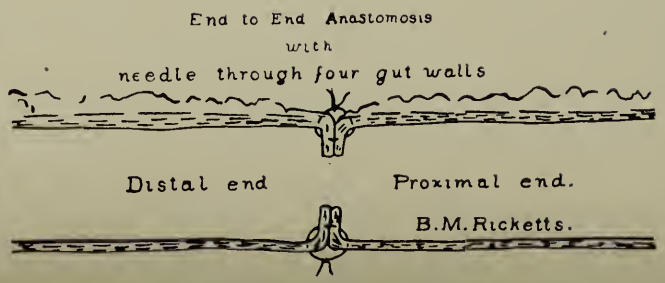

Serosa of two gut ends infolded and fixed by suture to unite.

6. It is not necessary to perforate the gut-wall with the needle, though this is of little or no consequence.

7. Interrupted, rather than continuous, sutures should be used.

8. Catgut should never be employed for this purpose.

9. Sutures should not be drawn excessively taut, but close enough to insure perfect coäptation.

10. An extra row of sutures may be applied as a precaution.

11. The method is especially advisable to hasten the completion of the operation. Expedition is always advisable.

A CONGENITAL ANOMALY OF THE DUODENUM AND ITS SURGICAL SIGNIFICANCE

LEONARD FREEMAN, M. D., F. A. C. S.

DENVER, COLORADO

In operating upon the stomach for supposed occlusion of its outlet, especially before the extensive use of the Röntgen ray, surgeons occasionally were puzzled by finding a dilated pylorus and duodenum, instead of a stenosis. Considerable time elapsed before it was recognized that partial chronic obstruction of any portion of the intestinal tract may result in "backing up" of the contents of the bowel upon the stomach, giving rise to stenotic and other gastric symptoms and possibly duodenal ulceration. I am convinced that this important fact is not kept in mind as clearly as it should be, thus leading to the overlooking of conditions that could be corrected, if searched for intelligently.

Among a multitude of possible obstructive lesions are those occurring at the duodenojejunal angle. It will be remembered that Lane described a "kink" sometimes existing where the fourth portion of the duodenum appears from beneath the root of the transverse mesocolon to the left of the spine, to merge into the jejunum. The duodenum is here ascending and fixed, owing to the absence of a peritoneal covering, while the jejunum is descending, enveloped in peritoneum, and free, thus giving rise to the normal duodenojejunal angle. (Fig. 1.)

[1]Dr. C. U. Collins has short-circuited the obstruction by anastomosing the ascending portion of the duodenal loop to the jejunum, which occasionally may be advisable.

Occasionally, a peritoneal fold from the colonic mesentery (ligament of Treitz) pulls on the jejunum, and increases the normal angulation until it becomes pathologic, the condition being perhaps aggravated by contracting bands. It is obvious that when once recognized the difficulty can be corrected by dividing this fold, which is readily done because of its accessibility.

I wish to describe another form of duodenojejunal kink, depending upon the persistence of an embryonic condition.

It will be recalled that the adult normal duodenum swings in a somewhat angulated loop from the pylorus downward to the right of the spine, passing beneath the hepatic colon to its pelvic side. It then runs directly across the spine, beneath the superior mesenteric vessels and the mesentery of the small intestine, and finally ascends obliquely toward the left to join the jejunum at the base of the transverse mesocolon.

During early fetal life, and in certain lower animals, the entire duodenum is covered by peritoneum and possesses an individual mesentery; but later the terminal three-fourths loses its peritoneum, becomes fixed in fibrous tissue, and attaches itself to the root of the transverse mesocolon, to the left of the median line, at the duodenojejunal angle. This attachment ("duodenal fold") occurs early and is quite constant.

In the anomaly under consideration, the duodenum, after passing beneath the colon, travels, as it were, too far toward the pelvis, thus bringing the transverse portion an unusual distance below the mesocolon. In addition, after passing beneath the colon, it does not become subperitoneal, as it should, but lies free in the abdominal cavity, with a peritoneum and mesentery of its own, as in the fetal state just mentioned. But in spite of this freedom, the duodenojejunal angle

often remains firmly attached on the left to the root of the mesentery of the transverse colon by the duodenal fold, thus suspending the intestine and possibly kinking it at the point of suspension. (Fig. 2.) A certain amount of twisting of the bowel may contribute to the tendency to obstruction, as may likewise the inclination of the root of the mesentery of the small intestine to push downward the free duodenal loop, especially if filled.

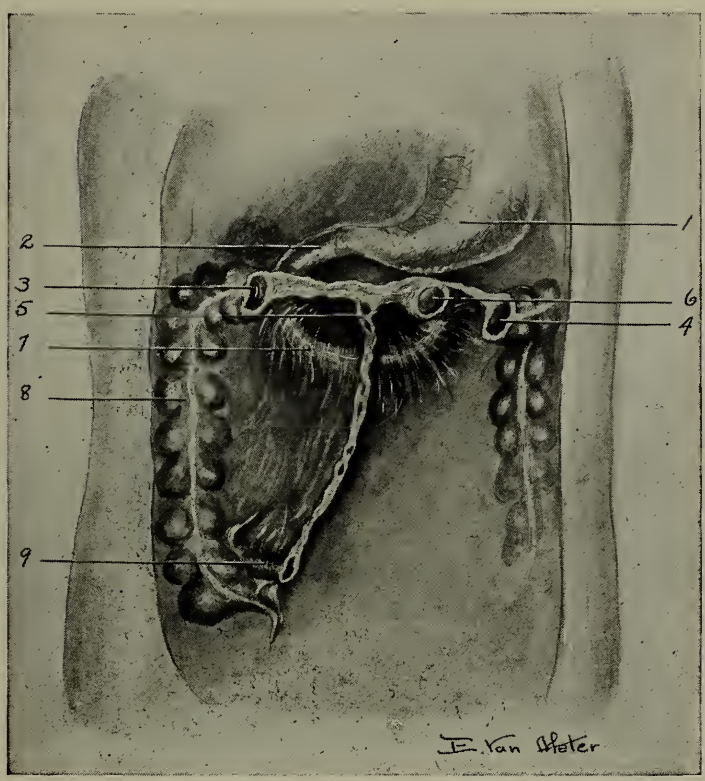

Fig. 1. 1, stomach; 2 and 7, duodenum; 3 and 4, severed ends of transverse colon, removed to show root of mesocolon; 5, mesentery of small intestine; 6, duodenojejunal angle; 8, ascending colon.

The peculiarity is of course congenital, but we may assume that it can increase with age, because of thickening and contraction of the suspending ligament, until partial obstruction finally appears. This leads to hypertrophy and dilatation of the duodenum, with

stagnation of its contents, and eventually to widening of the pylorus and alterations in the stomach.

The symptoms so closely resemble those of duodenal ulcer with pyloric obstruction that a correct diagnosis is hard to make without help from the x-ray, and even then certainty is not apt to be obtained short of an exploratory incision. In operating, however, it is important to bear the possibility of the trouble in mind, for "what we don't think of we may not see."

The surgical treatment may be difficult because of certain more or less awkward complications.

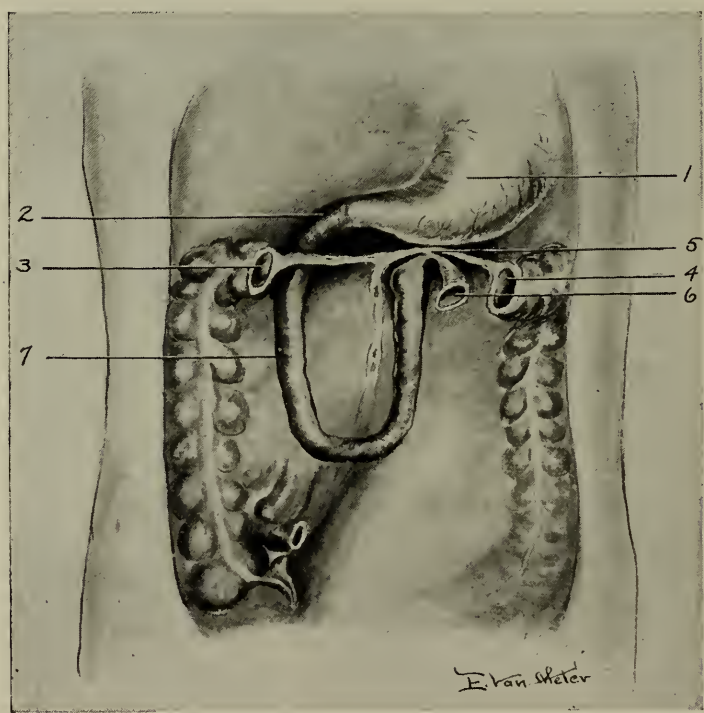

Fig. 2. 1, stomach; 2, first portion of duodenum; 3 and 4, severed ends of transverse colon, removed to show root of mesocolon; 5, "kink" at duodenojejunal angle; 6, jejunum; 7, free duodenal loop (length exaggerated in drawing) passing beneath mesentery of small intestine.

1. The lesion is deeply situated, being due to a firm adhesion pulling the gut down to the root of the colonic mesentery, the embarrassment often being

further increased by the location of the incision, which is usually to the right of the spine, while the kink is to the left.

2. The inferior mesenteric vein and left colic artery lie just external to the kink, and may be injured if care is not exercised. Hence one should cautiously strip the peritoneum bluntly from the surface of the bowel, rather than attempt to divide the ligament with knife or scissors, taking care that the gut is not perforated during the manipulation.

3. The completion of the procedure exposes a raw intestinal surface which may be quite large, and requires attention in order to prevent troublesome adhesions. Sometimes the edges of the torn peritoneum can be so stitched together as to cover the denuded area without compromising the lumen of the bowel; occasionally it may be desirable to use a free omental graft, as I have done in one instance.[1]

Since my attention has been called to this subject I have operated upon six of these duodenal obstructions. In no one of them, in spite of the *x*-ray, was the diagnosis made previous to the operation, the real trouble being discovered only after a lesion near the pylorus had been excluded.

SUMMARY

Partial occlusion of the duodenum at the duodenojejunal angle, simulating pyloric obstruction, occasionally occurs from the persistence of a condition normally existing in fetal life. In this, the duodenum, instead of appearing in the abdominal cavity from beneath the transverse mesocolon to the left of the spine, as it should, emerges to the right, its transverse and ascending portions possessing a peritoneal covering and mesentery of their own, similarly to the rest of the small intestine, instead of being fixed in fibrous

tissue, as is normally the case. At the duodenojejunal angle, however, the bowel is hung up to the root of the colonic mesentery by a firm adhesion (duodenal fold of fetal life), the "kink" thus produced being intensified by the downward pull of the free duodenal loop. This kink is deeply situated, and in freeing it care must be taken not to injure the bowel, the inferior mesenteric vein or the left colic artery. A considerable denudation of the gut may be necessary, which should be covered either by reuniting the peritoneum or by means of a free omental graft.

FOR DISCUSSION SEE PAGE 360

ABDOMINAL DRAINAGE

D. W. Basham, M. D.

WICHITA, KANSAS

Drainage may perform a most beneficent office in abdominal surgery, but it often requires much judgment and experience to determine when, where and how it should be employed.

It is not so much a question as to whether the patient may recover with or without a drain in the abdomen, but it must be remembered that a drainage-tube is a foreign body and is, therefore, capable of harm, and, consequently, should not be employed except in the presence of positive indications. The question then arises as to what constitutes these positive indications for drainage after celiotomy.

There are three principal reasons for abdominal drainage: the presence of extensive purulent infection; extensive operative manipulations, which are sure to be followed by copious secretions or hemorrhage; and when the hollow viscera have been dealt with and leakage is to be feared.

As previously intimated, it not infrequently becomes a mater of extreme delicacy of judgment to know just when drainage is indispensable to the well-being of the patient. This question arises oftener when dealing with mild and limited infections, for most of these will do perfectly well without a drain, while, occasionally, drainage may be necessary to recovery. There are, in fact, many cases of appendicitis where the exudate is more heavily lymph-laden with leucocytes than a purulent fluid. Most of these cases require but a brief period of drainage not exceeding three or four days duration. In many such cases if

the source of the infection has been removed and the field of operation has been carefully cleansed, drainage may be dispensed with without hazard to the patient.

It must not be forgotten that drainage is often more necessary for the protection of the wound in the abdominal wall than the site of operation within the peritoneal cavity. This is made apparent to the surgeon occasionally by the infection and separation of the incision, while the intra-abdominal trauma heals without incident.

When in doubt, omit the drainage. Let us get away from indiscriminate and unnecessary drainage.

A spot of gangrene in the appendix, when there has been no leakage nor much suppuration, does not constitute a positive indication for the use of a drain, provided, of course, all the affected tissue is removed. If sphacelation is extensive and there are necrotic areas in the adjacent bowels, drainage is indispensable. In this instance a drain correctly placed affords a means of egress for the contaminated post-operative wound secretions, and serves as a protection in case of sloughing and perforation, which may be delayed until several days after the operation. In very extensive operations, as, for example, the Wertheim procedure for uterine cancer, which may be followed by infection, and where there is sure to be copious oozing of serum and perhaps hemorrhage, it is wise to drain, but unless infection actually takes place drainage should not be prolonged.

The drain employed after cholecystectomy need not be large and should not be left in place longer than necessary to determine as to the occurrence of infection or leakage of bile. If we could depend upon absolute safety in the closure of the cystic duct stump with perfect aseptic technic in the conduct of cholecystectomy, it would be possible to dispense with drainage altogether in this operation.

The material employed for drainage is of much importance. It is rare, indeed, that we find it any longer necessary to employ the extensive and painful gauze drains of the Mikulicz type. In the vast majority of our cases a small drain is all that is necessary. The cigarette form of drain, consisting of a wick of gauze wound about with oil silk or some other like material, constitutes one of the most generally useful forms of drainage. A rubber tube split spirally with a wick of gauze in the center is also a useful device for drainage. The rubber tube has the disadvantage of sometimes causing pressure necrosis followed by leakage or hemorrhage, thus rendering the danger much greater than when some soft yielding substance is used. No rigid unyielding substance should ever be employed for abdominal drainage. This applies with special importance to pelvic operations where the drain may come in contact with the iliac vessels. The management of a drainage case is of exceeding importance.

The principal disadvantages attending abdominal drainage are the inevitable production of adhesions; the possible contact ulceration into the hollow viscera; the conduct of staphylococcic infection from without to within; and imperfect and delayed healing of the wound followed by hernia.

With these facts in mind it becomes evident that the materials employed in the construction of drains should be of the most non-irritant character possible, and that the period of drainage should be terminated at the earliest possible moment. When a drain is placed in the abdomen it is received there as a foreign body, and much the same things are seen to occur that transpire when the appendix becomes infected. There is an alexic barrier membrane cast up round about the infected area and at its outer limits provided that the patient's resistance is sufficient to afford plastic ma-

terial for the purpose. If the drainage is efficient the area to be walled off will be greatly diminished in extent because of the diminution of the septic fluids retained in the peritoneal cavity. The protective barrier must be cast up at the outer limitations of the field of infection. This barrier consists of a thin adventitious membraneous structure supported by agglutinative adhesions between juxtaposed viscera, and when once formed no drainage can take place beyond its limits. If an area beyond the borders of the protective membrane becomes infected it must be considered and dealt with as a metastatic affair having no connection with the original focus excepting the lymp-channel through which the infection migrated.

With these facts in view there can be no practical justification for the continuation of the drain beyond the time necessary for the isolation of the area to be drained, for after this the sinus remaining after the withdrawal of the cigarette will remain open to permit the escape of any fluid left behind or forming later. Only in case of leakage or sloughing, is it necessary to continue the use of the drain longer than a few days. In most cases of appendicitis and in many pelvic cases the drainage material may safely be dispensed with in from four to ten days. Notwithstanding, the drainage, in all cases, should be allowed to remain undisturbed until its office is fully performed. When once removed it should not be reinserted nor replaced. Much harm is often done by the meddlesome and pernicious practice of trying to replace a drainage tube which has been withdrawn. If a drainage tube is once removed the loops of intestine fall together and fill the space left behind, and all efforts to re-introduce the drain in its original position will be futile and result in harmful trauma. Again, if a drain be allowed to remain too long in place the granulations along the sinus will assume a weak and fungous type, thus ob-

viating all possibility of firm union, and hernia with a weak abdomen inevitably follow. If the drain be removed permanently as soon as it has fulfilled its office, firm union will occur, and the healing will not be delayed more than four or five days longer than when no drainage has been found necessary.

There are a few important things to be borne in mind in the management of drainage cases. The abdomen should not be kneaded or manipulated with the idea of being able to expedite the flow of pus, for the very obvious reason that the pus or fluids may be forced into other uninvolved parts of the peritoneal cavity.

Cathartic medicines, especially those that provoke active intestinal peristalsis, should not be given when a drain is in place. Catharsis in the presence of these conditions often plays an important part in the causation of postoperative obstruction, a complication which but few surgeons are able to contemplate with unperturbed equanimity.

The diet also is a matter of importance in drainage cases. These patients should not be overfed, for an embarrassment of the digestive apparatus may invite the occurrence of disagreeable and serious complications.

To conclude, let us avoid indiscriminate drainage. Let the drain be placed in a careful manner so as to conduct the products of infection away from the field of operation to the outside of the abdomen. Let us avoid all sorts of manipulations of the abdomen with the purpose of facilitating the outward flow of pus. When the drain has completed its function let it be removed, and do not try to replace it; especially do not plug up the remaining sinus with gauze, which can serve but to obstruct the escape of the serous flow which must follow.

DISCUSSION OF THE TWO PRECEDING PAPERS

Dr. Clifford U. Collins (Peoria, Ill.): They say that honest confession is good for the soul. I am personally grateful to Dr. Freeman for bringing this subject before us today. My only regret is that he did not read it a year ago. He has well said that we may not see this anomaly unless our attention is called to it, even if it is right before us.

In the last year I have had a patient who had this condition as represented in this chart (indicating). She had vomiting and evidences of obstruction in some place. The *x*-ray did not show any obstruction in the stomach, but did show, although we did not interpret the condition, obstruction in the duodenum, a loop being too large and too far down. I sensed there was obstruction, but I did not sense where it was, and was not able to give a ready interpretation for it. I thought a gastro-enterostomy would short-circuit the obstruction. This was done, and we might have known what followed. The food went around the pylorus and went into the loop of duodenum. We made further *x*-ray examinations, three or four of them; and they showed this large loop, which was getting larger. I still did not sense exactly where the obstruction was, or what it was, until I heard this paper. We re-operated and found the loop here (indicating). It had a mesentery which was covered with peritoneum. I did the next best thing which was to short-circuit the lower part of the loop with a Murphy button, and that relieved the trouble because it drained the dilated loop. The patient has been well now for two months. I did not relieve the obstruction and should have been glad to have done that if I had heard Dr. Freeman's paper before.

Dr. Oscar M. Shere (Denver, Colo.): The paper presented by Dr. Freeman gives one a good deal of food for thought and study. I believe that the conditions described are somewhat analogous to the gall-bladder enlargements embodied in Curvoisier's law. Not infrequently a megaloduodenum is observed during abdominal operations, and, unless a painstaking anatomic study is made of the surrounding structures, the condition may be regarded as one of the idiopathic variety.

Since the duodenum is not provided with a mesentery it is therefore the least movable part of the small intestine under normal conditions. On the other hand we recall that the infracolic segment of the descending duodenum gets a

covering of secondary parietal peritoneum, the latter being subject to various fusions during embryonic life and finally making up the hepato-duodenal ligament, also the attachment of the duodenum to the colon. Any deviation from this normal arrangement would suffice to inhibit the duodenal looping, leaving the first portion a great deal larger than normal.

The essayist mentioned an atrophic form of duodenum. In such instances the reverse condition may exist from that encountered in the enlarged variety.

It is my opinion that in the majority of instances the two varieties described are to be explained along faulty lines in the stage of development instead of claiming any pathologic entity for them.

Dr. E. P. Quain (Bismarck, N. D.): I have had the opportunity to make a few observations of patients suffering from obstruction at the duodeno-jejunal junction, and I wish to put some of my experiences on the records of this Association. About fours years ago I was consulted by a woman who suffered from periodic attacks of nausea and vomiting associated with sick headaches. She was thin, anemic and typically enteroptotic. She had submitted to two previous operations, one for the removal of the appendix and the other to drain the gall-bladder. Neither of the operations had improved her condition; on the contrary she was gradually becoming worse. Her symptoms led me to believe that the chief cause for her present trouble was due to post-operative adhesions about the gall-bladder and duodenum, and for the third time her abdomen was opened. She had a number of adhesions between the pylorus, liver, duodenum, and gall-bladder, but nothing else abnormal could be found. The adhesions were severed and the raw surfaces treated in an effort to prevent re-formation of harmful adhesions. But soon after the operation the old attacks of pain, nausea, and vomiting reappeared. Feeling convinced that her trouble was from some obscure abdominal cause she was put through a course of more careful *x*-ray examinations of the gastro-intestinal tract than had previously been done. By means of the fluoroscope it was possible to determine that her descending duodenal loop was very low and that it was dilated. The loop descended practically to the pelvic brim. It was shown, too, that the contents were retained in the duodenum during an abnormally long time before they began to pass over into the jejunum. She was then opened again, and I readily found the

low dilated duodenum which I had failed to see at the previous operation. It was evident that there was an obstruction at the duodenojejunal junction. Further examination indicated that the cause of the obstruction was a constriction of the bowel produced by a downward drag on the superior mesenteric artery. An attempt was made to elevate the dilated duodenum to a point where it might empty more easily into the jejunum, but it was soon evident that this could not be accomplished. I could think of no other way to overcome the obstruction than by means of an anastomosis between the ascending part of the duodenal loop and the descending jejunum, and this was done. The patient recovered from the operation, and her previous spells of indigestion and sick headache have not recurred.

Soon after this experience I had another patient of the same general enteroptotic type who compiained of irregularly intermittent attacks of epigastric pain associated with nausea and vomiting. She, too, had had several operations without relief from her original symptoms. It was suspected that her case was similar to the first one described and the fluoroscope proved it. She was operated on, and the same general condition of the duodenum was found. A duodenojejunostomy was made, and her symptoms were relieved from the time of the operation.

Later, a pupil nurse, in the hospital where I worked, gave me the opportunity to study more carefully and for a long time the phenomena attending a descended and dilated third portion of the duodenum. She had suffered from "dyspepsia" and "biliousness" since childhood. Her digestion had rarely been free from trouble. In order to reduce her distress she was compelled to live on restricted diet consisting largely of liquids. But in spite of all dietary and other precautions she would have recurring attacks of such severity that she was frequently confined to bed for a few days without any nourishment at all. The most marked symptoms were epigastric pain, nausea, and vomiting of bile. She complained of nervousness and insomnia and finally became entirely incapable of continuing her work in the hospital. By means of the *x*-ray it was shown that the descending loop of the duodenum was very large and reached nearly to the pelvic margin. At the operation the same condition of well-marked obstruction at the superior mesenteric artery was found and a duodenojejunostomy brought about relief from the previous symptoms.

Besides the three cases mentioned I have operated on two other cases for the same trouble. All these operations were done before I went to the military service, and since my return I have had very satisfactory reports as to the results from the three patients whom I was able to reach with my inquiries. They had remained free from their previous pain, nausea, and vomiting and had been able to eat freely and gain flesh.

It can not be stated what the underlying cause for this abnormal condition of the duodenum may be in all cases. In some it is undoubtedly a manifestation of Glenard's disease, while in others there are mechanical and pathologic causes acting more directly against the proper emptying of the duodenum. I am convinced, however, that the condition presents a clinical symptom complex which can be recognized and which can be treated successfully in proper cases by the method I adopted. I believe this condition gives us a new angle from which the old-fashioned attacks of "biliousness," as well as many of the symptoms in connection with the more modern "enteroptosis" should be studied.

Dr. W. W. Grant (Denver, Colo.): I have greatly enjoyed Dr. Freeman's paper and the discussion on it.

I desire to say a few words concerning the second paper on abdominal drainage. The original experiments of Yates, confirmed later by the work of Rowntree, Hartwell, and others, have shown that drainage of the peritoneal cavity is impossible except for six to forty hours. Drainage should be used only in the presence of infection, and there are some who do not use it in cases of limited infection, thinking the leukocytes will take care of it.

Another thing, it seems to me well established, and that is, of all possible material for drainage, gauze is the worst, and is so accepted. Beyond a few hours gauze will drain nothing. It becomes a mucoserous plug and retains infection. A rubber drain is about the best for ordinary cases if you really need substantial drainage, although the best material experiments prove, which is perfectly sterile, is the glass drainage-tube. That was established by the experiments I have referred to.

Personally, I, in doubtful cases, as in gangrene of the appendix, use frequently a simple drain of gauze covered by gutta-percha tissue in the form of wicks or cigarette drain, and these are removed very early. I seldom use them beyond

thirty-six hours, and a drainage-tube a little longer in case of fecal fistula, and in cases of gangrenous appendix where the tissues surrounding are in such a state that prompt union is improbable and fecal fistula sometimes occurs. These cases are drained by a tube, and I change the tubes often. I have no trouble in re-inserting the drainage-tube. Encapsulation is soon established, but, as I have said, gauze should never be used unless the surrounding tissues are protected by gutta-percha tissue and ordinarily should not be used at all.

Dr. Donald Macrae (Council Bluffs, Iowa): Dr. Grant has just made the remark that a drainage-tube tract will be closed up in 36 hours, and yet he goes on and talks about the kind of drainage he uses. I think the war has taught us the absurdity of drainage of the peritoneum in the most acute infectious conditions. I think the war has also demonstrated the absurdity of drainage of the knee-joint by mechanical means. If there is any one thing the war has taught us, it has taught us not to drain a knee-joint by means of any mechanical device. I have seen many cases of shrapnel wounds of the knee-joint, where large foreign bodies have been removed, portions of the trochanters torn off, the synovial membrane sutured tightly, no drainage instituted, immediate passive motion, and the patient is up and about on crutches in two or three days. In cases of infection, after the simple procedure of opening a joint without any tubes or gauze, I have sent these patients walking around the hospital, on their feet, pus running down the leg onto the bandages about the ankle-joint. Some of them got very good results. If we go back thirty or twenty-eight years and consider what we used to do in cases of ruptured appendices and acute infectious intestinal tract, gastric ulcer, etc., we will remember that in the early days we put in not only one drainage-tube but from six to ten in various parts of the peritoneum. Most of these patients got off the table alive. You may also remember that later we were taught to eviscerate and wash everything off with gauze, and when we tried to cover every inch of the peritoneum most of these cases got off the table alive. Then came the stage, you remember, when patients were placed on their heads as a result of a great amount of experimentation. I believe Howard Kelly brought that out. It was thought the diaphragm would hurry up absorption, and so we stood our patients on their heads, and they all died. Then we got the Fowler position, tried it, and a great many of these patients

recovered. Even then some of the cases died as a result of drainage. Personally, I cannot see where there is any indication in the world for putting anything in the peritoneum to drain the peritoneal cavity. We must not get confused with local abscesses, with conditions in which it is necessary to pack to stop hemorrhage, or mechanical means of some character to render extraperitoneal drainage, such as we do by putting a tube in cases of cholecystectomy with the idea, not of drainage, but for catching the bile. That is not drainage.

You may remember that we started to introduce large tubes into the pelvis for drainage. We do that at the present time. It is my practice to use a tube half an inch in diameter, placed in the bottom of the pelvis, so that aspiration can be done every three hours by a nurse. The first syringe would pull out from one to two drams of bloody fluid; the second time you would pull out a dram, and that is all there was to it.

I am afraid to remove the tube early because we break down nature's barrier which is put up around the tube; we have an infected tract into the peritoneal cavity, and we get a general infection if we remove the tube too early. It is better to leave it a considerable length of time.

The work we saw in the way of closure of the belly at the front, especially in perforating wounds of the intestine, operating in six hours on many of the cases, closing the wounds up tight, cleaning up the territory as fast as one could by means of gauze, not manipulating the parts any more than possible, was excellent. I am satisfied in the old days we killed many patients by over-zealousness with the idea of removing mechanically a lot of infection. If the drainage-tube will not drain the peritoneum longer than two or three hours, I cannot for the life of me see any reason why we should drain at all.

So far as my own practice is concerned, I have cut out any idea of draining these cavities except in exceptional instances. The knee-joint has demonstrated this very forcibly.

With reference to surgery of the chest: I was with the French for a while during which time I saw the work of a well-known French surgeon (Ombredanne), who constantly opened up the chest, removed the foreign body or bodies, closed up the tract of the lung and pleura, and had primary union, with practically no reaction. This was astonish-

ing to me. The same thing was done with brain injuries, primary closure, closing up tight, skin and all.

The result of primary closure of these cavities was excellent in selected cases. Where one cleaned out the débris from the wounds and sewed them up without any drainage whatever, there was primary union, and since seeing those cases and observing the results of that method of dealing with them, I am beginning to wonder why we allowed the methods of drainage we did in years gone by.

I do not wish to be too radical, but I would suggest, instead of the old slogan "when in doubt drain," we substitute "when in doubt (peritoneum) do not drain."

Dr. Herman E. Pearse (Kansas City, Mo.): The solidity of every structure rests upon the security and fineness of its foundation. I would like to say as a foundation for this discussion on drainage, very briefly, that all pathological processes will get well by drainage. The principal drainage of the body is through its lymphatics and those eliminating organs that have discharging ducts. When it comes to the question of what shall we substitute for the natural drainage processes of the body, a foreign body—gauze, glass, rubber tissue, gutta-percha tissue—then we should decide carefully, and should use the judgment of a surgeon in order to see how far this crude preliminary drainage of a foreign body in the wound is going to be necessary, and we should consider it under two heads: first, how far is it necessary to drain pus or serum or blood from a wound? and, second, in putting in this foreign body, how far will it interfere with the proper lymphatic drainage, proper absorption, or real drainage, and when we do that we will put in less and less drainage-tubes and leave them in a shorter time.

Dr. W. T. Coughlin (St. Louis, Mo.): About three years ago our President (Dr. Roland Hill) read a paper before this Association on position in drainage of the abdomen. That paper contained some convincing information, and I hope that most of us were so convinced by it that we shall continue to use abdominal drainage for some time. The essayist this morning has not said anything at all about Dr. Hill's contribution on the subject. Dr. Hill in his paper referred to the fact that an interne in our City Hospital, in 1901, suggested turning patients on their faces for a short time after the operation, in order to facilitate drainage. The learned colleague, at that time chief surgeon there, retorted

with "why not stand them on their head?"—and the laugh was on me, for I was that interne.

When I began to do surgery I began to put my idea into practice, and I still practice the method. When placed on our City Hospital Staff, in 1914, I there instituted the method, and since then a large number of my colleagues on the staff have come to adopt it, so that now it is almost routine.

When drains come from all quarters of the abdomen, or from its upper half only, they are brought out through the incision, which is most often in or close to the mid line, and the patients are placed on their faces for from ten to twenty-four hours. Where the drains come from the right side and the pelvis, as a rule, they come out near the anterior superior spine and the patient is turned on his right side. Pillows are placed under the chest or liver in either case, and the bed is horizontal. We are fond of the method for it gives better results.

I have seen cases of all kinds closed without drainage, and I have seen many deaths. I have seen many similar cases closed with drainage, and I feel convinced that not so many died. I often close cases now where in years gone by we would have left a drain, but there are many still in which I use drainage. It is well known that the peritoneal fluid is antiseptic, and it has been shown very conclusively that a great deal of fluid is poured out of the peritoneum as soon as it is irritated. If you get the wound before bacteria have implanted themselves into the walls of the intestine or into the parietal peritoneum, and have begun to grow there, and close your gunshot wounds, your gut perforations, or an acute stomach perforation, or what not, you can get by without drainage. Those are different cases from the ones that come to you some hours after when bacteria are beginning to grow in various parts of the peritoneal cavity, and if you expect to be able to remove all the foci of infection without taking with you all of the peritoneum and most of the viscera involved—which would be disastrous—you will be disappointed. But if you put your patient in such a position that the excess peritoneal fluid can flow away as fresh fluid is secreted then you will do well. The fluid should gravitate to the opening The drain acts as an irritant and will soon be walled off and the opening closed. Whatever drainage of the cavity you are going to obtain must therefore be obtained within the next few hours. The infectious material is an irritant of the peritoneum, the handling at oper-

ation, even the exposure of its surface to the air irritates the peritoneum—the bacteria growing irritate the peritoneum and even the drain itself acts as an irritant. Irritation of the peritoneum leads to increased blood supply thereto and increases the quantity of fluid thrown out, increases the phagocytes, and opsonins surely do counteract bacterial growth. The fluid is more actively bactericidal while fresh, and provision is made for carrying of the excess so as to ensure a fresh supply constantly where the infective material remains. In this way very soon will the cavity cleanse itself, provided all macroscopic damage and foreign material were repaired and removed at operation. Some bacteria may even be washed out with the discharging fluid; at any rate the cavity soon becomes sterile and the drains can be removed in the course of a few hours. In certain cases I surely believe in drainage.

Dr. F. G. Nifong (Columbia, Mo.): I have a mentor at home who says that surgeons ought to have sense enough to know that water runs down hill. I have two patients at home lying on their bellies, so that the serum will run out according to the method of Dr. Hill and Dr. Coughlin.

I think one of the best evidences of a good surgeon, if one can judge of one's ability to do surgery, is to see how he handles septic cases and how he drains them. That would give me the best idea of his capacity. It is one of the things that requires more common horse sense than anything else.

Dr. B. B. Davis (Omaha, Neb.): I think I must be awfully old-fashioned because I still use drainage. However, I do not use it quite as often as I did. The argument has been made that the peritoneum is able to take care of these things. The standing Army of the United States was able to take care of ordinary things that came up, but when the World War came we called for volunteers and got a lot of them; and when, it seems to me, we have infection within the peritoneal cavity, with a whole lot of gross pus among the coils of the intestines, the only possible way to do the best for the patient is to use drainage. Do not use the massive drainage we used to use, but use tubes, and a tube introduced into the bottom of Douglas' pouch, I find to be the best, and I think drainage with the patient lying on his face is probably a great step in advance. In my estimation there are many cases in which we must use some drainage.

Dr. Freeman (closing): I have only a word to say. In such an anomalous condition as this the suggestion of Dr. Collins to do an anastomosis between the afferent and efferent loops is a good one in certain cases. However, in a good many instances it would be difficult. It generally would be far simpler to loosen the kink itself, as I have suggested, and in all my cases it has been possible to do so. I think it is a good rule not to tamper with the normal fecal circulation if it can be avoided.

THE SURGICAL TREATMENT OF EMPYEMA

W. W. Grant, M. D.

DENVER, COLORADO

Excepting the variety and unusual character of wounds treated in the war zone, probably no diseased condition during this period has excited so much interest and consideration as empyema and associated diseases.

The numerous pathogenic bacteria involved have been quite fully investigated and results published, yet in this connection we know only that the one most important mortal factor was the hemolytic streptococcus. The focus of infection is in the lung, infection of the pleura being secondary.

At this time I shall confine my remarks to my personal experience based upon the two epidemics in the winter and spring of 1917-18 and 1918-19, at the recruiting depot, Fort Logan, Colo. In view of the diverse opinions expressed and published as to the treatment, I think it important to give, in some detail, chief expression to this phase of the subject. It is of considerable interest to note that the influenza epidemic of 1917 and the spring of 1918 was attended by an epidemic of measles and scarlet fever, while during the last epidemic there were not more than half a dozen cases, and yet, proportionately, the mortality from pneumonia was decidedly greater in the latter epidemic. This was in a measure surprising, for it had been the universal experience of past years that the prevalence of measles was dreaded as the most dangerous and fatal complication of camp life, with the possible exception of typhoid fever.

In the epidemic of 1917 and the spring of 1918, I operated on 28 cases of empyema, with a mortality

of 6 cases; and in the winter of 1918-19 I operated upon 3 cases only, with no mortality. Yet, there were five to six hundred cases of influenza and as many cases of pneumonia as in the former epidemic. It was much more fatal and fewer cases reached the surgeon for operation. A detailed report of 28 cases was made to the Surgeon-General's Office.

My surgical assistant visited the medical wards daily with the attending physician in order to detect, as soon as possible, the need of surgical intervention in any case. Aspiration was freely employed as a diagnostic measure to determine the presence and the nature of the effusion and to relieve embarrassed respiration. This procedure also resulted in the cure of a few cases of serous effusion in the absence of empyema.

The first three cases were operated on under general ether anesthesia, one patient of these died shortly afterward. All other cases were operated on under local anesthesia of novocain, 2 c. c. of a 2 per cent solution being injected above and below the rib to be resected, aiming to block the intercostal nerves; and then 5 c. c. of a 0.5 per cent solution was injected into the surrounding tissues to be dissected. Two to six minims of adrenalin (1 to 1,000) were added to the solution, and I waited eight to ten minutes for the full effect of the anesthetic, when a few seconds' application of ethylchloride along the line of a crescentic incision made the incision painless and the resection of the rib with the shears practically painless.

In most of the cases there was no perceptible shock an hour later. In some, who were very weak, moderate lowering of the blood-pressure was noted, but the condition responded soon to salt solution, the rectal drip, and hot milk by stomach.

In all cases, twenty minutes before the operation, an ounce or two of whiskey was administered and a hypodermic injection of 1/6 grain of morphine with 1/200 grain of atropin and ½ grain of spartein. One to one and one-half inches of rib were resected: on the right side the eighth rib and on the left the ninth or tenth, usually in the posterior axillary line, the aim being to secure the most dependent drainage. A rubber drainage-tube, sometimes double, was immediately introduced and the tissues sutured snugly around it. The tube was fixed primarily with a stitch and a safety-pin, and the long outer tube dropped into a bottle of water beneath the bed, as in certain cases of gall-bladder drainage. The quantity of pus varied from two to four quarts. The discharge diminished rapidly and on the second or third day the patients were taken to the dressing-room at least twice daily and the cavity irrigated with a 5 per cent bicarbonate of soda solution, adding boric acid, and immediately followed by one ounce of a 7 per cent solution of iodine to four quarts of warm water, gradually increasing the strength. The drainage-tube was later cut off close to the skin and the wound protected with a pad of sterile gauze held in place by strips of adhesive plaster, and a larger pad over this fixed by a roller chest-bandage, until the discharge was greatly reduced and the drainage-tube no longer required.

Under this treatment the patients breathed comfortably, and the lungs expanded rapidly. In about half the cases, notably those not operated on before the end of the second or in the third week—the pus was in a partly organized or coherent mass of fibrin, in which it was necessary to use the forceps for the removal of the floating mass of exudate at the time of the operation. The play of the diaphragm was easily observed, and with long ring forceps and sterile gauze pads these lymph masses were wiped off the dia-

phragm and pulmonary and costal pleura, the drainage-tube being inserted as soon as this procedure, lasting a few minutes, was over.

For irrigation of the pleural or pus cavity, I alternated in some cases the iodine solution with a 0.5 per cent formalin solution. I made but little use of the Carrel-Dakin solution, because it required exceptional skill and absolute purity of material in its preparation, was difficult to keep, often painful in use, and required almost the constant attendance of a nurse for its most efficient administration. Furthermore, it was my conviction that the mechanical cleansing of the cavity was perhaps as important as the chemical action of drugs used as antiseptics. The Carrel-Dakin can not be effectively applied to the large pleural pus cavity through the small catheter tubes commonly in use, but it may be applied by irrigation like other antiseptic solutions.

When the cavity was so nearly closed as to hold only two or three ounces, the drainage-tube was removed, and bismuth paste with the addition of iodoform and balsam of Peru were injected, and a pad placed over the wound and fixed by adhesive plaster. It was necessary in a few cases to reopen the wound much later at the old site on account of a reaccumulation of pus, which showed that the cavity was not sterile and the tube was removed too soon. The tuberculous are more protracted.

The shortest period in which any patient returned to duty after operation was seventeen days, while the convalescent period, with most, was from two to three months. Two of the recovered were discharged (s. c. d.) six months after operation on account of tuberculosis, and one six weeks after complete recovery on account of exophthalmic goiter, which was not observed before the present illness.

It was my conviction and that of the attending physicians, based upon observation and experience, that the patients operated on seven to ten days after beginning of illness, or immediately after the formation of pus, did not progress as satisfactorily as those operated on at a later date,—from the fourteenth to twenty-fourth day from the beginning of the attack of influenza or pneumonia. Some of these cases followed lobar pneumonia, but the most dangerous and fatal were the bronchopneumonias from hemolytic streptococcic infection. A few facts concerning the six fatal cases are interesting, if not illuminating:

T. C., aged 27, was admitted to the hospital on December 27, 1917, with bronchopneumonia; operation by rib resection under general ether anesthesia January 4, 1917; death, January 5.

H. L., aged 24, was admitted to the hospital January 2, 1918; sick two or three days before admission to hospital; operation, January 5; death, January 22, from general sepsis with phlebitis.

A. G. W., aged 21, was admitted to the hospital April 3, 1918, with scarlet fever and bronchopneumonia; operation, April 10; death, April 18, with cerebral meningitis of suspected tuberculous origin.

H. G., aged 16, was admitted to the hospital April 9 with bronchopneumonia; operation, April 19; death, April 30—nerve type.

H. S. J., aged 19, was admitted to the hospital April 11 with bronchopneumonia; operation, April 18; death, April 20.

This and the preceding case were of a class with distressing nervous symptoms; restlessness, sleeplessness and mildly delirious with spells of stupor, but generally answered questions intelligently and took nourishment willingly and plentifully.

D. B., aged 20, was admitted to the hospital April 19 with pneumonia; operation, May 13; recovered from empyema, but late in convalescence developed mastoiditis and died from septic basilar meningitis June 22—nearly six weeks after operation for empyema; death clearly not due to pneumonia or operation.

Cases 3 and 4, especially, I believe would have stood a better chance of recovery had the operation been deferred a week, but this is purely speculative.

General anesthesia endangers the prognosis in these acute conditions and is in fact unnecessary, as the operation can be done so quickly, so safely, and so thoroughly under local anesthesia. The safest general anesthetic is undoubtedly nitrous oxid and oxygen.

The patients who had the capacity to resist successfully the acute stage of the disease in question seemed to acquire a certain degree of immunity to the infection which enabled them to resist the local empyema or suppurative pleurisy and operation better, and the mortality was less.

Nothing, in my opinion, is to be gained from operating on these cases until the acute influenzal and lung conditions have well passed the critical stage. The opposite course will increase the mortality.

I believe a single rib resection and a flexible drainage tube is the best, most effective and satisfactory method of treatment. There are no medical specifics for this condition.

I have had no experience with the vacuum-suction method of draining the pleural cavity of pus. In no case was it necessary to do a multiple costectomy. The lung seemed easily inflated and commenced to expand as soon as the compression was relieved by evacuating the fluid. This process was encouraged and accentuated by forced inspiratory efforts. In all cases aspiration should be used to relieve the compression of the lung and the embarrassed breathing due to the serous or pus accumulation until a more auspicious time for a radical operation. The more virulent the infection due to the hemolytic streptococcus, the greater the mortality with or without operation.

In the *Journal of the American Medical Association,* September 13, 1919, is an interesting editorial commenting on the treatment of empyema, which states that "the objections to simple thoracotomy were that it permitted collapse of the lung through the equalization of the air pressure within and without the pleural cavity, which collapse occasionally became permanent, necessitating secondary operations of doubtful prognosis for the relief of the condition." This statement is not in accord with facts. The lung is in a state of collapse from compression by the effused serum, or pus, sometime before the patient reaches the operating table. The operation, therefore, by the admission of air does not cause the collapse; in nearly every case the empyema was diffuse. No secondary operation is usually required if the primary operation is well done and not delayed so long as to permit permanent adhesions.

The Thiersch method of drainage with a soft-rubber catheter inserted between the ribs, through a trocar and working automatically, does not appeal to me as an effective surgical procedure. Furthermore, no small tube would drain the floating exudate or inspissated pus. In my opinion, resection of a rib in the most dependent part and drainage with a rubber tube the size of the finger is the only method so far produced that is worthy of a permanent place in the surgical treatment of the disease.

The admission of air to the pleural cavity during operation is not a serious matter as the lung is already, in diffuse empyema, in a state of collapse; neither have I observed any distress during subsequent irrigation of the cavity. In two cases with bronchial fistulæ it was advisable to raise the head and shoulders during the irrigation to prevent the liquid entering the bronchial tubes. These two cases recovered perfectly.

The outer wound heals much faster than the infected cavity behind it and it is necessary to retain the drainage-tube until the cavity is sterile and lung expansion has practically or nearly closed it. No secondary operation is needed to close the wound of entrance, as it heals in a short time after removal of the tube. If the cavity is sterile, the small quantity of air inclosed will be absorbed. The Schede, Estlander, or DeLorme operation will seldom be required. If the primary operation is not too long delayed, the expansion of the lung will obliterate the cavity.

Empyema is not cured by aspiration nor by the immediate closure of the wound after operation. It is recognized that in the influenzal and pneumonia epidemics the virulence of the infection is more intense and varied and the mortality, in consequence, greater under any treatment than we have been accustomed to experience in sporadic cases under ordinary conditions of civil life.

DISCUSSION

Dr. J. R. Hollowbush (Rock Island, Ill.): During my service in the late war I had occasion to see a great many cases of empyema. In the first epidemic which occurred at Base Hospital, Camp Sherman, we had 500 cases of measles in two weeks, many of which were followed by the streptococcic form of empyema. The intensity of this infection in a great many cases caused death in from sixty to seventy-two hours. The empyema was simply an expression of a general streptococcemia. Autopsies in these cases showed not only the pleural cavity full of pus, but in many instances the peritonial cavity contained a large quantity of free pus, and the pericardium also contained pus. It was difficult to understand how the heart could functionate with this great quantity of pus in the pericardium.

As to the treatment of the streptococcic form of empyema as developed in the late war, I will say, in passing, that this form of empyema had never been known before in the history of the profession, as was shown in the epidemics that

occurred in the various cantonments throughout the country. I am firmly opposed to any treatment of streptococcic empyema that does not allow a free exploration of the pleural cavity. In empyema following lobar pneumonia, principally in children, there is no tendency to sacculation whatever; while in the streptococcic form of empyema sacculation occurs very early, and, unless the adhesions are broken up, you cannot cure the patient. In a number of these cases at Camp Sherman we made an incision under a wheal of novocain, 1 to 400, to relieve the dyspnea, which was so marked. It was not intended as a curative measure, but to tide the patient over until some future time. Later on, where the patients were in good condition, we resorted to large resection of the ribs. I do not believe in taking out two and a half inches of the ribs, but a long section of two ribs so the fingers can be introduced to explore the pleural cavity. In our earlier cases, where we only resected a small portion of the rib, a large amount of pus would be evacuated, and we thought the patients were doing all right, but the septic condition continued, and the hyperpyrexia showed the patients were not doing well, and we resorted to a secondary operation, resecting larger portions of the rib and found sacs of pus that were not evacuated at the primary operation. Later on, when we did a much larger resection of the rib, we found it added very little to the shock, and we were able to explore the pleural cavity and to feel sure that we had separated all adhesions.

As to the treatment outlined by Dr. Grant: I have had no experience with it. We used the Carrel-Dakin solution in all cases. Fresh Carrel-Dakin solution was prepared daily. The solution and its strength, 4.5 to 5, produced no irritation whatever. We made these large incisions, sewed up the skin to a certain extent, and introduced from four to five of the Carrel-Dakin tubes which are tied at the end with small incisions on the side. These tubes were fastened by adhesive tapes, and, as you know, these small tubes come down to a glass receptacle from which a tube leads to a container which is hung at the bed. Instruction was given to the nurse to pool the cavity with the Carrel-Dakin solution every two hours and thoroughly lavage with solution twice in twenty-four hours. Every two hours they are pooled of about two ounces of fluid. It is estimated that the chlorine is eliminated in the course of two hours, and some claim in less time. A bacteriological count was made of the discharge every twenty-four hours, and it

was astonishing to see how the micro-organisms diminish from day to day, from countless numbers, until we arrived at the point that we had only two or three micro-organisms in twenty-four fields. The tubes were then taken out and the wounds allowed to heal. A great many secondary operations are performed, because the tubes are taken out too early and pus has re-accumulated. In only one case did we use Beck's paste. We had a sinus that would not close after a secondary operation. We injected Beck's paste and found a cavity in the lung which, when filled with the paste, was cured entirely. I kept track of this man for five or six months, and he remained entirely well.

Dr. A. L. Blesh (Oklahoma City, Okla.): My experience with empyema up to the time of the war was that of a general surgeon doing general surgical work. I did not look upon empyema as a particularly serious affair. I looked upon it in the light that it had considerable morbidity when the operation was done late, when the ribs were raftered over an enormous cavity the floor of which was composed of compressed lung. This was late surgery, and these were cases of pneumococcic empyema. The first cases coming to us at Fort Sam Houston, out of a total of about 400, were typical of pneumococcic infection. Many of these in the early part of the epidemic had practically the conditions met with in civil practice. We soon forestalled morbidity by early diagnoses and operation in this type of cases with better results. Correspondingly, about this time, or a little later, came the epidemic of the streptococcus hemolyticus with which few of us were familiar. We knew nothing about the clinical course of the streptococcus hemolyticus, which the essayist has described. The streptococcic form of the disease caused adhesions to form early. These adhesions amount to fusion of tissue. There will not be a line of demarcation in streptococcic adhesions of any kind, whether in the pelvis or anywhere else. The process is so active that actual fusion takes place, and multiple abscesses were the cause of death in practically all these cases. A few of the patients died within forty-eight hours of an acute septicemia; others died of the results of late septicemia and inadequate drainage.

Cases of pneumococcic empyema should be operated on early, as soon as infected fluid is demonstrable. In all streptococcic cases time should be allowed for adhesions to anchor the lung to the chest wall. It will occur in

from three to four days in most all of the cases. It will occur early. We shall not have to wait long, but, if we do not wait for this anchoring to take place, when we open the chest the lung collapses under fourteen pounds of atmospheric pressure, and we have an enormous cavity in which we have introduced infection, and the results are correspondingly bad.

The mortality in the streptococcic type runs between 25 and 30 per cent, including all cases, those dying very early of acute septicemia, those dying very late of late sepsis.

As to the type of operation: there is danger to be apprehended in the course pursued by the doctor just upon the floor, and that is this: if we are dealing with one cavity only and we can explore the pleural cavity and break down our protecting adhesions for which we have waited, we do exactly what we do with the early type of operation, we open the whole pleural cavity to the infection, which I did in one case, and that warned me thereafter to use the *x*-ray far more than we did before to demonstrate the number and locations of the cavities. The *x*-ray was used for that purpose invariably, and it not only showed us when but where to operate. We did practically all of our operations under local anesthesia, for the reason that we found ether was contra-indicated, gas less so, but under local anesthesia, if we could overcome the psychic apprehension of shock, we got the best results.

Dr. Arthur T. Mann (Minneapolis, Minn.): Our experience was a little different from that which has been related. We were in a base hospital with a camp of 33,000 men, and during a certain period we had 1,000 new cases of the flu a day. There were 2,500 cases of pneumonia, and how many cases of empyema there were I do not know; I have not the figures at hand. In the first place, there is a great difference between a pneumococcus pneumonia and a streptococcus pneumonia. A pneumococcus pneumonia, as a rule, is evident after the crisis in the lung. If we operate on a patient whose lungs have passed the crisis and are healing, it is safe to do almost anything that is right with those men. With a streptococcus empyema, we have a streptococcus pneumonia which scatters in spots, and the patient is under a heavy load of toxins and will not stand operative procedures like a pneumococcic patient will.

Our experience was something like this: In the first cases we gave a general anesthetic in one or two instances,

and local anesthetics in the others after that. Local anesthesia can be carried out perfectly if one knows how to give the anesthetic. Every one knows how to infiltrate the soft tissues, and they can catch the intercostal nerve, but the point which everyone does not catch is that of the periosteum, which is sensitive, so if the periosteum is anesthetized either before or after the incision is made, one has an anesthesia which can be painless all the way through without whiskey and other things. The needle should be pushed under the periosteum and a little of the novocaine and adrenalin, or whatever is used, put under the periosteum. The rest of it then is painless as well. The periosteum can be stripped and the rib resected without pain. The bones have no nerves of sensation.

However, after a very few cases we did not resect the ribs. We found that incision between the ribs was effective. The shorter the operation the less there was to heal up afterwards. We found that a better way after that was the puncture with a trocar and the insertion of the tube. The Mozingo method has many points of advantage and a great many points in its favor.

I want to say, first, in regard to the diagnosis, we must know there is fluid present. Our ambulatory *x*-ray outfit in the army was rather a small tube, a Coolidge tube, very carefully focused, and we were able to get *x*-ray pictures which in many cases could not be told from the *x*-ray pictures taken with larger tubes in the laboratory itself. The *x*-ray man was able to get pictures in which fluid of about 500 c.c., or between 200 and 500 c.c., showed before the clinician was able to demonstrate the fluid by the ordinary clinical means. We learned then to rely upon the *x*-ray pictures of our chests. The *x*-ray machine was taken to the bed, and a picture taken with the patient still in bed. No matter how sick a patient may be the *x*-ray picture can be taken. So much for diagnosis. We learned to rely upon the *x*-ray plate.

In the early cases we tried aspiration with the needle and syringe, and, if the fluid was serous and not purulent, that was the method of treatment which was continued to the end. In these serous cases we injected a small amount of the 2 per cent formalin and glycerine solution (Murphy's old solution), and it seems to help sterilize the cavity. We used the Carrel-Dakin solution, but the Murphy solution seemed to be a little better for that particular type of cases.

The Mozingo method was used very largely as a routine measure, which means a trocar through which a catheter (about No. 14 French) is introduced, the trocar withdrawn leaving the catheter in place, and a suction apparatus put on the end. That may be simply a glass syringe. You withdraw the syringe piston, clamp the tube, and empty the syringe. Then re-apply the syringe, open the clamp, and repeat as many times as is needed. A large cavity can be emptied in that way. An injection was made of Dakin's fluid at each treatment, and there were from two to eight treatments in every twenty-four hours. A smear was made of the fluid each day. Some of the cases will be sterile in ten days, while I have had them sterile in other cases in five or six days.

After the pus becomes sterile 20 to 60 c.c. of the formalin glycerine solution may be injected at the end of the treatment instead of the Dakin's fluid, or the Dakin's fluid may be continued to the end. After the cavity has remained sterile four days, the rubber tube may be withdrawn and the puncture wound sealed with a dressing. The majority of the cases will heal, and stay healed without further trouble. An occasional case will need further treatment.

Dr. Emil G. Beck (Chicago, Ill.): I should like to say a few words in reference to the treatment of these cases. I was a little surprised to notice that we should have returned again to any irrigation of the pleural cavity after we have discarded it for fifteen years, and, therefore, I do not resort to any irrigations whatsoever. I have used the old method of drainage of the chest by rubber tubes, such as were used in previous times, and I find that 19 out of 20 cases would clear up as usual. We have inserted two tubes, after resecting the eighth rib posteriorly, and, inserting the finger, have passed a large forceps to the front and made a counter-incision through that, passing a catheter back to the front, and using a larger tube over the catheter. The catheter is left in for four days, the large tube is extracted, and the catheter left in a week, and then replaced by a thin piece of tape saturated with 20 per cent argyrol. In those cases in which the opening would not close, we have used bismuth paste, and I am glad to say that nearly all of them have closed up, with few exceptions.

I had an opportunity to assist the surgeons at the Great Lakes Hospital, where I showed the method, though 350 cases were treated there. When the men lined up, it was

found that in 70 cases they had used the Carrel-Dakin method, then gradually dropped it and replaced it with bismuth paste, and with gratifying results. Their report is now ready to be published. They have good results without washing—just from drainage.

There will still remain a small group of cases that will not yield to any of these treatments, either washing or injections; and for those cases that have continued to suppurate for a year or more, I would recommend extensive resection of many ribs with the skin-sliding method, because I have seen gratifying results from it.

Dr. E. M. Sala (Rock Island, Ill.): In speaking about drainage tubes, I think much of our trouble in the treatment of empyema has been due to the kind of tube used. I believe if you use the Wilson empyema tube in the treatment of cases of empyema, you will find it the most serviceable, and after you have used it once I am sure you will not want to use anything else. You put it inside the chest, and the lung comes up flat against it every time the patient breathes. It is a positive drain. I am aware that a lot of pockets form, but when you get a Wilson drainage tube into one of the main pockets it will communicate with the others and drain it.

The first case I operated on at Camp Cody was a man who had been operated on four times before, and the only hole he had for drainage was a hole thro his rib which would not admit a lead pencil. The bone had regenerated around the tube and closed it over except around the drainage tube itself.

A great deal of our trouble in operations for empyema is due to regeneration of the rib or bone. I had three or four cases in which there was positive evidence of regeneration of bone which had closed the cavity.

I was not very favorably impressed with the Mozingo method after having watched it for two months at the Walter Reed Hospital. I believe resection of the ribs is the best treatment for cases of empyema, although there are cases in which opening the chest between the ribs is a good thing.

I have in mind a tube which has a double cannula and metal sheath to go down through it, which I think possibly would be very good in some of these cases where you want to go in between the ribs.

Before the war I assisted in a case of empyema in a woman who had been operated on by a doctor in Chicago. He had inserted an ordinary straight tube and turned the case over to a local physician, and in a week's time the tube came out, the sinus closed up, and she began to have a recurrence of the symptoms, so that it was thought possibly she might have an abscess of the kidney. This physician came to Rock Island to operate again, and I asked him if he had ever used one of these tubes. He said he had not, but thought it was a good thing. He used it on this woman, and she got well without any trouble. You can leave it in almost indefinitely.

When I was in Europe in 1911 a doctor left one of these tubes in five months until I came back, and it caused no trouble.

I do not think there is any question but what the Wilson empyema tube will be the tube you will all use in time. You do not have trouble in changing dressings. Patients do not complain about it. In one case where a straight tube was used and lost, and thought to be in the patient's chest, it was learned later that it dropped on the floor and a boy swept it up. Another boy who was operated on in Liverpool Base Hospital had a piece of rubber dam which remained in his chest, and I removed it one year later. These accidents do not happen with a Wilson tube.

Dr. D. P. Mayhew (Colorado Springs, Colo.): I have had the opportunity of seeing at General Hospital No. 12 the results of a great many different types of operation for empyema, and we had the opportunity of coming to some conclusion as to the best method of taking care of the later cases, at least.

The consensus of opinion expressed by the Empyema Commission, who made very frequent visits, was to the effect that the best treatment of these cases in the early stage was drainage, ample drainage, through an opening, preferably made in the eighth interspace or through the eighth rib in the posterior axillary line or scapular line, with the immediate beginning of Dakin's irrigation. Cases that had been treated in that way came to us less frequently for further treatment than did those treated in other ways.

The method of final closure which we worked out was the Dakinization of these cavities—I mean real Dakinization, not the daily instillation of single doses of Dakin's solution, but

the flushing of the cavity. If this be done the cavities will be sterilized unless we have one of three conditions present. Possibly to these may be added a fourth condition. The three conditions are a necrotic rib, foreign bodies (of which we found a considerable number left by previous operators), and side pockets which opened into the main pocket, into which the Dakin solution could not be instilled. In the absence of these three conditions, to which bronchial fistula may be added as a fourth, sterilization of the cavity was comparatively rapid. Checks were made by plate cultures every other day. When we finally got sterilization, especially with reference to the hemolytic streptococcus, all tubes were taken out and the wound allowed to close. A single streptococcus on the plate is a contra-indication. A few other organisms, such as staphylococci, is not a contra-indication. The tubes once taken out, the cavity having been sterilized, the sinus will promptly close. These sinuses will close even in the presence of a cavity of 200 to 500 c.c. Once closed, the air in that cavity is absorbed, and following these cases by the *x*-ray we can see from week to week a diminution in the size of the cavity until finally it is obliterated.

I was interested to hear Dr. Mann speak of the method of early treatment by trocar and tube. Apropos of that, one of the members of the Empyema Commission, speaking to us about it, said, "The method is a nice one; it is very convenient for both surgeon and for patient, but it has one serious objection, namely, it does not cure the patient." Furthermore, he said he had had an opportunity recently of examining 67 patients who had come up for discharge as cured, and he had been able to find pus in 66 of them. There is no doubt in my mind that the Dakin solution, if used intelligently and used as it should be frequently,—every hour by preference, but never less than once in two hours,—is an efficient method. It is the method of choice in these cases especially. I know it is a method of choice in the later cases, and I am inclined to the opinion that it is the method of choice in early cases of hemolytic streptococcus infection. I am not so sure about the other forms of infection. We saw cases treated in every conceivable way, and likewise mistreated in every conceivable way.

Dr. Grant (closing): I would like someone to explain to me how in a large pleural pus cavity it is possible to apply Dakin's solution through the small catheters. It is utterly impossible to do so. You may put a dozen tubes into this

cavity, but with the patient usually in the reclining position you will find these tubes are worthless. They drain nothing. The Dakin solution, in order to be most effective, must be constantly in contact with every diseased part for two or three hours at a time, and that is the way it was used in flushing wounds in the war zone. Most of the stuff called Dakin's solution was not Dakin's solution at all, so that my confidence was shaken in regard to its use, and I was not thoroughly convinced it was the only thing to be used; in fact, in a series of 31 cases in which it was not used the results were as good as any reported. Results are what count. Furthermore, if I have to depend upon the *x*-ray to tell me what lung was diseased, what pleural cavity was filled with pus, I should think I was not a competent surgeon. I did not need it to inform me when to operate or where to operate, except in a few isolated cases of lung abscess, in which as a precaution I would use the *x*-ray. With an aspirating needle physicians were instructed by me not to hesitate to use it at any time to determine the character of the fluid and whether the chest cavity was filling up or not. I never saw any unfavorable results from that measure. The patients did not require a local anesthetic; it was like giving a hypodermic injection. With the Leur syringe and the clinical history and physical examination you can quickly determine what to do and where to operate.

With reference to the question of old adhesions, bronchial fistula, and so forth: I had two cases of fistula which I included among those that recovered. I did not know they had bronchial fistula until the chest cavity was filled with irrigating solution, and the men would cough and expectorate some of it through the tubes: in the semirecumbent position the flushing was continued afterwards without any serious trouble until the fistulæ closed and convalescence established.

There is one other point I want to allude to, and that is decortication. I did that at the time of operation in every case that required it. In civil life they are sent to us sometimes weeks after the acute stage is passed. In those conditions where we found a compressed lung with old adhesions formed around it, the operation of decortication was employed. I never re-operated by rib resection in a single case. There was no necrosis, and I did not find it necessary to make a counter-incision anywhere; most of them were large pus cavities and they healed gradually. In fact, after making resection of the rib I had no trouble in inserting two fingers.

If you cut the tube off smooth with the skin and hold it with safety-pins and apply a compress properly, no air can be drawn in during the respiratory process. In deep inspiration the fluid is forced out, and during expiration air will not be sucked in. These patients are comfortable and with a stethoscope you could tell that the lung was rapidly expanding and resuming its normal function.

I feel that even the limited number of cases I had taught me something of value. I did not have always the benefit of the pathologist or bacteriologist. Otherwise I made use of my clinical knowledge and experience. I did not use the *x*-ray often in these cases. I think it safer and easier to use an aspirating needle at the bedside rather than carry the patient from one building outside into the *x*-ray room to get an *x*-ray picture, which would tell me what I already knew.

OPERATIVE RESULTS IN TWO HUNDRED BREAST TUMORS

Byron B. Davis, M.D.

OMAHA, NEBRASKA

My private records of operations for growths of the breast contain the histories of 166 persons suffering from malignant tumors and 44 from benign. In this series no cases have been included that were operated on during the last three years, and the records cover my private work from 1898 to December, 1916. The records of many other cases operated on are inaccessible or so incomplete as to be valueless. The cases included have practically all of them been verified by the microscope in the hands of a trained pathologist.

Of the 166 cases of malignant disease that an effort has been made to trace there was one operative death, the remaining 165 having left the hospital apparently in good condition. One hundred and sixty-five were diagnosed as carcinoma, and only one sarcoma was found. All but one occurred in women.

My letters were sent to the husband, son, daughter, or physician, and not to the patient, as it was felt that this method would most likely bring answers in the event that the patient had died. To the 165 letters sent out answers have been received thus far from 101. Up to the present, 64 have failed to answer and these cannot be used for statistical purposes.

Of the 101 answers received, 63 reported the patients free of the disease for periods ranging from three to about 21 years. Of the 38 remaining, 36 have died of local or disseminated cancer, and 2 yet living are suffering from recurrence. Three or 4 reported

dead were not considered by their relatives to have died of cancer; 1 was called "creeping paralysis," 1 "from a stroke," etc.; but these were obviously deaths from cancer, and are so included.

This gives us, then, the rather encouraging result of a little better than 62 per cent of the cases free of recurrence from three to twenty years. I refrain from using the word "cured" in this connection, for there have been a number of cases that have remained free of any evidence of the disease from five to nine and one-half years and have then recurred and died of the disease, and there is little doubt that some of the cases reported free of all trouble now will later succumb to the disease. For this reason it is freely conceded that 62 per cent is not a fair estimate of cures obtained. It is also only fair to presume that among the 64 not heard from the proportion of deaths is larger, for it is only natural that the friends of the living would be more likely to answer the questions propounded than the friends of the dead.

Allowing for all sources of error we have 63 very favorable results, and this means a good many years of life and health, and, it is hoped, happiness in the aggregate.

Under benign diseases of the breast there have been included 44 cases. Two cases that were considered benign at the first opertion later appeared with carcinoma and underwent the radical operation. Whether the diagnosis first made was erroneous or the malignancy was of later development it is impossible to say. Forty of the benign cases were in females and 4 in males. Under the caption adenoma, fibro-adenoma, and cystadenoma there were 37, and 1 with mastitis complicated with adenomata. In 3 of these cases both breasts were involved, and the tumors were excised from both. In 2 cases after the adenoma had been

excised from one breast it appeared in the other and was excised, and in 1 case a second adenoma was later excised from the same breast.

The treatment of the adenomata in females was simply excision, usually through an incision along the thoracomammary junction, the breast being turned up and the tumor removed from underneath. In 2 cases of multiple fibro-adenoma the disease was so extensive that simple amputation of the breast was done, and in 2 other cases before I made a regular practice of having frozen section made immediately in all doubtful cases, I did the radical operation under the impression that it was carcinoma. Later these two cases were shown microscopically to be benign, and are so counted. In each of the four male cases the breast was amputated.

In the cases mentioned of mastitis complicated by multiple adenomata the breast was amputated, as was also done in three cases of generalized chronic mastitis. There were also 2 cases of lipoma that were simply enucleated and 1 case of mammary tuberculosis in which the breast was removed.

The average age of those having benign growths was thirty-four years, while the average age of those suffering from carcinoma was forty-seven and one-half years. The surprisingly large number of women with carcinoma between the ages of thirty-five and forty-five and the small number past sixty brought the average below that usually given.

For some time I have been under the impression that the propaganda being carried on by the "Society for the Control of Cancer" and by the medical profession generally is bringing women with cancer of the breast to the surgeon much earlier than formerly. From this standpoint my statistics are truly disheartening. The time the growth was first noted is given

in almost all the histories. The average time between the discovery of the "lump" and the day of the operation in those operated on before 1910 was one year, three months, eight days, while those operated on during the years 1910 to 1916 were aware of the growth one year, five months, eight days before the operation, a difference in favor of the earlier group of exactly two months. A partial explanation of this apparent lack of progress is, that in the 1910 to 1916 period are included two women with tumors of thirty and fourteen years' standing, respectively. Leaving these two cases out of consideration it would bring the average duration of the later period down to a little below that of the earlier. Statistics are peculiar things.

It is also found that the average time between the discovery of the "lump" and the operation of those that died of recurrence is practically the same as of those that have remained free of the disease. These apparently contradictory figures should not lessen our determination to operate as early as possible in every case. The discovery of the "lump" is in most cases purely accidental, and it bears little relation to the beginning of the disease. Every surgeon frequently operates on tumors only recently discovered that show advancement and must have been well started months before the date of discovery. It is evident that in most cases carcinoma of the breast antedates its discovery weeks and months and sometimes years.

There was one operative death, Mrs. N., of Valentine, Neb., aged seventy years, referred by Dr. Alfred Lewis. She had carcinoma of the right breast, well advanced and of five years' duration. Her condition seemed satisfactory, and the usual radical operation was done October 23, 1912. She died October 25 of suppression of urine.

Another case was a tragedy. Mrs. R., aged sixty-one years, had carcinoma of the right breast with

great axillary involvement. She was operated on June 21, 1910. In dissecting some adherent glands from the axillary artery the artery was punctured. The wound was sutured as carefully as possible, but at the close of the operation no radial pulse could be felt. The arm was wrapped in cotton and kept as warm as practicable, but gangrene of the forearm occurred, and July 6 the arm was amputated at the junction of the middle with the lower third. She recovered nicely from the operations, but died of recurrence of the cancer eleven months later.

For the past eight years it has been the regular procedure to have a pathologist present in all doubtful cases, who makes a frozen section of the removed tumor. In from three to eight minutes he is able to make a fairly thorough study of some sections. If he finds a definite picture of malignancy the radical operation is done at once; if he fails to discover malignancy the little wound is closed. This combination of the macroscopic study of the growth and the microscopic examination is fairly free from error, but not as certain as a careful laboratory study of the case made at leisure. To combat this source of error the tumor is taken to the laboratory later and prepared in the usual way, and many sections are studied. In two cases of this series that appeared benign at the hasty frozen-section examination, malignant areas were discovered later, and radical operation was done.

In this series are many cases that have had local recurrences, which have been removed by later operations. It is fair to state that most of the cases requiring secondary operations have subsequently died of the disease, but this has not been true of all of them. Even if all of this class had finally died operations for local recurrences prolong life and keep the patient hopeful. Several with one or more recurrences that were promptly removed are still alive and well and free of

any evidence of disease a number of years after their last operation. As an example of what may be done: Mrs. R., aged forty-six years, was operated on for a carcinoma of the right breast of four years' duration November 22, 1909. A nodule appeared in the scar and was removed by a wide dissection July 28, 1910. Still another recurrence along the line of the scar was removed April 1, 1911, about eighteen months after the first operation. She came to my office a few months later, and the scar was nice and smooth and gave no sign of any active process. About this time she moved to Chicago. On October 19, 1919, a letter from her husband stated that she is alive and well and had had no further evidence of the disease since her last operation, eight and one-half years before.

Cases of this kind give one courage to persist in removing these local recurrences when the outlook is darkest. One should make as great an effort to get rid of a recurrence radically as if he were dealing with the primary disease.

Among the 166 cases in this series one woman presented herself with carcinoma of both breasts that had developed simultaneously. Radical operation was done on both sides February 22, 1904. She was alive and well and free of recurrence a year ago, the last time I have heard from her.

In the series were seven patients operated on for carcinoma of one breast who subsequently returned with carcinoma of the other, for which radical operation was also done. Five of them died subsequently of cancer and two are alive and well six and one-half and seven and one-half years, respectively, after the second breast was removed. When a carcinoma permeates the lymphatics inward to the sternum it may be carried by the anastomosing lymphatics across the front of the sternum to the opposite breast and axil-

lary glands, and really when the permeation pursues this course it is not of much graver significance than to be carried to the lymphatic glands on the side in which it originates.

The youngest case in the series was a girl only eighteen years old. Only a few days before she appeared for an operation a "lump" was discovered in the left breast. It was almost "woodeny" in feel and had all the clinical characteristics of a typical carcinoma. A frozen section from the tumor, removed June 8, 1916, was pronounced by Doctor Manning to be carcinoma, and the radical operation was done. The later study of numerous sections confirmed this diagnosis. It was clinically, macroscopically, and microscopically an adenocarcinoma. This girl has been lost sight of.

There was in the series one case of sarcoma operated on October 16, 1916. Two local recurrences were removed the first six months after the radical operation. A letter from the husband, written October 25, 1919, states that she is in the best of health, and there is no sign of the disease.

Most of the cases operated on during the past ten years have received *x*-ray treatment. I am not able to make any positive assertions concerning its effects. About all I can say is that it seems a mildly palliative measure, and should be used vigorously after every operation for mammary carcinoma.

A few years ago it seemed that the ultimate had been reached in the surgical management of carcinoma of the breast. The ideas promulgated by Handley have produced some modifications that promise to lower the final death-rate still more. Formerly about all we had in mind was to remove the breast, the pectoral muscles, and fascia widely, and to clean out the axilla with the feeling that the avenue of dissemination outside of infiltration and metastasis was *via* the lym-

phatics leading to the axilla. Sometimes the enemy would make a counter attack on the mediastinum, the lungs, the liver, or some other vulnerable point for which the surgeon did not blame himself because he considered these attacks embolic and involvement of these regions meant metastasis *via* the circulation.

It seems that Handley's views that the chief method for the dissemination of cancer is by the cells growing along the lymphatic vessel lumina, and that they can as readily grow downward and penetrate the abdominal wall in the epigastric angle and reach the liver or the peritoneal cavity, or by growing along the lines of communication towards the sternum and passing backward in the lymphatics that accompany the internal mammary vessels to the mediastinal space, or by growing along the anastomosing lymphatics from the opposite side may reach the other breast, are correct. Still other routes may be chosen. Knowing the lines of most active permeation will naturally influence the form of operation.

The removal of large areas of skin as formerly practiced does not now seem necessary. Most recurrences in the skin have been shown to be extension of the process upward from the very dangerous fascia. Any tissue that is abundant in lymphatics is a menace, because the lymphatics have been shown to be the most travelled routes by which cancer is disseminated. Hence the most extensive removal of deep fascia and muscles not only extending to the axilla with the removal of its fat and glands, but extending upward past the border of the sternum and downward to the epigastric region, in order to cut off the different lines of advance of the cancer cell, is the logical procedure.

To have a set form of incision I am satisfied is a mistake. The location and extent should determine the line of incision and the amount of skin to be removed.

If the growth is deeply seated only a comparatively small amount of skin need be sacrificed. If near the surface, and especially if the skin is adherent, a much larger area should be removed.

The most methodical part of the operation, as well as the more extensive, occurs beneath the skin. There is really no especial limitation to the amount of fascia and fat that may advantageously be sacrificed. In the fascia one may be reasonably certain that there is microscopic invasion much farther than is macroscopically apparent.

Volkmann's three-year period of freedom from recurrence does not constitute a cure of cancer. Neither does a five-year period. A number in this series were free from recurrence more than five years, but later died of cancer. The longest period noted in any of them was a woman, operated on October 31, 1904, at the age of sixty-eight. She was apparently free of all trouble until early in 1914, about nine and one-half years after her operation, and she died of the disease in December, 1918, more than fourteen years after her operation. I examined this woman several times, and learned that the recurrence came in the form of nodules over the chest wall, formerly occupied by the breast, and was a typical local recurrence and not a carcinoma originating as a primary growth. At least, that is the way it appeared to me.

In conclusion, my study of these cases and the results obtained are encouraging rather than discouraging. Operation for cancer saves lives. The very early operation, so early that the microscope is necessary to make the diagnosis, is bound to produce better results than the operation done after the disease is easily diagnosed. The radical operation should be directed in such a way as to remove, as thoroughly as possible, the highways along which the disease is disseminated.

The campaign of education of the public with reference to the signs of early cancer and its curability when operated on early should be continued and kept up unceasingly. And finally the fact should be appreciated that every woman operated on for carcinoma of the breast who remains free of the disease, is more powerful propaganda in the community in which she lives than all the tracts that can be written.

DISCUSSION

Dr. Roland Hill (St. Louis, Mo.): There is one thing I would like to have seen brought out in Dr. Davis' paper, and that is the question of the change of small tumors that are primarily benign into growths that are malignant. First of all, we know that in some of these tumors to start with we get a thickening of the epithelium; and finally breaking through as they develop into true carcinomatous tissue. In cases of cyst adenoma we find a papillary ingrowth that will go on and ultimately develop into cancer.

The proportion of primarily benign tumors that become malignant is very great, and too much emphasis cannot be laid upon the necessity of removing every burst tumor, no matter how simple it may appear.

Dr. Thomas S. Cullen (Baltimore, Md.): I greatly enjoyed Dr. Davis' paper, and I think the method advocated by Dr. Beck in his paper will probably enable us to help many supposedly inoperable cases of cancer.

Dr. Davis dwelt especially on the education of the public as to what may be accomplished where cancer is operated upon early. About seven years ago I was going over my cancer statistics and was greatly disheartened by the large number of failures we had had. We had gone about as far as we could with operations, but we were not getting the cases early enough. I happened to be writing Dr. Franklin H. Martin that day and incidentally mentioned how disheartened I was. He suggested a campaign of education, and a few weeks later at the meeting of the Clinical Congress of Surgeons held in New York, a committee was appointed. This committee was instructed to write, or to have written, articles on cancer, and was further instructed to have these published in the daily newspapers and the weekly or monthly

magazines as might be deemed most expedient. Our committee was most fortunate in enlisting the co-operation of Samuel Hopkins Adams, who tackled the subject with his characteristic thoroughness. He wrote several articles, the most extensive one filling two full pages in the *Ladies' Home Journal.* A few weeks after this article was published I happened to meet Dr. LeGrand Guerry, of Columbia, S. C., on his way to Chicago, and he said that as the result of the *Ladies' Home Journal* article alone he had seen six early cases of cancer in a few weeks. At a later date the A. M. A. appointed a committee on cancer, and we were able to accomplish a good deal through the Council on Medical Education of the A. M. A.

The cancer educational propaganda has now outgrown any single committee, and all our energies are centered in the Society for the Control of Cancer, which has been particularly fortunate in securing Dr. C. A. Powers as its president. Do all you can to co-operate with this society. I urge upon you the education of the public at every opportunity. Do not hesitate to use the magazines to drive this question home, in season and out of season, for this is the surest way to get the early cases of cancer of the breast, of the lip, or of the pelvic structures.

Dr. Samuel C. Plummer (Chicago, Ill.): I have often thought I was able clinically to distinguish between a malignant and a non-malignant growth of the breast in the large majority of cases, but we all know there are still a large number of cases left where it seems impossible to make that differentiation.

Recently I had a case in which I discovered a small, smooth nodule in the breast, freely movable in the breast substance, which I thought was benignant, but it turned out to be malignant. I have adopted the plan of removing these tumors with the pathologist present with his freezing microtome. I take out the tumor widely so as to get it all out in case it is benignant, and no further operation is going to be necessary, and with the view, if possible, of getting outside of any extension of the growth in case it is malignant. As a rule, as soon as the growth is taken out and handed over to the pathologist, and he makes a cross section through it, you know at once without waiting for the microscopic report whether the tumor is benignant or not. It is so plain you do not wait for a frozen section. We make a frozen section anyway, and later that is confirmed by an examination of the hardened specimen which takes a few days.

A few years ago Dr. Bloodgood, of Baltimore, said that, in cases of doubt as to the nature of a tumor of the breast, always do the radical operation. I have followed that advice, and I know in two cases I have done a radical operation for a benign growth. That seems rather too bad. Now I am much more conservative, in that I remove the growth and find out by consultation with the pathologist and the use of the freezing microtome whether it is malignant or not, and close up the little wound or do a radical operation in accordance with what is found. Formerly, it was considered proper to remove the growth, and have it examined in the regular way in the laboratory, which took four days or so to get a report, and then operating for the removal of the tumor in its entirety later in case it was malignant; in the meantime, however, there was dissemination of the growth as a result of the operative interference, and there was a delay of a number of days before a radical operation was done. I would like to know whether there is any danger in disseminating the growth by following the idea Dr. Davis speaks of with reference to taking out the growth and proceeding at once with the radical operation in case the disease is found malignant.

Dr. W. D. Haines (Cincinnati, Ohio): We may say in a general way that 80 per cent of all breast tumors are malignant, that 10 per cent of the cases are potentially malignant, and that 10 per cent of the breast tumors are benign.

Table diagnosis is the ideal method to determine the nature and extent of neoplasms of the breast in patients who apply early for examination. I advocated the method before this association a number of years ago, and I follow this plan in practice when circumstances will permit.

The probability of disseminating the cancer infection to other portions of the breast during the table examination may be reduced to a negligible risk by removing breast tissue some distance beyond the limitations of the growth.

In order to reduce error to a minimum in the microscopic diagnosis we request the pathologist to examine three sections taken from different areas of the tumor. If the report is "Suspicious" or "Doubtful" we do not hesitate to classify the case as borderline, and proceed with the operation.

For the past ten years we have been referring all of our cancer cases for *x*-ray treatment as soon as the skin is firmly united, with instructions to continue the treatment as long as

the radiographer deems expedient. This plan has materially improved our statistics, in that the percentage of three, five, and ten years' freedom from continuation of the disease after operation is increasing. Continuation of the malignant process, however, in a large percentage of the patients despite improved methods of treatment would be very discouraging but for the fact that a greater number of cancer cases is being reported as cured each year. This should encourage us to continue the present plan of treatment until the future shall discover the cause and cure of cancer.

Public propaganda instituted some few years ago has borne fruit in that patients are consulting the doctor earlier, and many of the patients are being referred for operation at a time when operation offers most for relief. But our statistics following operation for cancer have not fully convinced the family physician. He wants to be shown, and he must be shown.

It is difficult for the public to judge of the relative merits of the blatant claims of the quack and the cancer propaganda of the altruistic profession when they appear side by side as they sometimes do in our daily papers.

We must send out patients who have been successfully operated on as walking advertisements in order to fully convince the public and induce other patients suffering from the disease to consult a surgeon at a time when operation offers most for the welfare of the sufferer.

Dr. Arnold Schwyzer (St. Paul, Minn.): We have seen patients with carcinoma of the breast that did not do well after operation where we felt we had hastened the end by operation.

The work of Peterson and Colmers years ago on carcinoma of the rectum was exceedingly interesting to me. They found in a surprisingly large percentage of cases that there were small microscopic emboli of isolated carcinoma cells in the lungs. Still secondary carcinoma of the lungs is a comparatively rare complication, and it is only very late in the course of carcinoma of the rectum that metastases in the lungs are seen. Therefore, the conclusion was that a large number of these carcinoma cells, especially when they are isolated, are taken care of by the tissues. It occurred to me, as long as we are liable to cut infected lymph-vessels at the operation, and thus may soil the wound during operation, no matter how careful we are, that by *x*-ray we could

energetically stun these carcinoma cells before the operation and, therefore, before dissemination. Thus the tissues could better take care of them. So, years ago I started to give massive doses of *x*-ray the day before the operation. We heard this afternoon how much influence the rays have on carcinoma, and if we give well-screened intensive doses which can be given in one day, at a half or one hour sitting, I feel we have materially helped the patient that his tissues may take care of the cancer cells which happen to become accidentally implanted in the wound. I feel quite sure since I use this precaution that results have been better.

After using this pre-operative röntgenization for several years I was gratified in reading that Professor Wilms, of Heidelberg, had made the same observation. He gave massive doses of *x*-ray before operation and stated he had materially improved his end-results.

Dr. Davis (closing): I am very much gratified with the discussion. I did not expect to bring forward anything especially new, but I think it is one of the subjects that should be emphasized every once in awhile.

As to the question brought up by Dr. Plummer in regard to whether there is any risk in cutting out the tumor in order do with the future appearance of carcinoma, is undoubtedly true. These adenomata are all potentially carcinoma, and a number of cases that I have gotten early were simply adenoma, and the first picture looked as if it was adenoma and nothing else, and carcinoma was found in some portion of the growth. In the two instances where they did not discover any carcinoma at the time of operation, but did later in the laboratory, both had evidently simple adenomas to begin with, malignancy occurring later on.

The question brought up by Dr. Plummer in regard to whether there is any risk in cutting out the tumor in order to have a frozen section done or not, we all concede that, as Dr. Bloodgood brought out several years ago, to take out a piece of the growth and then wait three or four days until we have a section examined, and then operate, is decreasing the patient's chances by a great many per cent; but in those cases where we do the operation immediately I do not think the risk is very great. I think that every time the knife goes through cancerous tissue you are taking a little chance of allowing some dissemination, and for this reason we should always be careful in our operations when we do the radical operation, to go outside the field. If we should cut into tis-

sue that is suspicious, our instrument should be cast aside, and we should get another freshly sterilized instrument on account of the possibility of engrafting the growth on healthy tissue.

I was interested in what Dr. Cullen said in regard to the Society for the Control of Cancer. I have taken an interest in that society ever since it started, and it is doing good work, and I have one particular example to mention where it did mighty good work.

One morning, three or four years ago, my telephone rang just as I was dressing. It was early in the morning. I went to the phone, and a lady said, "This is Mrs. So-and-so. When can I see you at the office?" I replied, "I may not be at the office this forenoon, but will be there at three o'clock." She said, "I will be there." At three o'clock she was at my office waiting. She said she had a little lump in her breast and wanted me to examine it. She stripped, and I examined the lump. It looked suspicious, and I told her so. I said, "When did you discover this?" She replied: "Doctor, as near as I can tell, forty-five seconds before I rang the phone this morning I discovered it accidentally." She went to the hospital that afternoon, was operated on the next morning, and the little growth proved to be carcinoma. She is still alive and apparently perfectly well. There is one case where the propaganda did some good.

At the present time, aside from the radical operation, and what we can accomplish with radium and the *x*-ray, there is nothing that will do any special good in these cases, consequently until some definite method of procedure is established, everything we can hope for in the way of improvement in our statistics, and the number of cases we can save, is by propaganda and education of the general public to the fact that carcinoma in the beginning is purely a local disease, and if removed while local it will cure these patients, and give them some idea in regard to the things to look out for and be apprehensive about, and the first thing they should do is to consult a physician.

Another thing is to educate doctors to the idea that when they find a lump or growth that is suspicious, they should not dismiss the patient for one minute until it is absolutely proven to be innocent.

OPERATION FOR ADVANCED CARCINOMA OF THE TONGUE OR FLOOR OF THE MOUTH

VILRAY PAPIN BLAIR, A.M., M.D., F.A.C.S.
ST. LOUIS, MISSOURI

Clinical observation has led me to believe that, in spite of their high mortality, the majority of carcinomata of the mucosa of the mouth and upper air passages are for some time after their appearance not very malignant, and the present high mortality rate is due chiefly to late or inefficient operation, or both. In spite of the reasonable hope that the time is not far distant when early recognition will render the simpler operations efficient for all but the more malignant growths, at present most of the cases that we are called to treat are so far advanced as to require the more radical operations, and many are not properly operable by any of the classic procedures. It was the cases of cancer of the tongue and floor of the mouth coming under the latter classification that led to a plan of operation that in its thoroughness may be compared to the "radical" operation for cancer of the breast. Unlike the latter, I do not believe it to be recommended for all cases of cancer of the tongue. Butlin's[1] analysis of his own results would lead one to believe that, with subsequent operation on the lymphatics, the Whitehead operation is suitable for many if not most cases. On the other hand, Lenthal Cheatle[2] concluded from his histological studies that extensive involvement of the associated muscles was the rule in the cases he examined, and therefore that the intrinsic and geniohyoglossus muslces should be removed in all cases.

It is my present belief that the operation to be described is properly applicable to the more advanced

cases, especially those that also involve the jaw, the floor of the mouth, or the base of the tongue, or those with palpable involvement of the submaxillary nodes, and to early cases where, after removal by a less radical procedure, examination reveals a high-grade malignancy. I believe that it has a lower death-rate than any of the operations that involve cutting through the jaw bone. It is easily and quickly done and gives

Fig. 1. Line of incisions from behind the angle of the jaw on one side to a corresponding point on the other crossing the midline at the lower border of the body of the hyoid bone.

speech results that compare favorably with partial removals, but, after total removal of the tongue, chewing is impossible and deglutition is very much impaired. It consists in the block removal of the tongue, the structures in the floor of the mouth, all muscles above the body of the hyoid bone and stylohyoid muscles, the submaxillary and submental lymph-nodes, and as much of the faucial pillars and pharynx as de-

sired, together with thorough cauterization of the mandible wherever the ulcer approaches or involves it.

The operation is performed as follows: Forced fluids are given for twenty-four hours before operation, and a low *bloodless* tracheotomy is done, perfer-

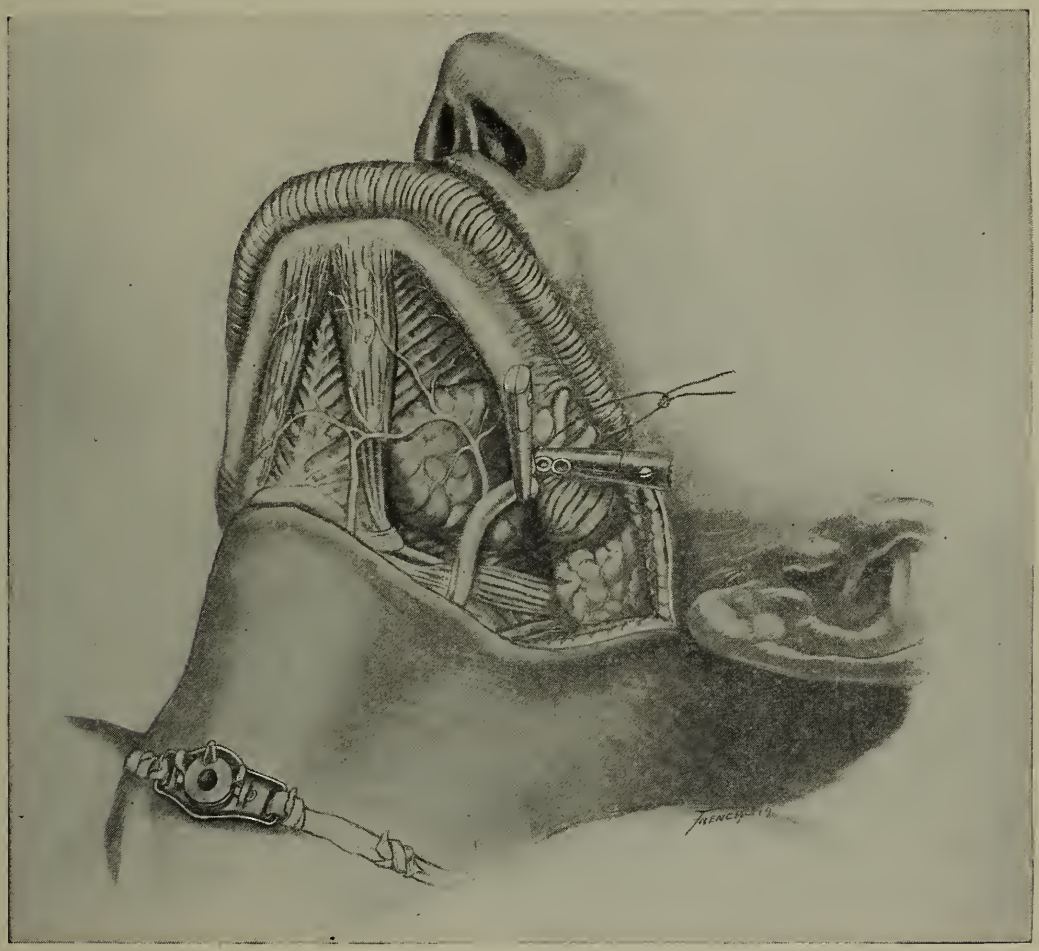

Fig. 2. This shows the skin platysma flap retracted upward and the facial artery and vein doubly caught and cut as they cross the lower jaw and ready to tie. In this figure and also in Figure 3, in order to identify them more easily, the muscles are shown stripped of their deep cervical fascia, but at operation they would be very much hidden by this fascia and usually by a deposit of fat.

ably under a local anesthetic; if a general anesthetic is given before the tracheal tube is inserted, septic material may be aspirated. I believe there are very certain advantages in having the tracheotomy precede the

main operation by a day or more. The tracheal tube should be large, (at least a No. 6) and long enough to reach well into the trachea; in a low tracheotomy the ordinary tube is not long enough except for very

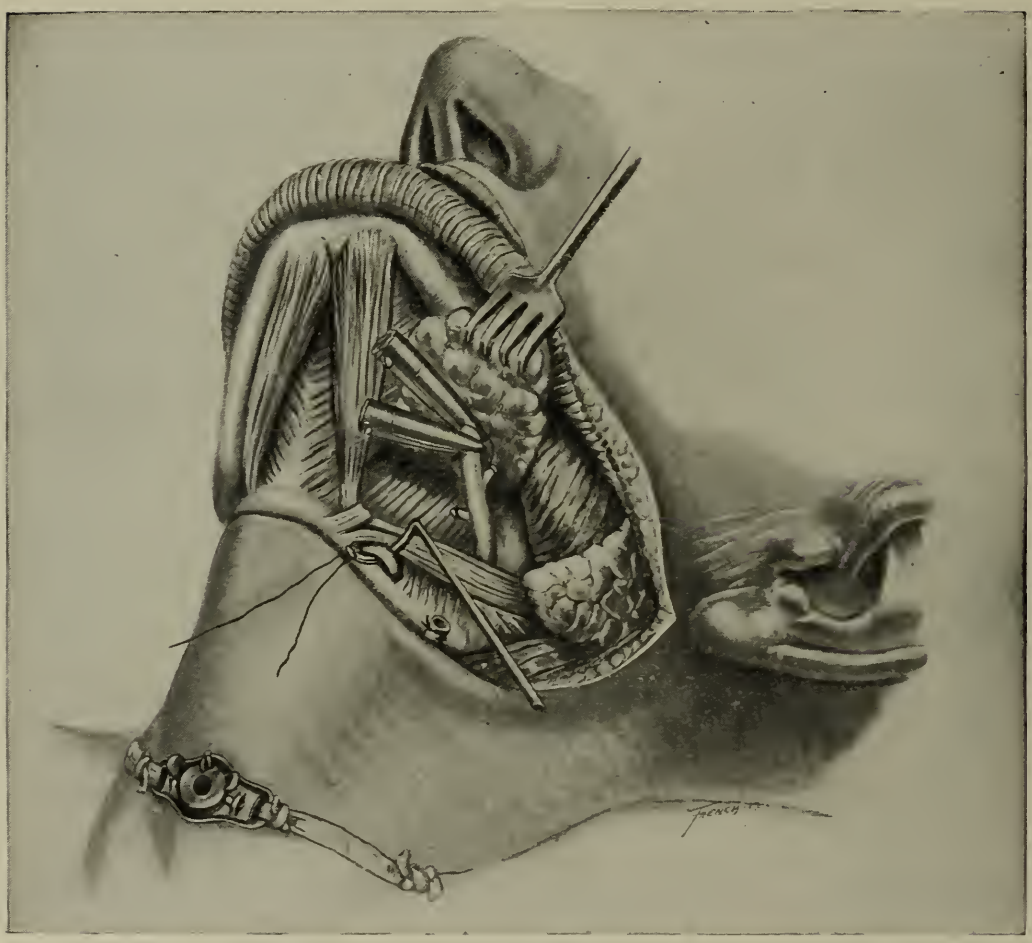

Fig. 3. Shows the submaxillary gland of the left side drawn forcefully upward and the facial artery caught and ready to be cut and ligated as it enters the gland. The lingual artery is shown drawn out through a separation between the fibers of the hyoglossus muscle ready for ligation.

thin individuals. No attempt is made to clean up the inside of the mouth before operation; a person in ordinary health has some immunity to the organisms he habitually carries but trauma may destroy this immunity.

The incision shown in Figure 1 skirts the lower border of the hyoid bone and goes just through the platysma muscle. With two sharp rake retractors, the skin and platysma above the incision are avulsed forcefully upward from the deep cervical fascia, cut-

Fig. 4. Shows the completed excision and the wound ready to close. Note that in this case the posterior pillars of the pharynx are left intact while the anterior pillars and the tonsils have been removed leaving the lower part of the internal pterygoid muscles exposed. The illustration also shows the lower part of the parotid gland removed, the facial artery standing up free in the pharynx and the posterior belly of the digastric muscle sutured to the sternomastoid to wall off the carotid triangle from the pharynx. If, before suturing these two muscles, the space between them has any depth, it should be drained by a separate stab wound through the skin.

ting the more resistant strands of tissue and the blood vessels, until the lower border of the mandible and the

facial vessels crossing it are well exposed. At the border of the jaw the facial artery and vein are caught with two forceps, cut, and tied above the normal site of the buccal node that lies on the vessels. (Fig. 2). At the level of the skin incision the facial vein is divided between ligatures and after freeing the submaxillary salivary gland at its lower border it is drawn forcefully upward until the facial artery is well exposed emerging from beneath the upper border of the digastric muscle to enter the gland. As far as possible from its origin, an inch from the digastric if practicable, the artery is caught between two forceps, cut, and ligated. Then a search is made for any branches of the facial arising within one-half inch proximal to the ligature. There are usually two, a very small and a larger one, and these should be ligated. This assures a long clot in the cut stump of the facial artery. Just below the outer part of the digastric tendon, the fibers of the hyoglossus muscle are separated by thrusting in the points of dissecting scissors, and the lingual artery is grasped and ligated by Kocher's ligation. (Fig. 3).

The blood supply being now controlled, the excision is made with a cutting cautery starting at the symphysis and cutting through the digastrics, geniohyoids, geniohyoglossi, and myohyoid muscles, stripping the periosteum and mucoperiosteum from the inner surface of the jaw. If the ulcer approaches the bone, prolonged cooking with a heavy cautery is done. The tongue is next drawn out through this opening, which brings the pillars and the pharynx into plain view, the excision here being guided by the position and extent of the growth. Finally the base of the tongue is cut across right at the hyoid bone, and, I believe, it is well also at this time to remove the lower part of each parotid gland on account of the closely associated lymph nodes.

The lower border of each digastric muscle is sutured to the anterior border of the sternomastoid with fine tannated gut, and the ligated facial artery stumps are left standing out free in the pharynx. This plan of treating the facial artery, in my opinion, is safer than burying it in tissue that may become septic. I have had several opportunities to observe the subsequent course which is, if the efferent branches have been ligated, that they become occluded by a clot and then shrink up and disappear. If subsequent bleeding should occur as it did in one of my cases, from an unligated efferent branch which tore loose in a coughing spell, the sutures can be removed and the bleeder is in plain sight. If moderately enlarged cervical nodes tend to protrude from between the sternomastoid and the digastric muscles, they are not ordinarly removed, but the sternomastoid is somewhat freed so that it can be sutured over these to the digastric. If one invades the carotid triangle at this time, it is apt to complicate and unduly prolong the operation. Before closing the external wound a large catheter is passed through one nostril into the pharynx and fastened by a strip of adhesive plaster one-half inch wide, to the upper lip. After the excision, the larynx drops very low, and, unless this catheter is guided by a finger in the pharynx, it is apt to enter the glottis. The external wound is closed without drainage by silkworm-gut mattress sutures that insure deep approximation of the skin and platysma. The cut or burned surface of the parotid should not be included in the approximation, as the secretion causes induration and suppuration. The floor of the mouth and all other raw surfaces are covered with a pack of broad strips of iodoform gauze into which balsam of Peru is thoroughly incorporated, this pack to be left in place several days and then renewed as necessary until the sloughs separate. This will entirely control all odors from the decomposing sloughs.

Postoperative treatment.—The patient is put to bed in a semi-sitting posture. Proctoclysis is instituted and fluids given through the nasal tube as soon as tolerated. Frequent inhalations of benzoin steam and small doses of iodides to loosen secretions are given when necessary and morphine as needed.

The tracheal tube is retained until danger of edema or of respiratory interference from the packs is passed; before removing the tube a cork is placed in it for twenty-four hours. Usually after ten days the patient can make very effective efforts to swallow but only water should be given until one can be sure that no fluid enters the glottis, at which time the nasal feeding tube can be removed.

After six weeks a very intelligible speech is usually developed, but the rapidity of the return of all these functions depends largely on the intelligence and industry of the patient. A physician from whom I removed the whole tongue and the muscles of the floor five years ago has been practising his profession all this time and his speech is so perfect that few people know he has had an operation in his mouth, though he told me his vocabulary has been reduced about 30 per cent.

This operation is to be followed later by the radical dissection of the lymph-bearing areas of both sides of the neck; a plan for doing this that fits in with the preceding operation will be presented in the future.

The operation presented can be modified in a number of ways and in its present form is the outcome of several plans having in common the suprahyoid approach and the removal of the tumor, the muscles of the floor, and the upper lymphatics in one block.

The first operations were done in 1913 for cases of ulcer of the floor, tongue and jaw and at this time the body of the mandible was included in the excision;

now I believe that thorough cauterization of the invaded bone with a soldering iron or Percy cautery is as curative, and besides the better functional results, is a safer operation. If the cauterization of bone is too prolonged the latter may be killed through the full thickness and no regeneration occur. I have had this experience. In one instance the hyoid bone and epiglottis were included in the excision. In this case persistent edema of the glottis greatly retarded recovery of function.

This operation might be done on one side only, but I have not seen a case in which I thought it indicated that I did not believe the most radical removal was necessary.

REFERENCES

1. Butlin: Brit. M. J., 1909, Jan. 2 and Feb. 20.
2. Cheatle: Brit. M. J., 1908, Feb. 22.

DISCUSSION

Dr. Joseph Rilus Eastman (Indianapolis, Ind.): Dr. Blair did not say whether he split the symphysis or not.

Dr. Blair: There is no bone cutting; the flap is turned up in the way described, and, if the bone is involved, this is cooked until the tumor is destroyed.

CANCER INVOLVING THE MOUTH

George Noble Kreider, A.M., M.D., F.A.C.S.

SPRINGFIELD, ILLINOIS

The greatest unsolved problem of the medical world today, is the primary cause of malignant disease. We still call it cancer and with this misnomer throw about it the errors, superstitions, and misconceptions of the past centuries. The most absurd ideas concerning the disease exist in the minds of the people and even the profession. Witness the idea that grief may cause it or that certain articles of diet, like tomatoes or pork, may cause it. We must clear the board of these absurdities before we can make any headway. Acknowledged ignorance offers a good foundation for a working basis, unwarranted presumption does not. One of the most encouraging signs of the times is the plain speaking of eminent pathologists on this matter. Read the strong statement by William Carpenter Macarty, in the last (1918) Mayo Clinic volume, part of which is here given: "I shall not review in detail the facts which have led to the apparently radical declaration that the conception or conceptions which the medical profession possess of the biogenesis, histogenesis, morphology, terminology, classification, and clinical behavior of neoplasms, are *based on a few facts and a great amount of speculation and empiricism.*"

It is not generally known that a careful attempt to study cancer dates from as long ago as 1792, when a ward was set aside in the Middlesex Hospital, London, and considerable money was donated for this purpose. Unfortunately, this provision has been as sterile of results as have been the many other foundations, special institutions, and laboratories which exist in all civilized countries. May God speed their investiga-

tions and may they soon develop the truth. It seems to me that the profession does not approach the sufferer with an open mind. Too often the cases when they appear are not thoroughly studied; the hereditary influences are not determined; and the collateral existing or provocative diseases and conditions are not discovered and remedied. The great obsessions on the part of the profession are either indifference to the existing danger or great hurry to begin operating. Both attitudes are wrong. Every suspicious case should be profoundly studied along all possible lines, and none dismissed, but kept under observation. None should be hastily operated on. A week's time for observation is not asking too much in any case.

Let me urge all my colleagues to include radiograms of the chest in every case of preliminary examination for patients showing evidences of cancer in the mouth or breast. This has been my invariable procedure for the last two years. Many times such conditions will be found in the chest picture that the surgeon must hesitate to operate. However, in several of my cases the patients have insisted on operations, even though it was explained that there was little hope. The magic word operation has become a panacea with the laity. Unfortunately, the radiogram gave true information, and hope only led to disaster.

Cancer involving the mouth.—This has always seemed to me to be the most frightful form of malignant disease. When the disease attacks other parts of the body, the patient may have considerable periods of mental and physical relief; but with cancer in the mouth and especially when the tongue is affected, there are few moments of the waking hours that are devoid of pain and mental distress. These cases, therefore, deserve our particular study.

Between April and October, 1919, four mouth cases came under my observation. The first man appeared

May 19. The patient is still living at the time of this report, but his condition in August was reported very bad. The right upper maxilla was involved.

The tongue was involved in the second man, who appeared April 9th. He died June 29th, surviving eighty days. Also in the third man who appeared June 17th. He died December 10th, surviving one hundred and sixty-eight days. And in the fourth man who appeared August 6th. He died September 21st, surviving 45 days.

First observation.—Cancer involving the mouth is seen very seldom in the animal. It is not infrequent in other parts of the animal body. What is the reason for this? It can not be an accident. There must be some reason. The tongue of the dog, the cat, the cow, and the horse, is subjected to irritation by the habits of the animal, the food eaten, or the rough bit used to guide his movements, and yet no malignant disease results.

Second observation.—It is important to note that all of these were men. In civilized countries the disease is much more frequent in men than in women. This rule does not hold true in the Philippines, where the habit of buyo-chewing is common to both sexes, and cancer occurs in the mouth of both.

Third observation.—The teeth were found diseased and irritating the growth in every case. The teeth should always be removed before any treatment is attempted. In the presence of diseased teeth, to perform a surgical operation, to apply radium, to use the *x*-ray would seem to be wrong. Get the mouth as clean as possible at once, and then endeavor to remove or limit the growth.

Fourth observation.—These men all had been subjects of luetic infection. Only one showed Wassermann four plus. The Wassermann test is certainly

not to be depended on in these cases with profoundly diseased tissues and foul teeth. The history must be minutely searched, and, if this is done, certain evidence of the spirochetal invasion will be found in nearly every case.

Fifth observation.—It is a mistake to give the usual treatment for lues after cancer has developed. It seems to do absolutely no good. Lues, like cancer, must be treated early to obtain a cure.

Sixth observation.—These men, without exception, had been large consumers of alcohol. De Quervain, of Bale, says in his experience, "Tonsillar cancers have mainly occurred among heavy drinkers."

Seventh observation.—These men had been excessive users of tobacco. Some day the profession and people will wake up to the dangers of nicotine poisoning. D'arcy Powers, of London, in a recent address, prophesies that our sisters will begin to show in 1950 cancer of the mouth, as frequently as their brothers. This because of the delightful privilege of smoking and drinking in which they now indulge so freely.

Eighth observation.—Rapid progress and mortality. These cases were far advanced when they presented themselves, and they did not live long. It was not possible to operate on any of them. The first went through the treatment of a radium expert, and was pronounced cured, but his death is certain. Do our radium experts deceive themselves at times? The second case had passed through a large city hospital. He had been operated on and had radium and the *x*-ray applied. The surgeon sent him home to die. Sometimes our surgeons are not deceived. When I saw him first I discovered a mouth full of decaying teeth. The other two cases were far advanced, and only palliative treatment was possible.

Ultimata.—Malignant disease of the mouth, I firmly believe, rests on a basis of untreated or insufficiently treated lues. All of my four cases did.

Do not rely on the Wassermann test.

Do not rely on the statements of the patients.

Some acquire it innocently. Some know they have it, and acknowledge the fact. The large majority know and deny it.

To the leukoplakia base is added a combination of bad teeth, and alcoholic and nicotine poisoning.

A cloud of witnesses of all nationalities testify to the rationality of these statements.

DISCUSSION

Dr. Charles E. Bowers (Wichita, Kan.): Just how to analyze some of the conditions referred to in this paper we are often at a loss to know. The author cites cases and says that cancer of the tongue does not occur in others of the animal kingdom besides man. Cancer seldom ever occurs in the mouth of a man until he is about forty years of age or beyond that. The rest of the animals do not live that long. The elephant may, and why cancer occurs more frequently in man than in woman is just as much a mystery. Why cancer of the breast occurs more frequently in women than in men we do not know.

With reference to cancer being due to the use of tobacco and whiskey, I do not think they have anything to do with it, because, if they did, most of the people of Ireland would have died of cancer. Tobacco may be a preventive because it is an antiseptic. The men who use tobacco usually have very good teeth. Here we are philosophizing without a true basis and are apt to arrive at false conclusions.

Nicholas Senn had the moral courage to attempt to demonstrate to the world whether or not cancer was an infectious disease. He placed virulent cancer cells in an incised wound in his arm and did not reproduce the disease.

When one is called upon to sign a death certificate of an individual who died of cancer, the inquiry is made, What do you believe is the cause of cancer? I always tell them

that I do not know, and I do not think there is anybody in the world that does know the cause of cancer; consequently, when we think we are establishing something as to the cause or the etiology of cancer, we are simply speculating, and we do not know anything about it. It is the task of future research to enlighten us.

Dr. John P. Lord (Omaha, Neb.): Years ago I used to take a hand in cancer cases. When I got these cases of extensive cancer of the mouth, tongue, and jaws, I tackled them as I would undertake a case of cancer of the breast. I began at the outskirts and moved up, and ligated the vessels of the neck, if necessary. I am now speaking of the extreme cases. I began the dissection from below and carried everything upward. Some of the cases were forlorn hopes that had been through the hands of several surgeons, and some of them did not have much of their anatomy left when we had finished. I have had a few cures after such very radical surgery. I do not wish to prolong the discussion, hence you will pardon the generalization.

Recently Dr. Kreider wrote me in regard to cancer of the mouth and tongue, more particularly the tongue, whereupon I called in an old lady I had operated upon nearly four years ago. She had an extensive cancer of the tongue—that had resulted from a bad tooth. She had already had an infiltrated alveolus and receding gums about the tooth. The tonsils were involved, also the submental and sublingual glands; and lymphatics in her neck, on one side, were involved. I attacked the disease from below. The carotid was ligated and everything cleared off. The tonsils were removed; the alveolus was removed after the extraction of the tooth; and one-half of the tongue was excised. She is still living with no recurrence.

Dr. William Jepson (Sioux City, Iowa): Cancers are different in malignancy, especially the type of melanotic sarcoma. Then again, by reason of site, and possibly there is no area wherein a cancer spreads more rapidly when once it is fairly well developed, than in the tongue. In other words, as soon as it has passed beyond the mucosa into the muscularis, the constant movement of the tongue in the act of mastication and speech leads to the rapid involvement of one-half of the tongue, and any operation short of removal of one-half of the tongue is going to be a failure. As I have said, extension takes place rapidly.

I want to put on record one case that to me was in a sense novel in this respect. Years ago a patient consulted me concerning an ulcer of probably the size of an inch in diameter at the junction of the anterior with the middle third of the tongue on the left side, as I recall it, and a small piece was removed. By the way, this was before we had an opportunity of taking a Wassermann test. There was no history of syphilis obtained. A small section of the growth was removed, and was examined by a competent pathologist who declared it to be tuberculous. The man was treated by the *x*-ray at that time, and in one area of the ulcer there were beginning nodules in the course of development, and a section of them showed the man was developing carcinoma engrafted upon the tuberculous ulcer. Whether the cancer had anything to do with that, I do not know.

Dr. Charles D. Lockwood (Pasadena, Calif.): We should not dismiss the subject without laying stress upon irritation as a cause of carcinoma about the mouth. For a number of years I held a clinic at the Los Angeles County Hospital. I have seen 100 cases of carcinoma about the mouth, and the most extensive operations were done on these cases, removing the whole inferior maxilla, the superior maxilla, half of the tongue, and in some cases all of the tongue, and I have nothing to say about the results of these operations because they have been most unsatisfactory. I wish to make this statement very emphatically, however, after observing these 100 cases of carcinoma about the mouth, namely, that I have never yet seen a carcinoma of the lip where I could not get a history of the man having smoked a pipe, or putting shingle nails in his mouth, or something in his mouth that acted as an irritant to the lip. Dr. Bloodgood spoke of this in a list of 200 cases that had cancer of the tongue, and that during the whole history of the clinic at the Johns-Hopkins Hospital there was only one case of cancer in a woman, and she was a smoker. I have never yet seen a case of cancer of the tongue (and I have seen a large number of them for a man with a limited practice) that was not in a smoker. I have never seen a carcinoma of the pharynx that was not in a smoker. Carrying this still further, I have never seen a carcinoma of the cheek where there were not rotten or diseased teeth. Bearing on this phase of the subject, I will say that one of the prominent ministers in our town was constantly in the habit of biting the mucous membrane in speaking. His wife and others called attention to it. He was a young man, and one of the most brilliant ministers in

Southern California. He developed a small nodule in the corner of his mouth from constantly biting the mucous membrane of the mouth. He went to Dr. McBride, and at his suggestion I excised the nodule, which was a beginning epithelioma.

Carrying the same idea further, we get carcinoma in the cecum because there we get an arrest of the fecal matter and irritation. We likewise get carcinoma in the cervix, but usually where we have a scar. I have seen one in a nullipara, but certainly they are very uncommon. They usually have as a basis scar tissue in the cervix, and Dr. Smith, of Toronto, pointed out in a large series of cases that where he has excised these scars he has had no case of carcinoma develop.

Again, one of the speakers said that there was no reason why a woman should have a carcinoma of the breast any oftener than a man. Why? There is an adequate reason for it. The breast of a woman is being constantly irritated; she may have retention cysts, and she has many sources of irritation, and I believe in chronic irritation we have a very important,—at least, an exciting cause of carcinoma, and we should emphasize this matter at this time.

ARTHROPLASTIC OPERATIONS, WITH REPORT OF CASES OF ARTHROPLASTY OF THE TEMPOROMAXILLARY JOINT; ALSO OF THE ELBOW JOINT

A. A. Kerr, M. D.

SALT LAKE CITY, UTAH

Arthroplasty, or making a movable out of an ankylosed joint, is one of the triumphs of modern surgery. The operation consists in separating the ankylosed ends of the bones in the joint by means of a saw and chisel and interposing between the divided ends of the bone and joint a layer of fascia or soft tissue. The cut end of the bone should be sawed or chiseled off to correspond to the contour of the joint. Bony prominences and scar tissue should be removed, tension on the end of the bone should be relieved; all parts of the synovial membrane involved in the process of articulation, which is covered by adhesions and has lost its synovial character, should be covered with the transplanted tissue. One of the most satisfactory methods (advocated and described by the late J. B. Murphy) consists in cutting out a pedunculated flap of fascia and fat near the joint and swinging it between the bones to cover the rough bone surfaces. This flap is sutured in place with fine plain catgut sutures, to the capsule of the joint. Some fatty tissue is desirable in this flap. Muscle and fat may be used if fascia is not available. After about ten days, passive motion may be begun, the patient being advised and encouraged to use the joint.

An arthroplastic operation, if aseptically done on a joint not infected, may be expected to give a good result. A new synovial membrane is formed; and a

fluid resembling synovial fluid is secreted. A fibrous layer becomes attached to the end of the bone.

Ankylosis may be fibrous, bony, cartilaginous, ligamentous, capsular, or extra-articular due to contractions of soft parts, such as tendons, muscles, and fascia. M. S. Henderson and G. B. New classify their cases into: (1) the articular type in which the joint alone is involved; (2) the extra-articular type; (3) the articular-extra-articular type in which the etiology of the ankylosis is both within and without the joint.

Etiology.—Infection, either by continuity or through the blood, and traumatism are the usual causes. In my cases there was a history of infection. On account of the lapse of time it is usually difficult to secure a very clear history as to the etiological factor. Blair gives trauma as a frequent cause (50 per cent) of ankylosis of the mandible.

Pathology.—Lack of development of the mandible takes place if ankylosis of the jaw occurs before the fifteenth year. The teeth, owing to disuse may be poorly developed, and where scars exist due to infection they prevent the natural mobility of the muscles.

Diagnosis.—Bony ankylosis allows practically no mobility, whne with the fibrous variety there may be a slight motion of the joint. Röntgenograms assist some in the diagnosis, but they must be studied in connection with the clinical history and the physical findings.

Treatment.—In arthroplastry of the temporomaxillary joint, a curved L-shaped incision, beginning about two inches above and one-half inch in front of the ear and down to a point about opposite the external auditory meatus, then anteriorly for about 1.5 inches, is made.

Care must be taken to avoid the facial nerve, the internal maxillary, and superficial branches of the temporal arteries. The condyle of the mandible may be sawed off with a chain saw or removed with a chisel gouge, care being taken not to injure the internal maxillary artery. If the coronoid process is involved, a sufficient amount of it should be resected to permit free mobility. A flap of temporal fascia is inserted, and the wound closed with catgut and horsehair or fine silk to avoid an extensive scar.

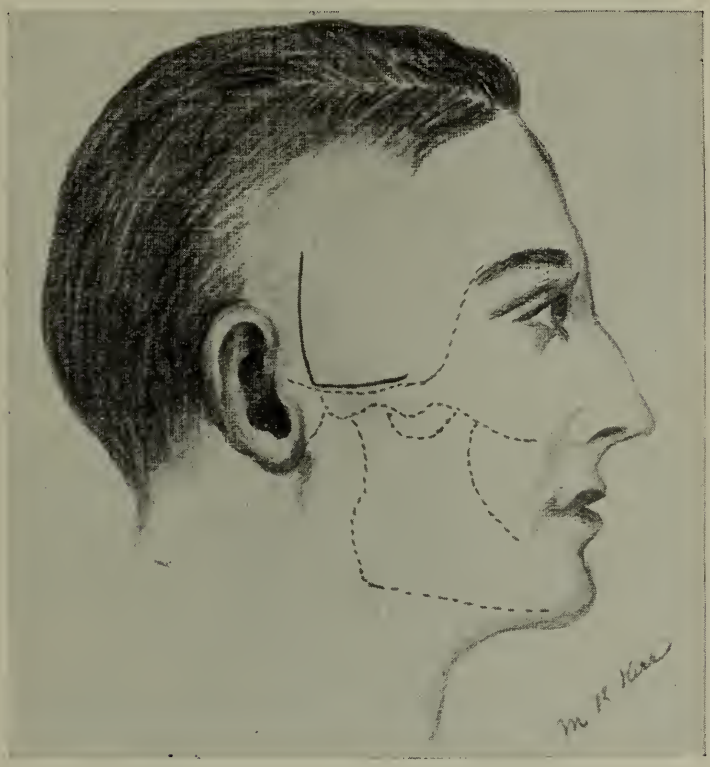

Fig. 1. Incision for arthroplasty of the right temporomaxillary joint.

Henderson and New advised against the use of any fascia, fat, membrane, or any foreign material between the ends of the mandible and the temporal bone.

The patient should be encouraged to use the jaw as soon as practicable after operation, but too powerful attempts at opening the jaw must be avoided, as in

some of these cases the teeth are easily broken or displaced. Some of the important points to be remembered in arthroplasty of the temporomaxillary joint

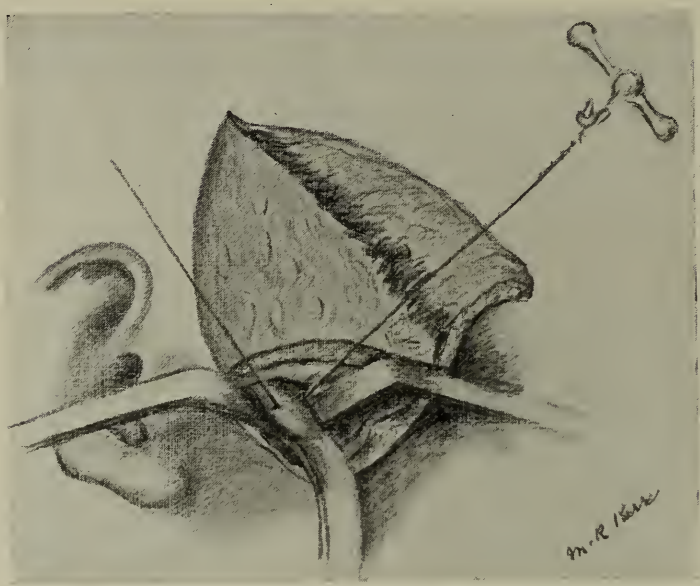

Fig. 2. Joint exposed and method of removing bone in arthroplasty of the temporomaxillary joint shown.

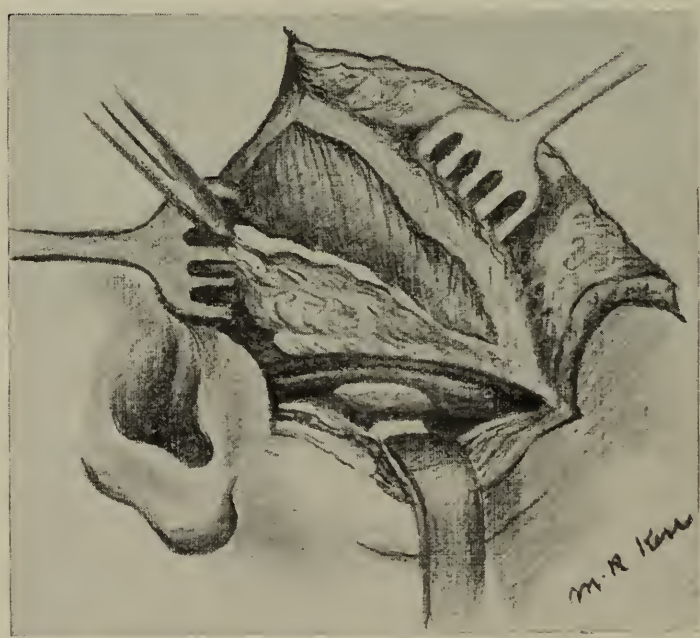

Fig. 3. Method of incising flap of fascia over temporal muscle for inserting over sawed surface of bone.

are: (1) avoidance of injury to the facial nerve, the temporal artery, and the internal maxillary artery; (2) removal of enough bone to give free motion (about one-half inch space between the bones); (3) persistent passive motion as soon as practicable after the operation.

HISTORY OF CASES

Case 1. Mr. X, aged 21. Family history, negative. In 1910 the patient suffered from what he described as inflammatory rheumatism, involving nearly all the joints of his body,

Fig. 4. Flap of fascia inserted in joint and sutured with fine catgut ligatures.

and for about eight months he was unable to work on account of the pain and weakness. He developed an endocarditis. The inflammation localized in the maxillary joints and for nine months he has been unable to open his mouth more than one-sixteenth of an inch. There is a distinct aortic regurgitant murmur over the precordia.

There is present a fibrous and bony ankylosis of both joints of the mandible with contraction of the peri-articular muscles and fascia. Röntgenograms were taken by C. W. Stewart, Arthroplasty of both temporomaxillary joints was done, using the technic previously described. Result: The patient was

able to masticate solid food after leaving the hospital, but had to guard against subsequent contractions of the muscles of the mandible.

Case 2. A girl, aged 16. Family history, negative. The patient has had good health up to two years ago, when she

Fig. 5. Location of incision in arthroplasty of the right elbow-joint.

hurt the side of her face. Following the injury she had an abscess of the right side of her face, near the parotid gland. Her family physician attempted on four different occasions forcibly to open the mouth.

The patient could not open her mouth, except for a distance of one-fourth inch at the widest place. The lower jaw was only partially developed. Otherwise she appeared fairly well nourished. She has a webbed condition of the fingers, which involves both hands. Diagnosis: bony ankylosis of the right temporomaxillary joint.

Under warm ether given by Dr. Wilson, the author, assisted by C. A. Nyvall, did an arthroplasty of the right temporomaxillary joint, using the technic as previously described, a flap being taken from the fascia of the temporal muscle. Result: Patient is able to open her mouth normally and to masticate her food naturally, and is very happy and grateful.

Case 3. A young man had a complete ankylosis of the right elbow, due to arthritis. At operation an angular incision was made beginning at the external supracondyloid ridge 1.5 to 2 inches above the line of the joint extending downward to the head of the radius and from there along the outer border of the anconeus to the posterior border of the ulna, about 3 inches below the tip of the olecranon, then curving inward. The first part of the incision extended down to the outer border and external condyle of the humerus, between the supinator longus and radial extensors anteriorly and to the edge of the triceps posteriorly. Below the external condyle it passed down to the bone between the extensor carpi ulnaris and the outer border of the anconeus and divided the strong capsule over the head of the radius, together with the annular ligament at its attachment to the ulna. The lower end of the incision divided the lower end of the anconeus subperiosteally. The incision (Kocher's) fell accurately along the interval between the muscles supplied by branches of the musculospiral nerve and those supplied by the posterior interosseous, thus preventing subsequent muscular atrophy. The outer head of the triceps, together with the periosteum and the upper attachment of the capsule was detached from the humerus and the anconeus from the back of the ulna, the attachment of the triceps from the tip of the olecranon and the flap displaced to the inner side. The external lateral ligament, with the attachment of the extensor tendons and the capsule attached to the external condyle, were separated subcortically and retracted. This enabled one to dislocate the forearm inward. The internal lateral ligament was separated subperiosteally along with the muscles from the inner border of the ulna and the internal condyle of the humerus. The ends of the bone and the diseased tissue were

removed, preserving as far as possible the contour of the joint. Some peri-articular fascia was inserted. The wound was then closed.

The result following this technic gave a useful movable joint with no atrophy of the muscles.

REFERENCES

Kocher: Operative Surgery.
Blair: Surgery of the Mouth and Jaw.
J. B. Murphy's Clinics.
Mayo Clinics, 1918.
Warbasse: Surgical Treatment.

INTENTIONAL REMOVAL OF SKIN AND OTHER TISSUES OVERLYING DEEP-SEATED INOPERABLE CANCER, A NECESSITY FOR EFFECTIVE TREATMENT WITH *X*-RAY OR RADIUM

With Report of Relative Absorption of Rays by Skin, Fat, and Muscle, as Compared with Various Thicknesses of Aluminum,

By G. W. Warner, A.B., of the Ryerson Laboratory, University of Chicago

Emil G. Beck, M.D., F.A.C.S.
CHICAGO, ILLINOIS

When confronted with a recurrent carcinoma of the breast or neck, for instance, the surgeon is apt to be too pessimistic in regard to the possibility of helping the patient. Usually the patient is referred to a röntgenologist for radium or *x*-ray treatment, partly to satisfy the hopes of the patient, who in his despair is happy to believe that something more can be done for him, and partly because we do not yet know definitely the possibilities of radium and *x*-ray therapy. We hesitate to do anything further surgically because we feel that if the surgeon was not able to eradicate all of the cancerous growth at the first operation, a second operation is apt to be much more difficult and not likely to be as radical as the first one. While recurrent cancer is not a promising field for the surgeon, still it seems to me that we have not yet exhausted all of our efforts in combating this dreadful foe. I have come to the conclusion that even in apparently hopeless cases, something more can be done, and I have

endeavored to work out a method of meeting this problem.

SUGGESTION FOR TREATMENT

It is a well-known fact that superficial malignant growths, such as epithelioma, respond readily to *x*-ray and radium treatment, while deep-seated malignant growths do not. The reason for this is very suggestive: the skin, fat, and subcutaneous tissues, which usually overlie deep-seated cancer, are strong filters for the penetration of the *x*-rays, they absorb most of the soft rays from the *x*-ray tube and allow only the hard rays, which are a small quantity, to penetrate deeply enough to reach the growth. Small quantities of radiation, instead of destroying the cancer cell, are apt to stimulate it to more rapid growth. Therefore it has seemed to me that if the skin and all the overlying tissue and as much of the growth as is feasible are removed and a large area left entirely exposed, and to this field is then applied either the *x*-ray or radium directly, we may obtain results in treating deep-seated carcinoma similar to those usually obtained in treating superficial growth. In other words our problem is to convert the deep-seated growth into a superficial one.

To verify the above hypothesis I began to use this technic in selected cases. I started with a very simple method: Instead of closing the wound after the completion of the operation for cancer of the breast, I allowed the skin edges to retract as much as possible, in order to leave an opening through which the *x*-ray and the radium treatment might subsequently be allowed to penetrate directly into the cancer bed and destroy any cancer cells which were inaccessible to surgical removal. I am aware that this had been done by others before, but I have carried the principle further. I have selected recurrent, apparently inoper-

able cases of deep-seated carcinoma, such as cases of cancer of the axillary and supraclavicular glands subsequent to removal of the breast, and in these selected cases I have removed intentionally large areas of skin, fat, fascia, and muscles and as much of the carcinoma as is consistent with the safety of the operation. The entire area was left exposed for the application of either *x*-ray or radium treatment. (Fig. 1.) During

Fig. 1. Showing extent of intentional removal of tissues preparatory to x-ray and radium treatment.

the past two years I have subjected a series of cases to this form of treatment, and, while it is too early to form definite conclusions, I desire to report the findings and results thus far obtained.

PHYSICAL PROPERTIES OF RADIATION

The physicists teach us that three varieties of rays emanate from radium: alpha-ray, beta-ray, gamma-ray. The alpha-rays constitute 91 per cent of all the rays emanated from radium, the beta-rays about 7 per cent, the remainder, gamma-rays, only about 2 per cent. The gamma-rays are very readily absorbed by metal foil or even by the air. Rutherford says that a thickness of 6/1000 aluminum or mica, or even a sheet of ordinary writing paper, is sufficient to absorb completely all the alpha-rays. Almost all of the beta-rays are absorbed in 5 millimeters of aluminum or 1 millimeter of lead. Only the gamma-rays will penetrate these filters. The density of tissues depends upon the close packing of the molecules which compose them. In fat, for instance, the molecules are far apart, while in the skin or muscles they are more closely packed, and in metals, such as lead or silver, the molecules are extremely dense. The shadows on the photographic plate of these different substances give us an approximate indication of the molecular composition. Lead will produce a very dense shadow, while fat or muscle will give a correspondingly lighter shadow.

For a rough working rule, it may be taken that the thickness of matter required to absorb any type of rays is inversely proportional to the density of the substance. Thus the alpha-rays have very little effect in the treatment of either superficial or deep-seated growths. The beta-rays, however, are about one hundred times as penetrating as the alpha-rays, and the gamma-rays are from ten to one hundred times more penetrating than the beta-rays. Therefore, it is evident that the alpha-rays may be entirely ignored as far as the treatment of cancer is concerned. We must depend entirely upon the action of the beta- and gamma-rays. Are we at present utilizing them to their

full extent? We are not. The skin, being the densest of all structures of body, is itself quite an obstacle to the penetration of the *x*-rays; it produces a shadow on the *x*-ray plate equal to that of three-fifths of a millimeter of aluminum, because of the arrest of the rays by the skin; and while the underlying tissues, such as muscle, fat, and fascia, absorb still more of the rays, it is likely that very few of the rays ever reach the deep-seated tumor. Thus, we deprive ourselves of the action of the greater quantity of the most effective rays emanating from the radium; namely, the alpha-rays. Even the gamma-rays lose some of their intensity in passing through the skin and subcutaneous tisues.

To determine just how much of the *x*-ray is absorbed by the skin, fat, and muscle, we have two methods at our disposal: one is the *photographic* method and the other the *electroscopic*. The following experiments have been undertaken by me to determine the quantity of *x*-ray absorbed by the tissues:

First. A piece of *skin,* free of fat, removed from the knee of a young man, was placed on an *x*-ray plate, and beside the skin were placed three strips of aluminum of different thicknesses,—one-fifth, two-fifths, and three-fifths of a millimeter, respectively. Comparing the shadow produced upon the plate by the aluminum and that by the skin, we can approximately estimate the relative amount of rays absorbed by the skin. (Fig. 2.) It appears that the skin absorbs about as much as does three-fifths of a millimeter in thickness of aluminum, which is considered by röntgenologists a substantial filter for the rays.

Second. A layer of *fat*, one-half inch in thickness, was placed along a series of five aluminum filters, ranging from one-fifth of a millimeter to one millimeter in thickness. A röntgenogram for comparison of these two substances was made in a way similar to







Figs. 2, 3, 4. Compare the density of shadows produced by different thicknesses of aluminum with that of certain thicknesses of tissues, namely, skin, fat, and muscle.

that in the case of the skin experiment, and it was shown that one-half inch of fat would arrest on the average about as much of the rays as two-fifths of a millimeter of aluminum would filter. (Fig. 3.)

Third. The same experiment as for fat was made with *muscle* tissue. A piece of beefsteak, three-quarters of an inch in thickness, was placed alongside the filter scale, and the shadow produced by the beefsteak was at least three times as dense as that obtained from one millimeter of aluminum. (Fig. 4.)

Thus it would appear that three-quarters of an inch of muscle would be capable of absorbing all the beta-rays from radium.

The measurements of the absorption of rays by means of the electroscope are more accurate and are now being conducted by G. W. Warner, A. B., at the Ryerson Laboratory of the University of Chicago. The report of his work is here appended. His experiments show that our photographic measurements are approximately correct,—namely, that a great portion of the harder rays are absorbed by the skin, fat, and muscle.

REPORT OF CASES

Taking into consideration these physical characteristics of the rays, I have concluded that, in order to have a full measure of the effective *x*-rays reach the tumor, we must remove the obstruction to their passage,—namely, skin and muscle,—and as much of the tumor as possible. The procedure will be best understood by the demonstration of cases because the operation must of necessity be different in each case. For illustration I shall cite several cases from a larger series in which this treatment has been tried. We must bear in mind that we are attempting the almost impossible and cannot expect that a magic cure will follow in miraculous fashion. If we can improve only

in a small degree upon previous methods, we are taking a step in the right direction, which may finally lead to fruitful results.

The method is based on scientific principles, and, while the number of cases thus far treated is not sufficiently large to draw definite conclusions, the results are encouraging enough, considering the hopelessness of the cases, to justify its application. The patients are usually perfectly willing to undergo one more operation, because they have lost all hope of getting well.

What becomes of this large denuded surface after the growth has apparently disappeared? The skin will gradually grow from the edges of the wound until it covers the entire surface. The growth of epithelium is accelerated by the aid of adhesive plaster.[1] The growth of skin over the cancer area is proof in itself that the cancerous tissue has been eliminated, because heathly epithelial cells will not grow over cancer tissue. I have observed in the cases I have treated that skin will grow over large surfaces which formerly contained masses of cancerous tissue. Whether there will be metastatic tumors in other parts of the body following this treatment is an unsolved question. It is likely that there will be. The susceptibility to cancer recurrence in what is called a cancer individual may still remain, even though the growth in a particular region be destroyed. It has been stated by some observers that subsequent to the *x*-ray treatment changes take place in the entire body, and the changes immunize the patient against recurrence. This is too extensive a question to be discussed in this paper.

The following cases will serve as illustrations of this method of treatment:

Case I. Recurrent carcinoma of the breast, wound left exposed at last operation. Mrs. S. S. was operated on in

1. Method described in Ann. Surg., 1919, April.

Stereophotograph B. Recurrent carcinoma of submaxillary gland.

Stereophotograph C. Recurrent carcinoma of middle ear and neck.

Stereophotograph D. Recurrent carcinoma of submaxillary gland.

August, 1916, for a tumor of the breast. The breast was not removed. The microscopic specimen of the tumor showed carcinoma; therefore it was decided to remove the breast and axillary glands, which I did on August 8, 1916.

Instead of closing the entire wound, a window about 4 by 4 inches was left exposed for the purpose of treating the underlying tissues with *x*-ray. The treatment was carried on for three months, during which time the skin gradually grew from the edges and finally covered the entire denuded area, as shown in Figures 5, 6, and 7.

The patient had no recurrence in the breast, but returned in September, 1917, complaining of a continued headache in the frontal region, loss of appetite, but no loss of weight. Whether this headache was a sign of metastasis in the brain cannot be stated, as the patient would not consent to any exploration, and we lost track of her.

Case 2. Carcinoma of jaw—open method for deep therapy. H. H., aged 60, developed a carcinoma of the lower left lip, which was removed in July, 1915. The wound healed. In 1917 he noticed a lump the size of a hazelnut growing inside of his lip in the same region. Within two months the glands on the left side of the neck began to enlarge. A radical operation was performed in October, 1917, with resection of the submaxillary gland and of all the lymphatics on that side, as well as a resection of the tumor in the mouth and part of the lip. A large amount of skin overlying the maxil-

---

Stereophotograph B.[1] A man 58, first radical operation for carcinoma of the submaxillary gland in 1919. Recurrence took place with great rapidity, so that it involved the recurrent laryngeal nerve, producing hoarseness and inability to open mouth. Case pronounced inoperable by competent surgeons. This stero illustrates the extent of the intentional removal of tissues during which the jugular vein was excised. Radium and x-ray treatments are being carried out at present.

Stereophotograph C. A man of 66, who had a very extensive carcinoma involving the middle ear and mastoid region and entire neck down to the supraclavicular region. This stereo shows the extent of the operation, excising all the carcinomatous tissues surrounding the ear. The lower part of the exposed ear was separated from the bone and later on sutured to the wound in order to preserve the ear.

The entire surface was left exposed for radium and x-ray treatment.

Stereophotograph D. A man 53 years of age presented himself with a large recurrent carcinoma of the submaxillary gland, involving the glands of the neck. Primary operation performed in Ohio. This stereo illustrates the total excision and depth of the carcinoma, exposing the entire transverse ramus of the jaw. Patient is being treated with radium and x-ray.

1. These stereophotographs should be viewed through a stereoscope.

Fig. 5.

Fig. 6.

Fig. 7.

Fig. 5. Denuded surface left open for subsequent application of radium and x-ray.

Fig. 6. Granulating surface gradually being replaced by skin growing from the edges, after prolonged treatment with x-ray.

Fig. 7. Dry surface one year subsequent to operation.

lary bone was removed and a flap of skin was shifted over to cover the defect. (Fig. 8, insert.) Healing took place within two months, as shown in Figure 8.

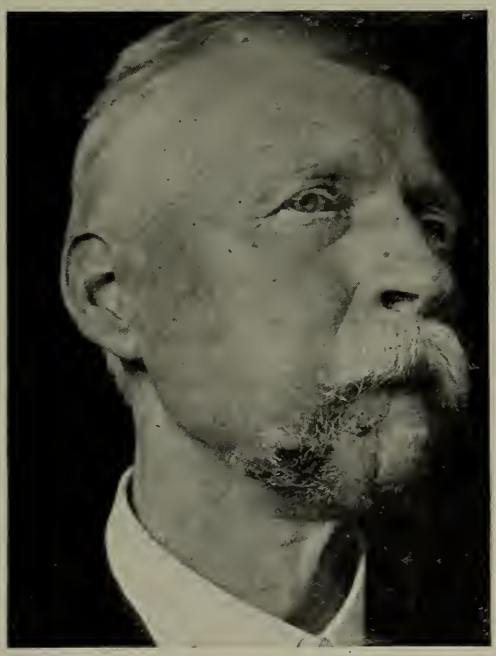

Fig. 8. Plastic operation subsequent to removal of carcinoma of the neck and lower jaw. Insert shows complete healing four weeks later.

Fig. 9. Recurrence about six months later.

In July, 1918, recurrence took place in the lower maxillary bone. (Fig. 9.) Another radical operation was performed, this time resecting the lower part of the transverse ramus of the lower jaw and all the overlying tissue, and the ascending ramus was curetted. The wound was not closed. Radium and *x*-ray treatments were applied directly into the diseased tissue. (Fig. 10.)

Under the treament healing took place rapidly, the skin gradually grew over the exposed area. (Fig. 11.) The patient remained perfectly well until April, 1919, when he developed severe headache and earache. It was uncertain as to whether there was any recurrence high up under the cranium, but very likely there was. There was no recurrence, however, in the neck or at the seat of the operation, which was treated by the exposed method. The patient is still under observation. End-result is uncertain.

Case 3. Recurrent cancer of breast, supraclavicular excavation. Dr. J. C., aged 48, married; one healthy child. The

patient developed carcinoma of the left breast in June, 1918. Although it was growing rapidly, and she was losing in

Fig. 10. Open operation, removing muscle and part of the maxillary bone. Radium inserted into the ramus of the jaw.
Fig. 11. Skin gradually covering the denuded surface; lip preserved.

weight, she refused the removal of the breast until September, 1918, when all axillary glands were involved, and a noticeable mass and induration were felt above the clavicle. The breast was removed in September, 1918, with radical removal of all glands and muscles below the clavicle. Daily *x*-ray treatment was given after the operation to reduce the involvement in the supraclavicular region, but, instead of a reduction, the growth increased in size and the arm became swollen. She could not raise it above 90 degrees. (Fig. 12.)

I decided then to remove the skin, fat, and all cancerous involvement above the clavicle within reach. This was done on January 21, 1919. An area of three inches in width and five inches in length was denuded, the clavicle was entirely exposed, and as much diseased tissue above the clavicle as was feasible was extirpated; no attempt was made to close the wound. (Fig. 13.)

Through the wound daily *x*-ray treatments for one month were given and radium was applied once a week for twelve hours. The crater gradually filled up with what appeared to be normal tissue. On February 1, 1919, we began the appli-

Plate I. Removal of recurrent carcinoma (third operation), wound left open, for radium.

Stereophotograph A. Open operation in recurrent carcinoma of inguinal glands.

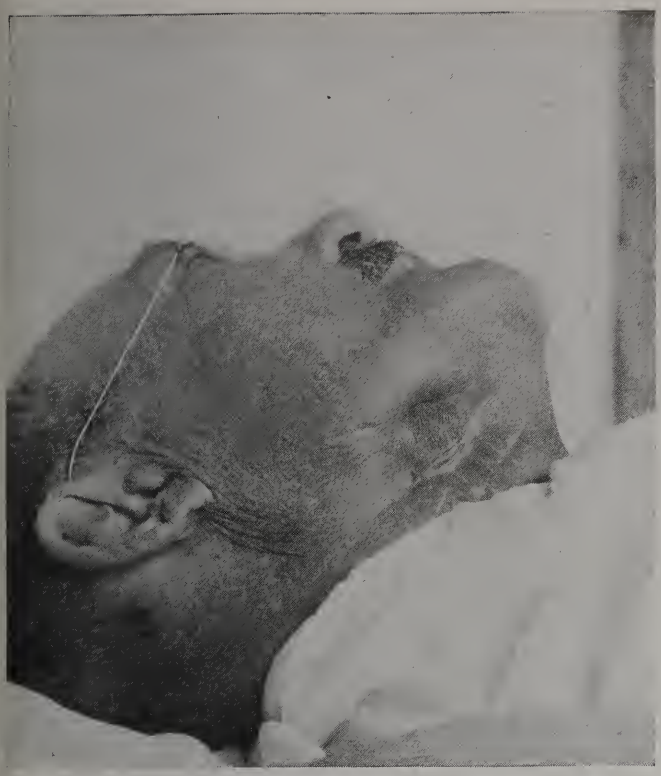

Plate II. One and a half years after operation, denuded surface entirely covered with new skin grown from the edges, no recurrence up to date, patient gained 30 pounds.

Fig. 12.

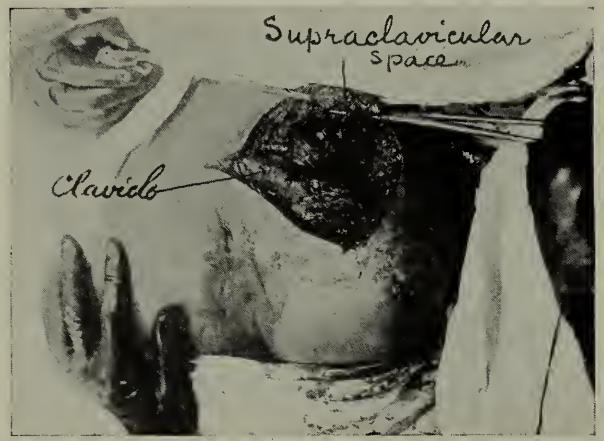

Fig. 13.

Fig. 14.

Fig. 12. Recurrent carcinoma of the breast in the supraclavicular region. Edema of arm.

Fig. 13. Removal of skin, fat and muscles, and supraclavicular involvement; wound left open for treatment.

Fig. 14. Five months later, wound entirely covered with skin; patient gained twenty pounds, perfect motion in arm. No recurrence up to date.

cation of adhesive plaster along the edges of the wound for the purpose of favoring regeneration of the skin. This proved satisfactory, and at present the entire wound is covered with dry skin, and no recurrence of the cancer has as yet taken place. The patient has been gaining at the rate of one to two pounds a week since the last operation. (Fig. 14.)

Case 4. Cancer of neck with recurrence after two operations, third operation with open wound proved effective. Mr. A. L. M., aged 54, developed a cancer of the lip early in 1916. The same was excised, and for several months there was no recurrence. In November, 1916, several glands in the region of the sternocleidomastoid were found and a radical excision of the same was done. Recurrence took place after this operation, but the patient would not submit to a more radical procedure until the tumor was of considerable size, when, in March, 1918, a very radical operation was performed by Dr. Carl Beck. *X*-ray treatment was given and radium also was then applied almost daily over the sutured wounds, but recurrence took place as quickly as before, and within three months there was a tumor the size of an orange in the submaxillary region, the original seat of the trouble. In this desperate condition, the patient presented himself to me, and I proposed the open method of treatment, which was carried out as follows: A circular flap, with the base pointing to the lower jaw was lifted up, and all of the tumor mass that could possibly be removed was eliminated. The skin flap was then pushed underneath the inner ramus of the jaw and kept there by gauze packing. This left the wound entirely exposed.

Into the depth of this wound 10 milligrams of radium element was inserted for twenty-four hours. This was repeated every week, besides the daily exposure of the wound to the *x*-ray. The patient began to gain in weight rapidly, twenty pounds to date, the skin began to grow into the wound by the aid of adhesive plaster, and now, more than a year later, the patient is in perfect health, without a sign of recurrence. (Plate II.)

We have done even more extensive operations upon three other cases of recurrent carcinoma of the jaw or the submaxillary gland, but it is still too early to make a report as to the therapeutic results. At present I will simply include photographs to illustrate to what extent we should go in removing the overlying tissues

in cases of this kind. A final report of the entire series of cases will be made when sufficient time has elapsed to permit us to judge more or less the therapeutic effects of this treatment.

Stereophotographs B, C, and D show the extent of the removal of skin, fat, fascia, and glandular structures, and as much of the tumor as feasible. A short history and description of the operation is found in the legends for these illustrations.

Another illustration of the extent to which we may proceed in resecting recurrent carcinoma in the inguinal region is shown in the colored Lumière stereophotograph A. (Not shown herein.)

In this case there was a most extensive involvement of the inguinal glands, the lower part of the abdominal muscles and the glands beneath Poupart's ligament, subsequent to a primary carcinoma of the scrotum. The deep vessels were involved also. All the tissues overlying the tumor and as much of the tumor, including Poupart's ligament, as possible were removed in January, 1919, and the large surface shown in the picture left for subsequent radium and *x*-ray treatment. Rapid improvement followed first, and the tumor mass has almost disappeared, so that the patient was able to travel to Detroit to be presented before the Western Röntgen-Ray Society. Later metastatic tumors appeared in the right inguinal region, which were excised early enough to prevent involvement of the deeper structures. Unfortunately, the patient had a severe hemorrhage from an erosion of the femoral vein on the left side, the first involved, which caused sudden death.

The subject is here treated mainly from the standpoint of the surgeon and not from that of the röntgenologist. Thus the points of the technic of the application of the *x*-rays, etc., are omitted. This important part of the work is being worked out by Dr. Paul Eisen, röntgenologist at the North Chicago Hospital, who has treated all of my cases and who will in due time publish his observations, as well as those I have had in the application of radium.

The röntgenologist is handicapped when such cases are referred to him for treatment, for the surgeon has closed for him the door to success by suturing the wound over the area to be treated. When the surgeon realizes that the full exposure of the cancer bed is necessary to avoid recurrence, he will disregard the cosmetic effect and prepare the field for efficient Röntgen treatment.

I present this subject in this immature state merely that others may try it and help perfect the surgical as well as the Röntgen technic. It certainly can do little harm to these poor individuals who have nothing but misery and death to look forward to.

Relative Absorption of Rays by Skin, Fat, and Muscle, as Compared with Various Thicknesses of Aluminum, by

G. W. Warner, A.B.

A hydrogen tube with tungsten target was used, excitation being produced by a transformer and rotary rectified (Victor). The absorption was measured by an ionization method. The distances of 16 to 32 inches refer to the distances from the target to the window of the ionization chamber. The numbers are percentages of the total incident rays absorbed,—namely, one aluminum screen absorbed approximately 25 per cent of all the rays falling upon it in the conditions given in Table 1. The aluminum screens were of standard type but varied from 0.20 to 0.23 millimeters in thickness. Since the time of exposure was of necessity very short and because the effects from equal short intervals of time are not equal, due to the variations in the primary current, no attempt was made to keep the time intervals constant, but in general it

was somewhat longer for the 32-inch distance than for the 16-inch distance.

In Table 1 two sets of data were taken for the 16-inch distance for each absorbing substance. A comparison of these results shows that the percentage of variation is in all cases less than 1. Comparing the results for the two distances shows that for short dis-

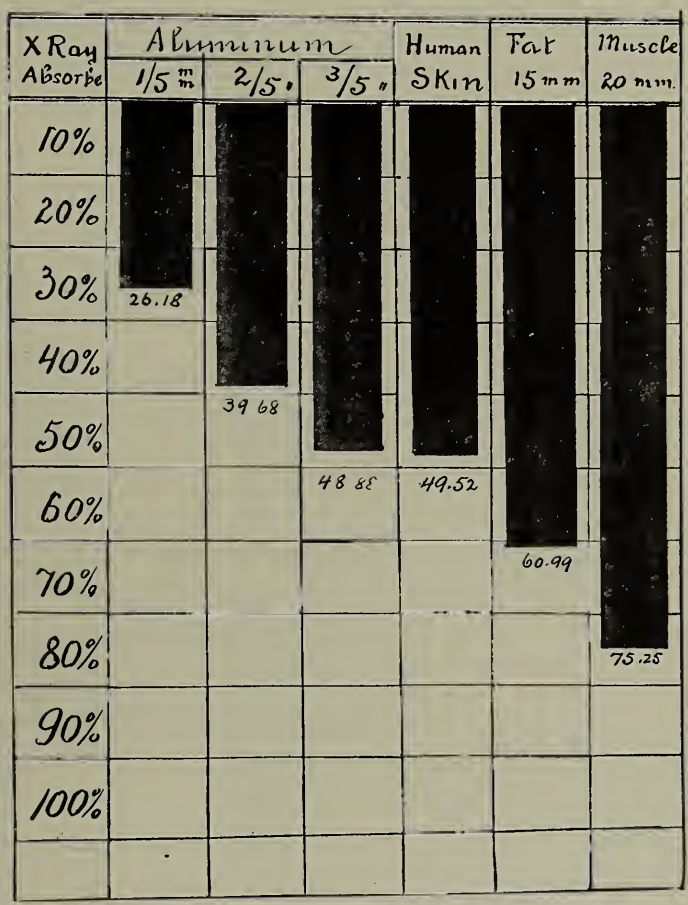

Chart 1. Absorption of x-rays by skin, fat, and muscle, as compared with ⅕, ⅖ and ⅗ millimeters of aluminum.

tances there is practically no difference in the percentage of absorption, hence in the remainder of the work the 32-inch distance was used.

In Table 2 the same absorbing substances were used as in Table 1, but with the addition of three other

substances. The heterogeneous rays were obtained with the same conditions as before except that the voltage and consequently the current through the tube were increased slightly. The medium-hard rays were obtained by screening out the soft rays by interposing a piece of plate-glass between the tube and the ionization chambers.

The great variation in the two samples of skin is easily accounted for by the fact that the first sample was much thicker and of more uniform thickness than the second.

TABLE I

Absorbing Substance	Conditions Victor H. Tube, Tungsten target Spark 5 inches Current 1.2 milliamperes. 16 inches	32 inches
One aluminum screen	25.06 25.18	24.07
Two aluminum screens	37.48 37.14	37.18
Three aluminum screens	45.40 45.04	45.06
First sample skin	46.45 45.65	46.48

TABLE II

Absorbing Substance	Conditions Victor H. Tube, Tungsten target Spark 5.5 inches Current 1.6 milliamperes. Distance, 32 inches Heterogeneous	Medium Hard
One aluminum screen	26.18	
Two aluminum screens	39.88	
Three aluminum screens	48.88	
First sample skin	49.32	
Second sample skin	17.91	8.08
Fat 15 millimeters thick	60.99	31.49
Beef 20 millimeters thick	75.25	42.88

The slight increase in percentage absorption with increased voltage would at first seem to indicate that the absorption is greater for hard rays than for soft ones; but, as all the soft rays are screened out by interposing the plate-glass the percentage absorption is cut down approximately half, and the explanation is no doubt that, while increased voltage did produce some

harder rays, it also produced a proportionally greater number of soft rays, thus increasing the percentage absorption for the heterogeneous beam. The very great decrease in percentage absorption for the harder rays seems to be a plain indication that the fleshy tissues are quite transparent to hard rays.

It is usually unwise to attempt to draw a conclusion from incomplete data but it seems safe in this case to predict that a few centimeters of body tissues would act effectively as a screen for nearly all the soft rays, but would be quite transparent to hard rays. Hence if it be the soft rays that are valuable in therapeutics, the removal of parts overlying the diseased organ is quite essential; but if hard rays are the valuable ones, then removal of the overlying tissues seems unnecessary.

Chart 1 illustrates the comparative figures of ray absorption by various tissues.

DISCUSSION

Dr. E. H. Skinner (Kansas City, Mo.): I am very glad to see this work put before the profession because it will permit the röntgenologist and radiologist to be more courageous in the application of the *x*-ray.

The success of *x*-ray therapy in these malignant conditions depends upon the thoroughness with which it is done. You must use the *x*-ray courageously and use multiple portals of entry. The removal of the skin, it seems to me, is not the deciding factor in these cases. This method, however, is one which every *x*-ray man would be glad to support, but, if the surgeons do not feel they want to submit their cases to these radical measures, they can attain approximately the same results by large doses of the *x*-ray, and letting the patient know that you may burn the skin. A burnt skin is nothing compared to the death of the patient, and if the surgeon will support the *x*-ray man in giving large doses of the *x*-ray, regardless of the skin effect, there will be better results.

Of the eight or nine *x*-ray burns I have seen, one of which I produced with a full knowledge it was going to occur, I

have seen excellent results from the surgical excision of the ulcer and skin-grafting. The case in which an *x*-ray burn was produced was one of recurrent supra-clavicular carcinoma. The patient had had three operations upon the breast and was going down hill rapidly. We produced a burn above the clavicle because we wanted to get in sufficient of the *x*-ray. She is still alive. This was five years ago, and she has a perfectly good result, which approximates these results reported by Dr. Beck. But she has a skin-graft instead of a scar, as this patient shows. You can use skin as a filter if you want to instead of using aluminum, and while you will burn the skin you will get the results, if you give enough *x*-ray or radium.

It is important to have these new ideas in technic, as brought out by Dr. Beck, and from an institution where they are able to go ahead with their own ideas and carry them into effect. I am very glad to have seen these cases; it will give us renewed courage to go ahead with the larger doses of *x*-ray, which are necessary. There is no use in pestering these patients with too small doses of *x*-ray or too much filtration.

Dr. John P. Lord (Omaha, Neb.): I was a pioneer in the use of the *x*-ray in Omaha. I had the first apparatus, and early in its use I regarded *x*-ray burns as insignificant in their results as compared with the formidable disease which we were trying to remove.

There was referred to me many years ago a case of inoperable sarcoma of the face and neck the treatment of which illustrates what I am about to say. It is recognized that sarcoma breaks down more rapidly than carcinoma, but the principle is what I wish to emphasize. The tumor, which involved the parotid and side of the face, almost obliterated his nose. All lines of his neck had disappeared, because of the fullness of the growth occupying the whole side of the face and neck. The growth was so large that one eye was shut. It was absolutely inoperable. I put him under the *x*-ray, told him that we would burn him, and that we had to move fast to save his life. He was a young fellow, about 19 years of age. He said, "All right; I am ready for anything." He wanted something done. He had one hundred and five *x*-ray treatments; he had them every day. In some of the treatments the tube was within two and a half inches of the surface. One treatment lasted forty minutes. My

operator was a morphine addict, and as a result of that the man was subjected to a seance of forty minutes.

This growth broke down so rapidly that it was necessary to slit open nodules now softened to evacuate the very rapidly liquefying material. The man had a most profound toxemia, but we went ahead because there was no time to lose as he was enduring the treatment. He had sloughing of the skin that involved his chin, his face, his clavicle, and the point of his shoulder. The necrosis was so extensive that the fascial planes and the aponeuroses of the muscles broke down, and it was necessary to excise everything down to his vessels. It was then our task to fill up the gaps. No success had been obtained with skin-grafting because the fibrous tissue continually broke down and interfered with the maintenance of a healthy wound. After this very extensive excision of the devitalized parts was made, a flap was turned in from his shoulder, and another from his deltoid region to fill up this gap. This man was living eight years afterwards and apparently cured. After that I lost track of him.

I recite this case not because I am doing this work now, for I am not, but to claim a little credit for the profession and to show what can be done with the *x*-ray if it is pushed without regard to minor consequences, and this case only illustrates some of the success from the *x*-ray before the days when we knew how to measure it or knew anything about filtering it. It was pushed to this extent, in this particular case, but also with gratifying results in the more superficial forms of true cancer.

Dr. Beck (closing): Dr. Lord's case was one of sarcoma, in which the tumor yielded better to *x*-ray treatment than a carcinoma would, even if the skin is not denuded, and we do not necessarily denude the skin. But, if the operation of removal of the tumor before using the *x*-ray treatment had been resorted to, I think Dr. Lord would have had a quicker result without burning of the skin. Burning of the skin is painful to the patient, and one is liable to a suit for damages when he burns the skin. I remove the skin in the case of a large tumor, and then use the *x*-ray treatment.

The indiscriminate use of the *x*-ray by one who does not thoroughly understand the technic of its use is a dangerous thing. In these days we do not expose patients for forty minutes. We can measure the dosage of the ray today with

the Coolidge tube, and all I can say is, if those who have cases like this all the time, will read this article (a reprint of which I will be glad to send any of you), and carry out the treatment according to the rules, they will be surprised as to what can be done in these apparently hopeless cases.

MEMBERS OF THE WESTERN SURGICAL ASSOCIATION, DECEMBER; 1919

ARRANGED ALPHABETICALLY

Abbott, Amos W. ..... Minneapolis, Minn.
Andrews, E. Wyllys ..... Chicago, Ill.
Aylen, James P. ..... Fargo, N. D.

Babler, Edmund A. ..... St. Louis, Mo.
Bailey, Frederick W. ..... St. Louis, Mo.
Balfour, Donald C. ..... Rochester, Minn.
Bartlett, Willard ..... St. Louis, Mo.
Basham, David Walker ..... Wichita, Kansas
Beck, Emil G. ..... Chicago, Ill.
Benjamin, Arthur E. ..... Minneapolis, Minn.
Besley, Frederick A. ..... Chicago, Ill.
Binnie, John F. ..... Kansas City, Mo.
Black, Carl E. ..... Jacksonville, Ill.
Blair, Vilray P. ..... St. Louis, Mo.
Blesh, Abraham L. ..... Oklahoma, Okla.
Bowers, Charles E. ..... Wichita, Kansas
Brockman, David C. ..... Ottumwa, Iowa
Byford, Henry T. ..... Chicago, Ill.

Case, James T. ..... Battle Creek, Mich.
Clark, Edmund D. ..... Indianapolis, Ind.
Clopton, Malvern B. ..... St. Louis, Mo.
Cochran, Guy ..... Los Angeles, Calif.
Coffey, Robert C. ..... Portland, Ore.
Collins, Arthur N. ..... Duluth, Minn.
Collins, Clifford U. ..... Peoria, Ill.
Colvin, Alex R. ..... St. Paul, Minn.
Connell, F. Gregory ..... Oshkosh, Wis.
Corbett, J. Frank ..... Minneapolis, Minn.
Corwin, Richard W. ..... Pueblo, Colo.
Cottam, Gilbert G. ..... Sioux Falls, S. D.
Coughlin, William T. ..... St. Louis, Mo.
Coventry, William A. ..... Duluth, Minn.
Crossen, Harry S. ..... St. Louis, Mo.
Cubbins, Wm. R. ..... Chicago, Ill.

Davis, Byron B. ..... Omaha, Neb.
Davis, Carl B. ..... Chicago, Ill.
Dennis, Warren A. ..... St. Paul, Minn.
Dunsmoor, Frederick A. ..... Minneapolis, Minn.
Dyas, Frederick G. ..... Chicago, Ill.

Earl, Robert.....St. Paul, Minn.
Eastman, Joseph Rilus.....Indianapolis, Ind.
Eisendrath, Daniel N.....Chicago, Ill.
Eliot, Ellsworth (Honorary).....New York City, N. Y.
Evans, Edward.....La Crosse, Wis.
Evans, John L.....Wichita, Kas.

Fairchild, David S., Jr.....Clinton, Iowa
Fairchild, David S., Sr.....Clinton, Iowa
Fay, Oliver J.....Des Moines, Iowa
Fowler, Ora S.....Denver, Colo.
Franklin, John H.....Spring Valley, Ill.
Freeman, Leonard.....Denver, Colo.
Frick, William J.....Kansas City, Mo.
Fuller, William.....Chicago, Ill.

Gatch, Willis D.....Indianapolis, Ind.
Grant, William W.....Denver, Colo.
Gray, George Morris.....Kansas City, Kas.
Griffith, Jefferson D.....Kansas City, Mo.

Haines, Willard D.....Cincinnati, Ohio
Halstead, Albert E.....Chicago, Ill.
Hancock, John C.....Dubuque, Iowa
Hanna, Robert A.....Peoria, Ill.
Hare, Earle R.....Minneapolis, Minn.
Harris, Malcolm L.....Chicago, Ill.
Harsha, William M.....Chicago, Ill.
Hegner, Casper Frank.....Denver, Colo.
Henderson, James P.....Kansas City, Mo.
Henderson, Melvin S.....Rochester, Minn.
Hertzler, Arthur E.....Kansas City, Mo.
Hessert, William.....Chicago, Ill.
Hill, Howard.....Kansas City, Mo.
Hill, Roland.....St. Louis, Mo.
Hollowbush, Joseph R.....Rock Island, Ill.
Hopkins, Clarence W.....Chicago, Ill.
Horton, George M.....Seattle, Wash.

Ide, Arthur W.....Brainerd, Minn.

Jackson, Jabez N.....Kansas City, Mo.
Jackson, Reginald H.....Madison, Wis.
James, Charles S.....Centerville, Iowa
Jepson, William.....Sioux City, Iowa
Jonas, August F.....Omaha, Neb.
Jones, Samuel F.....Denver, Colo.
Judd, Edward S.....Rochester, Minn.

Kahn, Maurice.....Los Angeles, Calif.
Kanavel, Allen B.....Chicago, Ill.
Kerr, Archibald A.....Salt Lake City, Utah
Kimball, Hannibal H.....Minneapolis, Minn.
Knott, Van Buren.....Sioux City, Iowa
Kreider, George N.....Springfield, Ill.

Lamson, Otis F.....Seattle, Wash.
Law, Arthur A.....Minneapolis, Minn.
Leighton, William E.....St. Louis, Mo.
Lemon, Charles H.....Milwaukee, Wis.
Lewis, Dean D.....Chicago, Ill.
Lockwood, Charles D.....Pasadena, Calif.
Lord, John P.....Omaha, Neb.
Lyman, Charles B.....Denver, Colo.

McArthur, Lewis L.....Chicago, Ill.
McCarthy, Wilton W.....Des Moines, Iowa
McDonald, Archibald L.....Duluth, Minn.
McGraw, Henry R.....Denver, Colo.
McKinnie, Lewis H.....Colorado Springs, Colo.
McNaught, Francis H.....Denver, Colo.
MacLaren, Archibald.....St. Paul, Minn.
Maclean, Neil John.....Winnipeg, Canada
Macrae, Donald, Jr.....Council Bluffs, Iowa
Magie, William H.....Duluth, Minn.
Mann, Arthur T.....Minneapolis, Minn.
Mayhew, David P.....Colorado Springs, Colo.
Mayo, Charles H.....Rochester, Minn.
Moore, Edward C.....Los Angeles, Calif.
Myer, Max W.....Columbia, Mo.

Nicholson, Clarence M. (Honorary).....St Louis, Mo.
Nifong, Frank G.....Columbia, Mo.

Pearse, Herman E.....Kansas City, Mo.
Percy, James F.....San Diego, Calif.
Plummer, Samuel C.....Chicago, Ill.
Porter, Miles F.....Fort Wayne, Ind.

Quain, Eric P.....Bismarck, N. D.

Ransohoff, Joseph.....Cincinnati, O.
Ransohoff, Lewis J.....Cincinnati, O.
Reed, Charles A. L. (Honorary).....Cincinnati, O.
Reynolds, William T.....Kansas City, Mo.
Richardson, Witham W.....Los Angeles, Calif.
Richter, Harry M.....Chicago, Ill.

Ricketts, B. Merrill.....Cincinnati, O.
Riggs, Theodore F.....Pierre, S. D.
Ritchie, Harry P.....St. Paul, Minn.
Robinson, Samuel.....Santa Barbara, Calif.
Rochford, William E. (Honorary).....Minneapolis, Minn.
Rockafellow, John C.....Des Moines, Ia.
Rowan, Charles J.....Iowa City, Ia.

Sala, St. Elmo M.....Rock Island, Ill.
Salter, P. Harold.....Norfolk, Neb.
Sanders, Evander M.....Nashville, Tenn.
Schwyzer, Arnold.....St. Paul, Minn.
Schwyzer, Gustav.....Minneapolis, Minn.
Seelig, Major G.....St. Louis, Mo.
Senger, William.....Pueblo, Colo.
Shere, Oscar M.....Denver, Colo.
Sherk, Henry H.....Pasadena, Calif.
Smith, Joseph F.....Wausau, Wis.
Smith, Rea.....Los Angeles, Calif.
Speed, Kellogg.....Chicago, Ill.
Stokes, Arthur C.....Omaha, Neb.
Strachauer, Arthur C.....Minneapolis, Minn.
Summers, John E., Jr.....Omaha, Neb.
Sweetser, Horatio B.....Minneapolis, Minn.

Teachenor, Frank R.....Kansas City, Mo.
Tennant, Chauncey E.....Denver, Colo.
Twyman, Elmer D.....Independence, Mo.

Vaughan, Roger T.....Chicago, Ill.
Venable, Charles H.....San Antonio, Texas

Wallace, Charles H.....St. Joseph, Mo.
Warren, John N.....Sioux City, Ia.
Wetherill, Horace G.....Denver, Colo.
Witherspoon, Thomas C.....Butte, Mont.

Yates, John L.....Milwaukee, Wis.

MEMBERS OF THE WESTERN SURGICAL ASSOCIATION, DECEMBER, 1919

ARRANGED BY STATES AND CITIES

CALIFORNIA

Los Angeles

Cochran, Guy
Kahn, Maurice F.
Richardson, Witham W.
Smith, Rea
Moore, Edward C.

Pasadena

Lockwood, Charles D.
Sherk, Henry H.

San Diego

Percy, James F.

Santa Barbara

Robinson, Samuel

CANADA

Winnipeg

Maclean, Neil John

COLORADO

Colorado Springs

Mayhew, D. P.
McKinnie, Lewis H.

Denver

Fowler, Ora S.
Freeman, Leonard
Grant, W. W.
Hegner, Casper F.
Jones, S. F.
Lyman, Charles B.
McGraw, Henry R.
McNaught, Francis H.
Shere, Oscar M.
Tennant, Chauncey E.
Wetherill, H. G.

Pueblo

Corwin, Richard W.
Senger, W.

ILLINOIS

Chicago

Andrews, E. Wyllys
Beck, Emil G.
Besley, F. A.
Byford, Henry T.
Cubbins, Wm. R.
Davis, Carl B.
Dyas, Frederick G.
Eisendrath, D. N.
Fuller, William
Halstead, A. E.
Harris, M. L.
Harsha, William M.
Hessert, William
Hopkins, Clarence W.
Kanavel, Allen B.
Lewis, Dean D.
McArthur, L. L.
Plummer, Samuel C.
Richter, Harry M.
Speed, Kellogg
Vaughan, Roger T.

Jacksonville

Black, Carl E.

Peoria

Collins, C. U.
Hanna, Robert A.

Rock Island

Hollowbush, J. R.
Sala, St. E. M.

Springfield

Kreider, George M.

Spring Valley

Franklin, John H.

INDIANA

Fort Wayne

Porter, Miles F.

Indianapolis

Clark, Edmund D.
Eastman, J. R.
Gatch, W. D.

IOWA

Centerville

James, C. S.

Clinton

Fairchild, David S., Jr.
Fairchild, David S., Sr.

Council Bluffs

Macrae, Donald, Jr.

Des Moines

Fay, Oliver J.
McCarthy, W. W.
Rockafellow, John C.

Dubuque

Hancock, J. C.

Iowa City

Rowan, Charles J.

Ottumwa

Brockman, D. C.

Sioux City

Jepson, Wm.
Knott, VanBuren
Warren, J. N.

KANSAS

Kansas City

Gray, G. M.

Wichita

Basham, D. W.
Bowers, Chas. E.
Evans, John L.

MICHIGAN

Battle Creek

Case, J. T.

MINNESOTA

Brainerd

Ide, A. W.

Duluth

Collins, Arthur N.
Coventry, W. A.
McDonald, A. L.
Magie, William H.

Minneapolis

Abbott, A. W.
Benjamin, A. E.
Corbett, J. Frank
Dunsmoor, F. A.
Hare, Earle R.
Kimball, H. H.
Law, Arthur A.
Mann, A. T.
Rochford, Wm. E.
Schwyzer, Gustav
Strachauer, A. C.
Sweetser, H. B.

Rochester

Balfour, Donald C.
Henderson, M. H.
Judd, Edward S.
Mayo, C. H.

St. Paul

Colvin, Alex R.
Dennis, Warren A.
Earl, Robert
MacLaren, Archibald
Ritchie, Harry P.
Schwyzer, Arnold

MISSOURI

Columbia

Myer, Max W.
Nifong, F. G.

Independence

Twyman, E. D.

Kansas City

Binnie, John F.
Frick, W. J.
Griffith, J. D.
Henderson, James P.
Hertzler, A. E.
Hill, Howard
Jackson, J. N.
Pearse, H. E.
Reynolds, William T.
Teachenor, F. R.

St. Joseph

Wallace, C. H.

St. Louis

Babler, Edmund A.
Bailey, F. A.
Bartlett, W.
Blair, Vilray P.
Clopton, M. B.
Coughlin, Wm. T.
Crossen, Harry
Hill, Roland
Leighton, W. E.
Nicholson, C. M.
Seelig, Major G.

MONTANA

Butte

Witherspoon, T. C.

NEBRASKA

Norfolk

Salter, P. Harold

Omaha

Davis, B. B.
Jonas, A. F.
Lord, J. P.
Stokes, Arthur C.
Summers, J. E., Jr.

NEW YORK

New York City

Eliot, Ellsworth

NORTH DAKOTA

Bismarck

Quain, Eric P.

Fargo

Aylen, James P.

OHIO

Cincinnati

Haines, W. D.
Ransohoff, Joseph
Ransohoff, Lewis J.
Reed, Charles A. L.
Ricketts, B. M.

OKLAHOMA

Oklahoma

Blesh, Abraham C.

OREGON

Portland

Coffey, R. C.

SOUTH DAKOTA

Pierre

Riggs, Theodore F.

Sioux Falls

Cottam, Gilbert G.

TENNESSEE

Nashville

Sanders, Evander M.

TEXAS

San Antonio

Venable, C. H.

UTAH

Salt Lake City

Kerr, Archibald A.

WASHINGTON

Seattle

Horton, George W.
Lamson, Otis F.

WISCONSIN

La Crosse

Evans, Edward

Madison

Jackson, Reginald H.

Milwaukee

Lemon, C. H.
Yates, John L.

Oshkosh

Connell, F. Gregory

Wausau

Smith, Joseph F.

INDEX

Abdominal drainage 355

Adenomyomas containing uterine mucosa, the distribution of 41

Anastomosis, intestinal—newest, quickest and best..... 345

Anesthesia, a mixture of ethyl chloride, chloroform and ether, for general..... 227

Arthoplastic operations 423

Basham, D. W.
Abdominal drainage 355

Beck, Emil G.
Intentional removal of skin and other tissues overlying deep-seated inoperable cancer, a necessity for effective treatment with *x*-ray or radium, with report of relative absorption of rays by skin, fat and muscle, as compared with various thicknesses of aluminum, by G. W. Warner, A. B., of the Ryerson Laboratory, University of Chicago 431

Black, Carl E.
Medical education in Greece..... 273

Blair, Vilroy Papin.
Operation for advanced carcinoma of the tongue or floor of the mouth..... 405

Breast tumors, operative treatment in two hundred..... 389

Cancer, intentional removal of skin and other tissues overlying deep-seated inoperable..... 433

Cancer involving the mouth..... 415

Carcinoma, advanced, of the tongue or floor of the mouth 405

Clopton, Malvern B.
Tuberculosis of the great trochanter of the femur.... 163

Coffey, Robert C.
Gastro-enterostomy still the treatment for chronic gastric and duodenal ulcer..... 315

Collins, Clifford U.
Volkmann's contracture of the forearm, with presentation of a patient..... 205

Corwin, Richard W.
Traumatic osteomyelitis 187

Cullen, Thomas S.
The distribution of adenomyomas containing uterine mucosa 41

Davis, Byron B.
Operative treatment in two hundred breast tumors... 389

Duodenum, a congenital anomaly of the, and its surgical significance 349

Eastman, Joseph Rilus.
Operative technic in spina bifida 215

Empyema, the surgical treatment of..... 371

Evans, Edward.
Some rarer fractures—with lantern slides..... 149

Fistulæ, vesicovaginal, the operative treatment of..... 251

Fracture of the neck of the femur, treatment of..... 139

Fractures, some cases of..... 149

Freeman, Leonard.
A congenital anomaly of the duodenum and its surgical significance..... 349

Gastro-enterostomy still the treatment for chronic gastric and duodenal ulcer..... 315

Grant, W. W.
The surgical treatment of empyema..... 371

Haines, Willard D.
Dislocation of the tarsal scaphoid: double fracture of the ischiatic tuberosities 155

Heliotherapy, Rollier's 169

Hernia, diaphragmatic 291

Hill, Roland.
Medical problems suggested by the war..... 23

Ischiatic tuberosities, double fracture of the..... 155

Jaundice and its surgical significance..... 303

Judd, E. S.
The operative treatment of vesicovaginal fistulæ..... 251

Kerr, A. A.
Arthroplastic operations, with report of cases of arthroplasty of the temporomaxillary joint; also of the elbow joint..... 423

Kreider, George Noble.
Cancer involving the mouth..... 415

Lockwood, Charles D.
Treatment of fracture of the neck of the femur in the aged 139

McKinnie, Lewis H.
A new method of applying plaster-of-Paris splints... 197

Mayo, C. H.
Jaundice and its surgical significance..... 303

Medical education in Greece..... 273

Medical problems suggested by the war..... 23

Merycism, case-reports of..... 283

Nifong, Frank G.
Case-reports of merycism 283

Osteomyelitis, traumatic 187

Plaster-of-Paris splints, a new method of applying..... 197

Quain, E. P.
A mixture of ethyl chloride, chloroform, and ether for general anesthesia—an experience in war surgery 227

Rhinophyma 239

Ricketts, B. M.
Intestinal anastomosis—newest, quickest and best.... 345

Riggs, Theodore F.
Diaphragmatic hernia 291

Rollier's heliotherapy 169

Schwyzer, Gustav.
Tuberculosis of the joints and Rollier's heliotherapy.. 169

Seelig, M. G.
Rhinophyma 239

Spina bifida, operative technic in..... 215

Tarsal scaphoid, dislocation of the: double fracture of the ischiatic tuberosities 155

Tuberculosis of the great trochanter of the femur..... 163

Tuberculosis of the joints and Rollier's heliotherapy..... 169

Ulcer, chronic gastric and duodenal, gastro-enterostomy still the treatment for..... 315

Volkmann's contracture of the forearm..... 205